

Vaping Induced Pathological Changes in the Lung: A Case Report Study

Rashmi R Bhuyan* and Kumkum Vadhera

Department of Medicine, Harbor-UCLA Medical Center, USA

Abstract

Introduction: The angiosome concept was first described in 1987, defining an angiosome as an area of tissue comprising skin, subcutaneous tissue, fascia, muscle and bone supplied by a specific artery and drained by a specific vein. We report a case of a patient who was successfully complex revascularized by open surgery and endovascular techniques based on angiosome concept.

Case presentation: A 73-years-old male patient with critical limb ischemia and type 2 diabetes, presented increasing resting pain in the lower right limb during the last 3 months, followed by necrosis of distal phalanx of I and II toes, wet interdigital necrosis of toes I-II on the right leg, with absence of distal pulses on both limbs. Direct flow into affected angiosome was successfully achieved with right proximal femoral-popliteal saphenous vein bypass and ATA balloon dilatation angioplasty.

Conclusion: The vascular patient with critical ischemia associated to diabetes currently requires a complex treatment including open surgery, endovascular technique and negative pressure therapy to save the lower limbs. The angiosome concept is useful during both open and endovascular tibial revascularisation.

Keywords: Bypass • Endovascular • Angiosomes • Critical limb ischemia • Diabetes

Abbreviations: PAD: Peripheral Arterial Disease • ATA: Anterior Tibial Artery • PTA: Posterior Tibial Artery • PA: Popliteal Artery • CLI: Critical Limb Ischemia • DR: Direct Revascularization • VAC: Negative Pressure Therapy • ABI: Ankle-Brachial-Index

Introduction

The outbreak of severe and acute pulmonary disease associated with the use of cannabis extract-containing vape pens and nicotine e-cigarettes has grown to 2,711 reported cases according to the most up-to-date data retrieved from the Center for Disease Control and Prevention (CDC) website posted on January 20, 2020 [1]. 27 confirmed death cases have been reported due to severe and acute pulmonary disease associated with e-cigarettes in all 50 states, the District of Columbia, and two U.S. territories (Puerto Rico and the U.S. Virgin Islands) [1]. Although chemical exposure has been postulated as a definitive cause, the acute incidence of pulmonary disease has brought national attention to this epidemic [2] and warrants more studies of clinical course, radiological findings and unique pathological changes in the lungs that will help in immediate medical management for VAPI with appropriate support, as reported in the case below (Figure 1).

Case Report

A 30-year-old female with history of anxiety, depression and marijuana use presented in the ED with dyspnea and hypoxic respiratory failure with presumed etiology of inhalation of injury vs hypersensitivity pneumonia. CT chest showed diffuse bilateral ground-glass changes with differential diagnosis of multifocal pneumonia vs interstitial pneumonia (Figure 2). Due to sustained hypoxia, bronchoscopy was performed on day eight day of admission in the pulmonary intensive care unit. Patient responded well to steroids with infectious work up

*Address for Correspondence: Bhuyan RR, Department of Medicine, Harbor-UCLA Medical Center, USA, E-mail: rbhuyan@dhs.lacounty.gov

Copyright: © 2020 Bhuyan RR, et al. This is an open-access article distributed under the terms of the Creative Commons Attribution License, which permits unrestricted use, distribution, and reproduction in any medium, provided the original author and source are credited.

Received 30 July 2020; Accepted 12 August 2020; Published 19 August 2020

negative. She was discharged on a short course of Bactrim and oral prednisone 40 mg. Prednisone was tapered and discontinued eventually, with cessation of vaping and smoking, patient made complete recovery in few weeks at home. On arrival in the emergency department, the patient was tachypneic with a respiratory rate of 46 breaths per minutes and oxygen saturation 70 at ambient air, blood pressure was 127/65 mmHg, heart rate 98 per minute. Started on high flow nasal cannula with improvement of oxygen saturation to high 90s. Subsequently patient was admitted to medical intensive care unit on empirical antibiotic coverage, bronchodilator inhalers and BiPAP for breathing fatigue with an oxygen flow at 40 L/min.

Physical examination is remarkable for diaphoresis, tachypnea, labored breathing with accessory muscle use, diffuses inspiratory and expiratory

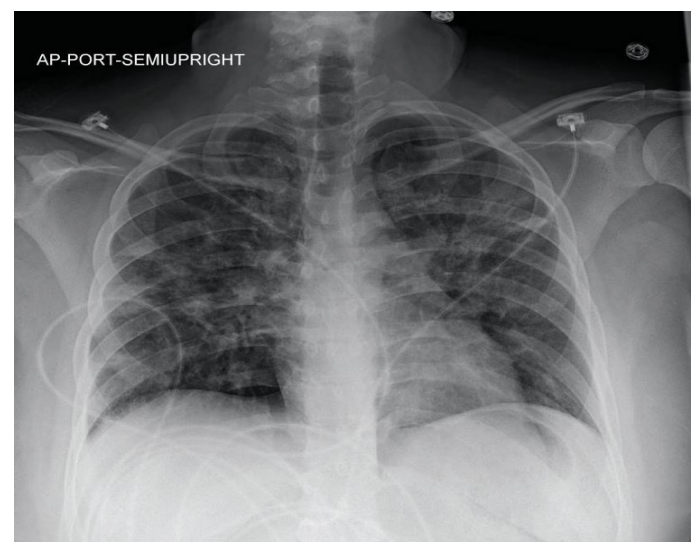


Figure 1. Lungs are well expanded; Heart size is normal, there is a hazy appearance to the interstitium bilaterally, worst in the perihilar distribution.

wheezing in all lung fields bilaterally. Differential diagnoses initially in the emergency department made were interstitial pneumonia vs multifocal pneumonia; VAPI was considered after cytology finding of lipid-laden macrophages in the bronchoalveolar lavage by bronchoscopy procedure was observed. Bronchoscopy showed normal vocal cord, airways without secretions, lesions or obstructions, bronchoalveolar lavage in the right middle lobe and left lower lobe performed with good return of foamy fluid. Patient was then started on oral steroids 60 mgs per day, after that patient was observed to have notable improvement, BiPAP was changed to high flow nasal cannula at 40 L/min. Patient showed gradual improvement, was transitioned to room air on day fifteen. Oral steroid was weaned to 40 mg daily for 7 days, then to 30 mg per day for another 7 days, then 20 mg per day for next 7 days, eventually completely discontinued (Figures 3 and 4).

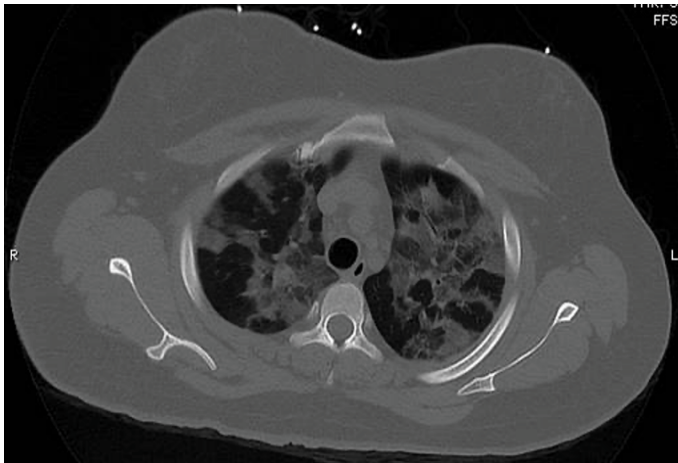


Figure 2. Markedly increased bilateral, diffuse patchy ground-glass opacities which are upper and mid lung zone predominant.

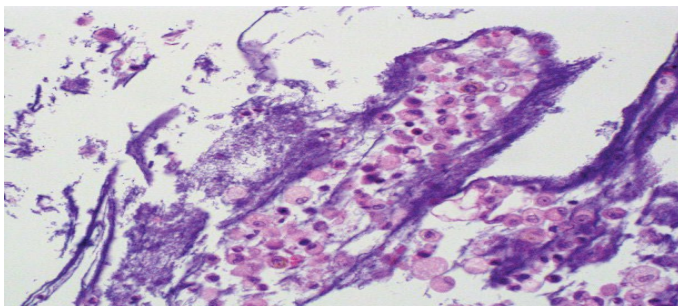


Figure 3. Bronchoalveolar lavage showing foamy macrophages in the background of acute and chronic inflammatory cells, mucin and benign bronchial epithelial cells. Hematoxylin-eosin, original magnification 400x.

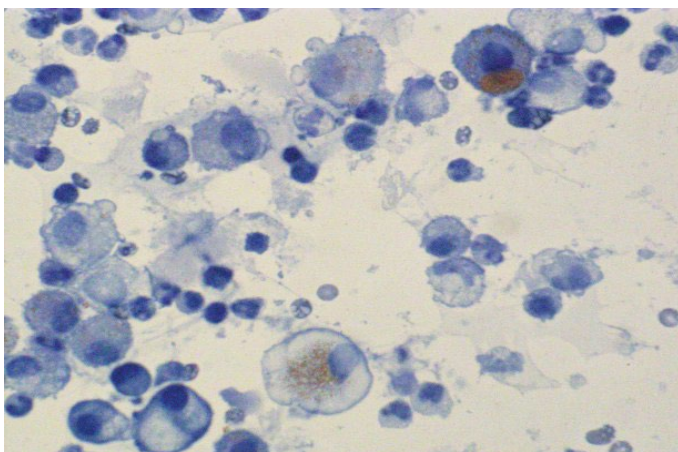


Figure 4. Bronchoalveolar lavage fluid stained with oil red O highlights numerous macrophages, containing lipid deposits, marked with blue arrows (lipid-laden macrophages).

Discussion

Lipoid pneumonia is a constellation of lung disease due to presence of lipids in the alveoli and is a chronic foreign body reaction to fat. It can be classified into two groups depending on an exogenous versus endogenous source of lipid or oil and host tissue reactions to the inhaled substances according to their chemical characteristics. The clinical presentation is variable ranging from subtle respiratory symptoms like dyspnea and cough to severe symptoms with life-threatening respiratory failure [3-6]. Therefore, making a diagnosis of exogenous lipid pneumonia requires a good clinical history and high degree of clinical suspicion. Imaging findings indicating VAPI include interlobular septal thickening, diffuse infiltrates with a range of “ground glass” opacities, and nodular or “tree-in-bud” apical surfaces [7-9]. Cytology examination of sputum or BAL specimen showing the presence of lipid-laden macrophages is also consistent with diagnosis of PAVI; however, high lipid-laden macrophages and high Lipid-Laden Alveolar Macrophage Index (LLAMI) are not specific findings and can be found in various lung diseases [10], correlation with clinical suspicion and radiologic finding is helpful. So, the addition of foamy macrophages, extracellular oily droplets, and macrophage with large cytoplasmic vacuoles contrasting to small vacuoles in the endogenous forms is a more specific diagnosis of exogenous lipid pneumonia [11] which may be associated with inflammatory cells like foreign body reaction with a proliferative fibrosis and macrophages with black pigmentation [12].

Conclusion

The disease outbreak is evolving rapidly. There appears to be some difference of opinion on whether VAPI is best characterized as exogenous lipid pneumonia or chemical pneumonitis. However, the likely diagnostic path and treatment (trial and failure of albuterol and antibiotics, treatment with steroids, respiratory support and antibiotics to suppress secondary infections) remain the same. This case, with typical symptoms, imaging findings and lipid-laden macrophages on lung cytology, confers the need of early suspicion and appropriate intervention with respiratory support.

References

1. Lauren F. Chun, Farzad Moazed, Carolyn S. Calfee and Michael A. Matthay, et al. “Pulmonary Toxicity of E-Cigarettes.” *Am J Physiol* 313 (2017): 193-206.
2. Kendall Moore, Henry Young and Matthew F. Ryan. “Bilateral Pneumonia and Pleural Effusions Subsequent to Electronic Cigarette Use.” *Open J Emerg Med* 3 (2015): 18-22.
3. Ivan O. Rosas and Naftali Kaminski. “Update in Diffuse Parenchymal Lung Disease 2013.” *Am J Resp Crit Care Med* 191 (2015): 1.
4. Janes, Kaslow. “Cookies and Cream Lung: Hypersensitivity Pneumonitis Leading to Acute Respiratory Distress Syndrome after Electronic Cigarette Use.” *Pediat Clin Chest Rounds* 21 (2019): 01.
5. Nivin, Poponea. “The Dark Side of Vaping; Acute Dyspnea and Granulomatous Lung Disease Associated with Electronic Cigarettes.” *Am Thorac Soc* 2 (2018): 21.
6. Jeffrey Sturek and Numaan Malik. “Acute Hypoxic Respiratory Failure with Crazy Paving Associated with Electronic Cigarette Use.” *Chest* 152 (2017): 746.
7. Kevin Davidson, Alison Brancato, Peter Heetderks and Wissam Mansour, et al., “Outbreak of Electronic-Cigarette-Associated Acute Lipoid Pneumonia-North Carolina, July-August 2019.” *MWR* 68 (2019): 784-786.
8. Jennifer E. Layden, Isaac Ghinai, Ian Pray and Anne Kimball, et al., “Pulmonary Illness Related to E-Cigarette Use in LInois and Wisconsin: Final Report.” *New England J Med* 382 (2020): 903-916.
9. Simon Sung, Henry D. Tazelaar, John P. Crapanzano and Aziza Nassar, et al. “Adult Exogenous Lipoid Pneumonia: A Rare and Under Recognized Entity in Cytology: A Case Series.” *Cyto J* 15 (2018): 17.
10. Giulio Rossi, Alberto Cavazza, Paolo Spagnolo and Salvatore Bellafiore, et al. “The Role of Macrophages in Interstitial Lung Diseases.” *Euro Resp Rev* 26 (2017): 170009.

11. Zeeshan Sheikh, Patricia Brooks, Oriyah Barzilay and Noah Fine, et al. "Macrophages, Foreign Body Giant Cells and their Response to Implantable Biomaterials." *Materials* 8 (2015): 5671-5701.
12. Bryno Gay, Zachary Field, Sachin Patel and Rodrigo Murillo Alvarez, et al. "Vaping-Induced Lung Injury: A Case of Lipoid Pneumonia Associated with E-Cigarettes Containing Cannabis." *Case Rep Pulmonol* 20 (2020): 1-4.

How to cite this article: Rashmi R Bhuyan and Kumkum Vadhera. "Vaping Induced Pathological Changes in the Lung: A Case Report Study." *Clin Case Rep* 10 (2020): 1376. DOI: 10.3742/jccr.2020.10.1376