

# The Use of 3D Printing Pelvis and Hip in a Complex THA: Clinical Experience and Reports of Literature

Chenyu Huang<sup>1,2,3</sup>, Qingqiang Yao<sup>1,3,4</sup>, Wei Liu<sup>2</sup>, Yan Xu<sup>1,3,4</sup>, Cheng Tang<sup>1,3,4</sup>, Bo Wei<sup>1,3,4</sup>, Jiayi Li<sup>1,3,4</sup> and Liming Wang<sup>1,3,4,\*</sup>

<sup>1</sup>Department of Orthopaedic Surgery, Nanjing First Hospital, Nanjing, China, 210006

<sup>2</sup>Department of Orthopaedic Surgery, Jiangsu Province Hospital, Nanjing, China, 211800

<sup>3</sup>Institute of Digital Medicine, Nanjing Medical University, Nanjing, China, 210006

<sup>4</sup>Jiangsu Digital Medicine and 3D Printing Clinical Engineering Research Center, Nanjing, China, 210006

## Abstract

**Background:** Total Hip Arthroplasty (THA) is a good solution of Developmental Dysplasia of the Hip (DDH). However, patients diagnosed with Crowe type IV are difficult to deal with. With traditional operation skills, the operation time is quite long and the patients will lose a lot of blood.

**Case presentation:** We present the case of a 58-year-old male patient who underwent left THA due to Crowe type IV DDH with the help of 3D printing models. Before the operation, we put the CT image into computer software named mimics. After getting the stl. Document, we use 3D printer to print the models out. By using the models, we planned the operation in advance. And after sterilizing the models, we put them in the operation area, which saves a lot of operation time and reduces much blood loss by giving surgeons a better anatomy view.

**Methods:** A health institution-based retrospective cohort study was conducted among 421 children with HIV/AIDS from 2009-2018. The Time to develop TB was defined as the time from enrollment for ART care until the development of TB among children on ART. Variables with a P-value <0.25 at bivariate Cox regression analysis, were entered into the multivariable Cox model. Multivariable-Cox-regression model with 95% CI and AHR was used to identify significant predictor variables to develop TB at P< 0.05.

**Conclusion:** THA with the help of 3D printing pelvis and femur can result in a relatively short recovery time and provide good clinical efficacy of type IV DDH patients.

**Keywords:** 3D printing • Crowe type IV DDH • THA Addictive manufacturing

**Abbreviations:** 3D: Three-dimensional; DDH: Developmental Dysplasia of the Hip; CT: Computed Tomography; THA: Total Hip Arthroplasty

## Introduction

### Background

The Developmental Dysplasia of the Hip (DDH) is a condition characterized by morphological abnormalities of the acetabulum and femur. And surgeons classified it according to dislocation severity, from I to IV, most commonly based on the Crowe rubric. And the type IV is the most severe of the four types [1]. Primary Total Hip Arthroplasty (THA) is complicated and difficult in patients with Crowe type IV (type IV from here forward for simplicity) DDH because the pathological anatomical changes that accompany this condition. Compared to traditional THA, the operation time is longer and intraoperative bleeding is much more. In the 1970s, John Charnley introduced the trochanteric osteotomy for complicated primary hip replacement, including in patients with type IV DDH [2]. Along with the good performance of the patients after the operations, is the longer operation time and more intraoperative bleeding? Some Crowe type IV DDH patients undergoing THA require a femoral shortening osteotomy to equalize the length of the lower extremities and decrease the difficulty of intraoperative reduction and the incidence of complications [3-5]. The femoral sub trochanteric transverse osteotomy is one of the most common forms of

osteotomy [6,7]. Although several such surgical protocols have been reported to yield excellent results, each has drawbacks. Thus it is necessary to invent a method to save operation time and reduce intraoperative bleeding. With the development of the 3D printing technique, 3D printing pelvis and femur can be of great use in the surgeries of THA. Our study reports the case of a patient with type IV DDH who underwent THA with the help of 3D printing pelvis and femur. The time and blood control of the surgery and recovery time after THA are discussed based on literature reports.

## Case Presentation

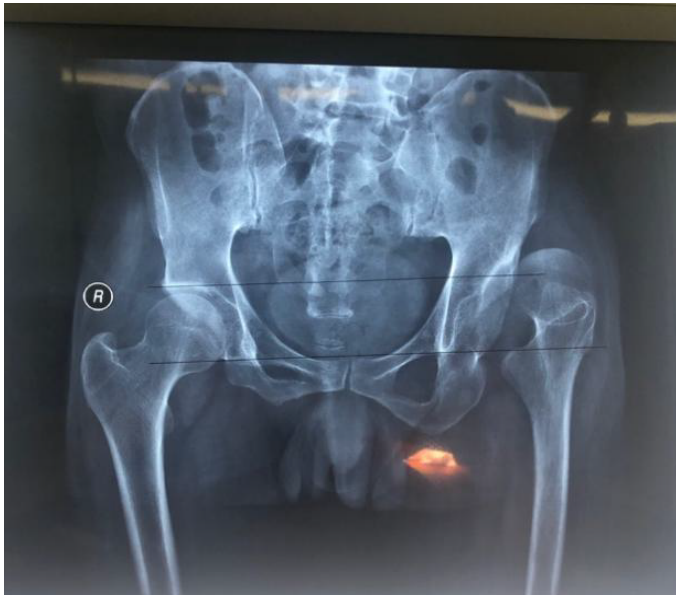The patient we operated on is a 58-year-old male, who came to our hospital because of the limited activity of the left hip. He suffers from the intermittent pain of the hip for more than 40 years and the pain aggravated for 6 months. We X-rayed his pelvis and found that his left hip was dislocated (Figure 1). Then he was diagnosed with Crowe type IV with a Harris score of 23 and visual analogue scale (VAS) score of 8. After the physical examination, we found that the patient's left leg is shorted by 4.2 cm and he suffers from the pain of hip rotation. The degrees of right hip joint motion were as follows: adduction, 10°; internal rotation 10°; and external rotation, 10°; flexion, 80°; and outreach, 15°. There are no other diseases reported by the patient.

First, we collected the patients' image data by using MRI (Siemens, Berlin, Germany) and CT (Philips, Eindhoven, Netherlands) plain scans. Then we import the MRI and CT data (DICOM format) for the surgical area into the computer and reconstructed it via Mimics 21.0 software (Materialize, Leuven, Belgium). We used different colours to distinguish different parts of the structure and finally we got a 3D digital model (Figure 2). After getting the 3D digital model, we analyse the condition of the patients and developed a surgical plan, which helped us get to know the patients better. And then we use 3D printer to print the model out and sterilize the 3D model (Figure 3).

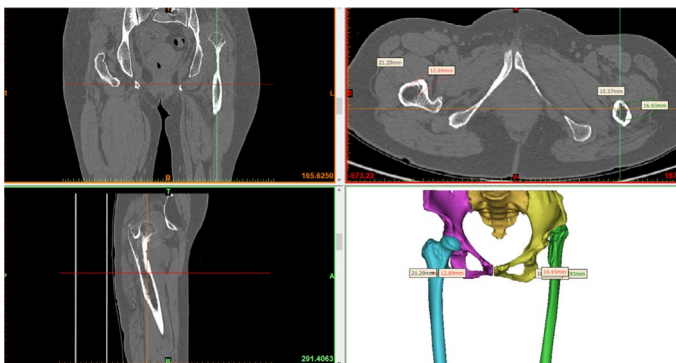
**\*Address for Correspondence:** Chenyu Huang, et al, Department of Orthopaedic Surgery, Nanjing First Hospital, Nanjing, China, 210006, E-mail: lmwang@njmu.edu.cn

**Copyright:** © 2021 Huang C, et al. This is an open-access article distributed under the terms of the Creative Commons Attribution License, which permits unrestricted use, distribution, and reproduction in any medium, provided the original author and source are credited.

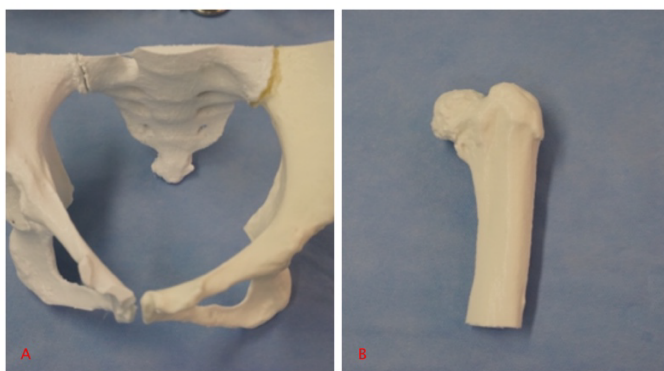
**Received** 23 December, 2021, Manuscript No. jma-21-50650; **Editor Assigned:** 05 January, 2022, PreQC No. P-50650; QC No. Q-50650; **Reviewed:** 17 January, 2022; **Revised:** 22 January, 2022, Manuscript No. R-50650; **Published:** 30 January, 2022, DOI: 10.37421/2684-4265.2022.6.221



**Figure 1.** Patient X-ray image before the operation.



**Figure 2.** 3D digital model of the patient.



**Figure 3.** 3D printed models.

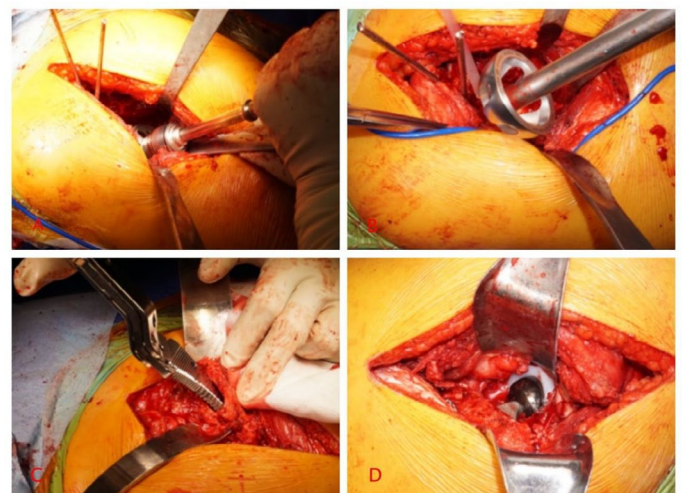
We performed the surgery through the posterior-lateral approach. The patient was placed in the right lateral position after sciatic nerve block and lumbar plexus anaesthesia. We made a roughly 12-cm poster lateral incision on the left hip of the patient right after disinfection and draping. And the epidermis and subcutaneous tissue of the surgical area were dissected to expose the selected bony landmark according to the surgical plan. First, we compared the sterilized 3D model with the patient's structure. Second, in the preoperative design of the acetabulum cup position, we use the acetabula reamer with a diameter of 36 mm to grind to a diameter of 46 mm (Figure 4), and then we inserted a 48 mm diameter cement less acetabula cup and reinforced it with two acetabula screws (Figure 4). Time to time, we used the 3D printing model to avoid extra procedures. And then we opened the femoral medullary cavity enlarged it to the size of 10.5 with the medullary cavity file (Figure 4). We installed the femoral prosthesis with a 36mm diameter short neck head. At last,

we reset the hip joint and checked its motion (Figure 4). Before suturing layer by layer, we placed a drainage tube deep into the surgical area. The operation lasted for 2h, which is much quicker than traditional DDH surgery. Also with the help the 3D printing models, the intraoperative bleeding is less than usual.

## Discussion

The other name of Three-Dimensional Printing (3DP) is rapid prototyping, which constricts 3D models layer by layer. It is an additive manufacturing process that promotes the production of the complex geometrical. The development of imaging modalities and the 3D printing technology enables a big advancement in the use of 3D printing models of some operation practices [8-11]. Nowadays, the use of 3D printing technology in clinical practice focuses on 3D printing models [12-15]. Previous researchers made a lot of researches [16-18] in virtual and haptic patient specific anatomical models, often termed bio models [19]. It can help surgeons to plan the operations in advance and save their operation time. So we operated this special operation: 3D printing models assisted complex THA. According to the previous researches, surgeons all around the world hold the opinion that the 3D printing models are quite beneficial when they are operating difficult operations [20]. Previously, before and during the operations, most of the surgeons relied on two-dimensional (2D) images, for example, X-ray, CT and/ or MRI. And the 1:1 scale 3D printing models could provide the surgeons with the better understanding of the anatomy compared to the 2D visualization. Also, before the operations, we can sterilize these models. In that way surgeons could use these models to get a template to review intra-operatively [21,22]. However, the work people have done on the models is limited. Previous researchers have found that, compared to traditional operations, the application of 3D printing models can offer more accurate evaluation of relevant surgical structures in complex cases, for example, acetabula fractures and spinal deformities [22].

Besides the subjective benefits, we can also find some other objective advantages of the 3D printed models. Researchers found that compared to traditional operations, the surgery time, intraoperative blood loss and fluoroscopy time are much less [23-30], which improves the quality of planned placement of implants and selection of instrumentation. And thus the need to contour and the implants number of adjustments intraoperative are reduced. Nowadays, surgeon often uses sub trochanteric shortening osteotomy to deal with the type IV DDH. And in our study, with the usage of the 3D printing models, the surgery time, intraoperative blood loss and fluoroscopy time are much less, which is of great benefit. Disadvantages are also obvious. First is the cost. For better evaluation, we have to compare the potential savings of the improved operations and production cost of the 3D printing models. Second is that the 3D printing model don't include the soft tissue structures, as well as the



**Figure 4.** Procedure of the surgery.

nerves and blood vessels. To better serve the clinical practice, further studies and a streamlined protocol for the 3D printing models are needed in the future.

## Conclusion

THA with the help of 3D printing pelvis and femur can result in a relatively short recovery time and provide good clinical efficacy of type IV DDH patients.

## Ethics Approval and Consent to Participate

All procedures performed in studies involving human participants were in accordance with the ethical standards of the institutional and/or national research committee and with the 1964 Helsinki Declaration and its later amendments or comparable ethical standards. Informed consent was obtained from all individual participants included in the study.

## Funding

National Natural Science Foundation of China (81771985)

## Authors' Contributions

FK, CYH and QQY contributed to the study design and the drafting of the article. WL, CT and BW collected CT data and CAD. JYL, HKZ and CYH cleaned, prepared and sterilized the model. JTL and LMW contributed to all surgical procedures. The authors read and approved the final manuscript.

## Acknowledgment

The datasets used and/or analyzed during the current study are available from the corresponding author on reasonable request.

## Data Availability

The datasets used and/or analysed during the current study are available from the corresponding author on reasonable request.

## References

- Crowe, James Franklin, VJ Mani, and Chitranjan Singh Ranawat. "Total hip replacement in congenital dislocation and dysplasia of the hip." *J Bone Joint Surg Am* 61 (1979): 15-23.
- Charnley, J. "Total hip replacement by low-friction arthroplasty." *Clin Orthop Relat Res* 72 (1970): 7-21.
- Krych, Aaron J, James L Howard, Robert T Trousdale, and Miguel E Cabanela, et al. "Total hip arthroplasty with shortening subtrochanteric osteotomy in Crowe type-IV developmental dysplasia." *J Bone Joint Surg Am* 91 (2009): 2213-2221.
- Wang, Duan, Ling-Li Li, Hao-Yang Wang, and Fu-Xing Pei, et al. "Long-Term Results of Cementless Total Hip Arthroplasty with Subtrochanteric Shortening Osteotomy in Crowe Type IV Developmental Dysplasia." *J Arthroplasty* 32 (2017): 1211-1219.
- Ollivier, Matthieu, Matthew P Abdel, Aaron J Krych, and Robert T Trousdale, et al. "Long-Term Results of Total Hip Arthroplasty with Shortening Subtrochanteric Osteotomy in Crowe IV Developmental Dysplasia." *J Arthroplasty* 31 (2016): 1756-1760.
- Park, Myung-Sik, Kyu-Hyung Kim, and Woo-Cheol Jeong. "Transverse subtrochanteric shortening osteotomy in primary total hip arthroplasty for patients with severe hip developmental dysplasia." *J Arthroplasty* 22 (2007): 1031-1036.
- Muratli, Kivanc S, Vasfi Karatosun, Bora Uzun, and Salih Celik. "Subtrochanteric shortening in total hip arthroplasty: biomechanical comparison of four techniques." *J Arthroplasty* 29 (2014): 836-842.
- Sofu, Hakan, Nizamettin Kockara, Sarper Gursu, and Ahmet Issin, et al. "Transverse subtrochanteric shortening osteotomy during cementless total hip arthroplasty in Crowe type-III or IV developmental dysplasia." *J Arthroplasty* 30 (2015): 1019-1023.
- Mu, Wenbo, Desheng Yang, Boyong Xu, and Askar Mamtimin, et al. "Midterm outcome of cementless total hip arthroplasty in Crowe IV-Hartofilakidis type III developmental dysplasia of the hip." *J Arthroplasty* 31 (2016): 668-675.
- Rengier, Fabian, A Mehndiratta, H von Tengg-Kobligk, and C M Zechmann, et al. "3D printing based on imaging data: review of medical applications." *Int J Comput Assist Radiol Surg* 5 (2010): 335-341.
- Wilcox, Ben, Ralph J Mobbs, Ai-Min Wu, and Kevin Phan. "Systematic review of 3D printing in spinal surgery: the current state of play." *J Spine Surg* 3 (2017): 433-443.
- Kim, Jiwon, Jeremy Rajadurai, Wen Jie Choy, and Lachlan Cassar, et al. "Three-Dimensional Patient-Specific Guides for Intraoperative Navigation for Cortical Screw Trajectory Pedicle Fixation." *World Neurosurg* 122 (2019): 674-679.
- Phan, Kevin, Alessandro Sgro, Monish M. Maharaj, and Paul D'Urso, et al. "Application of a 3D custom printed patient specific spinal implant for C1/2 arthrodesis." *J Spine Surg* 2 (2016): 314-318.
- Lu, Sheng, Yong Q Xu, William W Lu, and Guo X Ni, et al. "A novel patient-specific navigational template for cervical pedicle screw placement." *Spine* 34 (2009): E959-E966.
- D'Urso, Paul S, Owen D Williamson, and Robert G Thompson. "Biomodeling as an Aid to Spinal Instrumentation." *Spine* 30 (2005): 2841-2845.
- Burnard, Joshua L, William C H Parr, Wen Jie Choy, and William R Walsh, et al. "3D-printed spine surgery implants: a systematic review of the efficacy and clinical safety profile of patient-specific and off-the-shelf devices." *Eur Spine J* 29 (2019): 1248-1260.
- Choy, Wen Jie, Ralph J Mobbs, Ben Wilcox, and Steven Phan, et al. "Reconstruction of Thoracic Spine Using a Personalized 3D-Printed Vertebral Body in Adolescent with T9 Primary Bone Tumor." *World Neurosurg* 105 (2017):1032.e13-1032.e17.
- Choy, Wen Jie, William C. H. Parr, Kevin Phan, and William R. Walsh, et al. "3-dimensional printing for anterior cervical surgery: a review." *J Spine Surg* 4 (2018): 757-769.
- D'Urso, Paul S, G Askin, J S Earwaker, and G S Merry, et al. "Spinal Biomodeling." *Spine* 24 (1999): 1247-1251.
- Jiang, Michael, Gordon Chen, Jasmine Coles-Black, and Jason Chuen, et al. "Three-dimensional printing in orthopaedic preoperative planning improves intraoperative metrics: a systematic review." *ANZ J Surg* 90 (2019): 243-250.
- Bizzotto, Nicola, Ivan Tami, Attilio Santucci, and Roberto Adani, et al. "3D printed replica of articular fractures for surgical planning and patient consent: a two years multi-centric experience." *3D Print Med* 2 (2015): 2.
- Jentzsch, Thorsten, Lazaros Vlachopoulos, Philipp Frnstahl, and Daniel A Mller, et al. "Tumor resection at the pelvis using three-dimensional planning and patient-specific instruments: a case series." *World J Surg Oncol* 14 (2016): 249.
- Chen, Chunhui, Leyi Cai, Chuanxu Zhang, and Jianshun Wang, et al. "Treatment of deepunch fractures with 3D printing technology." *J Invest Surg* 31 (2017): 385-392.
- Yang, Long, Brian Grottkau, Zhixu He, and Chuan Ye. "Three dimensional printing technology and materials for treatment of elbow fractures." *Int Orthop* 41 (2017): 2381-2387.
- Yang, Long, Xian-Wen Shang, Jian-Nan Fan, and Zhi-Xu He, et al. "Application of 3D printing in the surgical planning of Trimalleolar fracture and doctor-patient communication." *Biomed Res Int* 2016 (2016): 2482086.
- Li, Chao, Mingyuan Yang, Yang Xie, and Ziqiang Chen, et al. "Application of the polystyrene model made by 3D printing rapid prototyping technology for operation planning in revision lumbar discectomy." *J Orthop Sci* 20 (2015): 475-480.
- Zheng, Sheng-Nai, Qing-Qiang Yao, Feng-Yong Mao, and Peng-Fei Zheng, et al. "Application of 3D printing rapid prototyping-assisted percutaneous fixation in the treatment of inter-trochanteric fracture." *Exp Ther Med* 14 (2017): 3644-3650.
- Karlin, Lawrence, Peter Weinstock, Daniel Hedequist, and Sanjay P Prabhu. "The surgical treatment of spinal deformity in children with myelomeningocele: the role of per-sonalized three-dimensional printed models." *J Pediatr Orthop B* 26 (2017): 375-382.

29. Yang, Mingyuan, Chao Li, Yanming Li, and Yingchuan Zhao, et al. "Application of 3D rapid prototyping technology in posterior corrective surgery for Lenke 1 adolescent idiopathic scoliosis patients." *Medicine* 94 (2015): e582.
30. Cherkasskiy, L, JP Caffrey, AF Szewczyk, and E Cory, et al. "Patient specific 3D print models improve deformity correction after proximal femoral osteotomy for slipped capital femoral epiphysis." *J Child Orthop* 11 (2017): 147-153.

**How to cite this article:** Huang,Chenyu, Qingqiang Yao, Wei Liu, and Yan Xu, et al. "The Use of 3D Printing Pelvis and Hip in a Complex THA: Clinical Experience and Reports of Literature". *J Morphol Anat* 6 (2022): 116.