

The Ultrasound-Guided Intratissue Percutaneous Electrolysis

Kristen S*

*Department of Medicine and Physiotherapy in Sports Injuries, University of Lleida, Spain

Description

Stubborn patellar tendinopathy (RPT) is a persistent sickness with reformist degeneration of extracellular lattice, microtearing, and deficiency of ligament microarchitecture as a trademark. The fundamental pathologic injury of tendinopathy is regularly depicted as a bombed mending reaction of the ligament, and steadiness of the sore is ascribed to the tissue secured in the proliferative or angiogenic stage, as demonstrated in histopathology.

Primary discoveries of collagen degeneration and angiofibroblastic neoplasia have been all around depicted and are currently alluded to as "neovascular tendinosis." The presence of neovascularization has been hypothesized to cause torment in patients with tendinopathy.

Ongoing examinations have inspected the part of neo-vessels and neo-innervation on persistent ligament agony and brokenness, and intercessions focusing on this cycle have revealed great results in RPT (Figure 1).of adult squirrel monkey. J Neuroci 16: 785-807. 6. Schwartz JM, Begley S (2002) He mind, the brain: Neuroplasticity and the power of mental force. HarperCollins Publishers Inc., New York. Ultrasound-guided Intratissue percutaneous electrolysis (EPI®) treatment is the application of a direct current (DC) whose cathodic flow is transferred to the area of the degenerative tendon using an acupuncture needle.

This accumulated electrical charge (AEC) in the degenerative tissue will produce the activation of the molecular, celular and biological processes necessary to restore the regeneration mechanisms of the tendon. In recent studies it has been demonstrated that EPI® technique is effective in tendinopathy and sport muscular injuries (Figures 1).

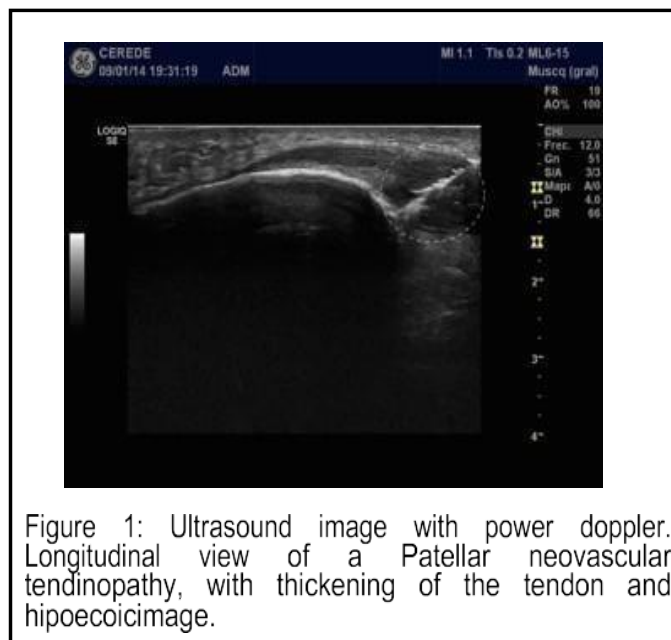


Figure 1: Ultrasound image with power doppler. Longitudinal view of a Patellar neovascular tendinopathy, with thickening of the tendon and hypoechoic image.

How to cite this article: Pradeep M. "The Ultrasound-Guided Intratissue Percutaneous Electrolysis". Physiother Rehabil 6:1(2021): 203

*Corresponding author: Kristen S, Department of Medicine and Physiotherapy in Sports Injuries, University of Lleida, Spain, E-mail: kristen@cerede.es

Received date: January 08, 2021; Accepted date: January 19, 2021; Published date: January 27, 2021

Copyright: ©2021 Kristen S. This is an open-access article distributed under the terms of the Creative Commons Attribution License, which permits unrestricted use, distribution, and reproduction in any medium, provided the original author and source are credited.