

Sustained Histologic Remission (Complete Mucosal Healing) 12 Years after One-Time Treatment of Refractory Ulcerative Colitis with Novel Combination Therapy: A Case Report

Jay Pravda^{1*}, Richard Gordon² and Pamela B. Sylvestre³

¹Inflammatory Disease Research Centre, Department of Redox Mediated Diseases and Therapeutics, 4371Northlake Blvd #247, Palm Beach Gardens, Florida 33410, USA

²Department of Medicine, 226 Brenrich Cove, Memphis, TN 38117, USA

³Department of Pathology, 8000 Wolf River Blvd Suite 200, Germantown, TN 38138, USA

Abstract

Ulcerative colitis is a major form of chronic inflammatory bowel disease affecting millions of individuals worldwide. It most often strikes in the prime of life, during late adolescence and early adulthood. Individuals with ulcerative colitis experience life-long reoccurring and unpredictable episodes of abdominal pain and bloody diarrhea lasting from weeks to months. This results in significant emotional and psychological burdens leading to life-long disruption of daily activities and quality of life. Environmental factors acting in concert with genetic, epigenetic, and microbiome influences are thought to trigger an immune abnormality leading to the chronic colonic inflammation observed in this condition. However, despite extensive research, a primary antecedent immune vulnerability has not been demonstrated in patients or healthy family members. Current therapy is primarily focused on suppressing or modulating the immune response, which is not curative. Other therapeutic modalities such as fecal microbiota transplantation and probiotics are not recommended as viable therapy options. Recent experimental data suggest a build-up of hydrogen peroxide in colonic epithelial cells as a causal factor in the development of this disease. Herein we describe a patient with a 39-year history of ulcerative colitis refractory to standard medical therapy including oral and rectal 5-aminosalicylic acid, oral and rectal steroids in addition to immunosuppressive agents such as 6-mercaptopurine. The patient received the recommended doses of these medications for months at a time in varied combinations without significant improvement. He subsequently received a novel combination therapy aimed at reducing colonic hydrogen peroxide. Histologic remission was achieved 6 weeks after this initial therapy. Colonoscopic evaluation 12-years after initial therapy revealed complete and sustained mucosal healing with histologic restitution to normal colonic mucosa. The patient reports having normal bowel movements during this 12-year period.

Keywords

Ulcerative Colitis • Hydrogen Peroxide • Inflammatory Bowel Disease • Novel Therapy • Remission

Introduction

Ulcerative colitis (UC) belongs to a group of diseases causing chronic inflammation of the gastrointestinal tract. Ulcerative colitis and Crohn's disease comprise the two principal conditions in this category known as inflammatory bowel disease. Ulcerative colitis is a chronic debilitating condition that usually strikes in the prime of life during late adolescence and early adulthood [1]. Various environmental, genetic, epigenetic, and gut microbiome factors have been implicated in the development of this disease [2]. The substantial increase in the worldwide incidence of UC has made it a global disease, affecting nearly a million individuals living in the United States [3,4]. The lifetime individual expense for UC of over

\$400,000 represents a significant economic burden for patients. However, when extrapolated to the prevalent 2016 population with UC in the United States, the lifetime cost is reported to be a staggering 377 billion dollars [5].

Ulcerative colitis causes inflammation of the large intestine that leads to unpredictable life-long episodes of abdominal pain and bloody diarrhea. These episodes, called flares or relapses, can last from weeks to months, causing substantial emotional, psychological, and financial burdens accompanied by a significant deterioration in quality of life [6,7]. Almost all currently approved medications are directed at modulating the immune response, must be taken indefinitely, and are not curative. Additionally, despite the widespread use of immunosuppressive and immunomodulating drugs such as anti-TNF and anti-integrin biologic agents (biologics), studies have shown that these agents just delay surgery with approximately a third of individuals with UC ultimately requiring total colectomy due to medical treatment failure [8,9].

*Corresponding author: Jay Pravda, Inflammatory Disease Research Center, Department of Redox Mediated Diseases and Therapeutics, 4371 Northlake Blvd #247, Palm Beach Gardens, Florida 33410, USA, Tel: (682) 273-6177; E-mail:jaypravda1@gmail.com

Received: June 10, 2020; Accepted: June 22, 2020; Published: June 30, 2020

Copyright: © 2020 Pravda J, et al. This is an open-access article distributed under the terms of the creative commons attribution license which permits unrestricted use, distribution and reproduction in any medium, provided the original author and source are credited.

In 2005, a new theory of ulcerative colitis was proposed that identified excess colonocyte (colonic epithelial cell) hydrogen peroxide (H_2O_2) as the causal factor in the development of colonic mucosal inflammation characteristic of this disease [10]. Based on this new model of pathogenesis, a novel therapy was developed whose aim was the restoration of colonic redox homeostasis by reducing colonic epithelial hydrogen peroxide, which the data implied was the upstream cause of the inflammation. This novel therapy, developed by one of the authors (JP), was offered to patients with refractory ulcerative colitis over a several-year period and the results published as a case series [11]. In this case series, consisting of 36 patients with moderate to severe refractory disease, complete mucosal healing (histologic remission) was achieved by 85% in an average of 54 days.

The patient described in this case report is a licensed medical doctor, an author on this paper (RG), and one of the original 36 patients described in the above case series who received the novel combination therapy directed at lowering extracellular and intracellular colonocyte H_2O_2 . The treatment consisted of a combination enema (5-aminosalicylic acid, budesonide, sodium butyrate, and sodium cromoglicate) administered simultaneously with a systemic oral reducing agent (alpha lipoic acid). Although a multiyear follow-up was not part of the original case series, the patient offered to share the results of his 12-year follow-up colonoscopy and mucosal biopsies, which showed complete mucosal healing with histologically normal colonic mucosa and no evidence of ulcerative colitis. Microscopic examination of the initial and 12-year follow-up colorectal biopsies was performed by the pathologist who is an author on this paper (PBS). The patient relates having completely normal bowel movements during this intervening 12-year period.

Case Presentation

The patient is a 57-year-old male with a 39-year history of ulcerative colitis, initially manifesting with abdominal pain, tenesmus,

urgency, and bloody diarrhea. Family history is positive for a parent and sibling with ulcerative colitis.

Over the years, the patient received various forms and combinations of oral and rectal 5-aminosalicylic acid (enema and suppository), rectal steroid preparations in addition to immunosuppressive agents (6-mercaptopurine, oral steroids). Initial improvement was always followed soon after with relapse of disease characterized by abdominal pain and bloody diarrhea.

When initially evaluated in 2007, the patient had been experiencing intermittent abdominal pain accompanied by 6-8 episodes of blood-tinged diarrhea for the previous 6 months. Medications included oral balsalazide 1.5 g bid. He was diagnosed with moderately severe left-sided ulcerative colitis based on colonoscopic appearance (Figure 1A), and mucosal biopsies that revealed histological features characteristic of ulcerative colitis (Figure 2A). A diagnosis of refractory left-sided ulcerative colitis was made [12].

The patient was offered a novel combination therapy designed to reduce colonic H_2O_2 , which is described in the case series referenced above [11]. Briefly, therapy aimed at reducing intracellular and extracellular colonocyte hydrogen peroxide consisting of a nightly enema containing 5-aminosalicylic acid, budesonide, sodium butyrate, and sodium cromoglycate was instituted. Daily oral alpha lipoic acid was also administered. The therapy was continued daily for 6 weeks.

Colonoscopy and biopsy performed 6 weeks after initiating therapy showed complete endoscopic resolution of colonic inflammation with no evidence of active inflammation on microscopic examination (Figures 1C and 2B). The patient remained on his current medication, balsalazide 1.5 g bid. The patient had no further colorectal biopsies prior to his 12-year follow-up colonoscopy in 2019, which was endoscopically and histologically normal (Figures 3 and 4). He continues to take balsalazide 1.5 g bid.

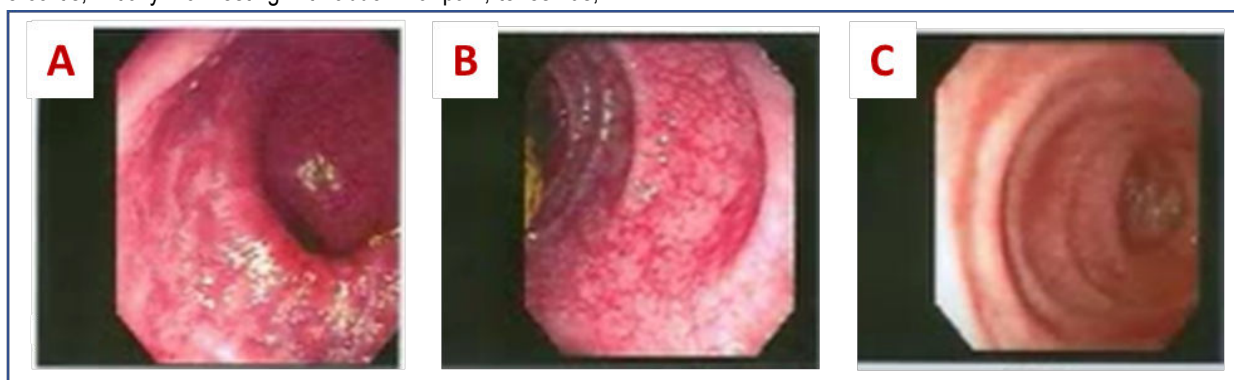


Figure 1:2007 Colonoscopies: (A) Pre-treatment, mucosa in mid sigmoid colon shows marked erythema, loss of vascular pattern, erosions, granularity, and superficial ulcerations. (B) Three weeks after treatment, mucosa in mid sigmoid colon shows mild erythema, normalizing vascular pattern, and healing of superficial ulcers. (C) Six weeks after treatment, mucosa of distal sigmoid colon mucosa is endoscopically normal in appearance.

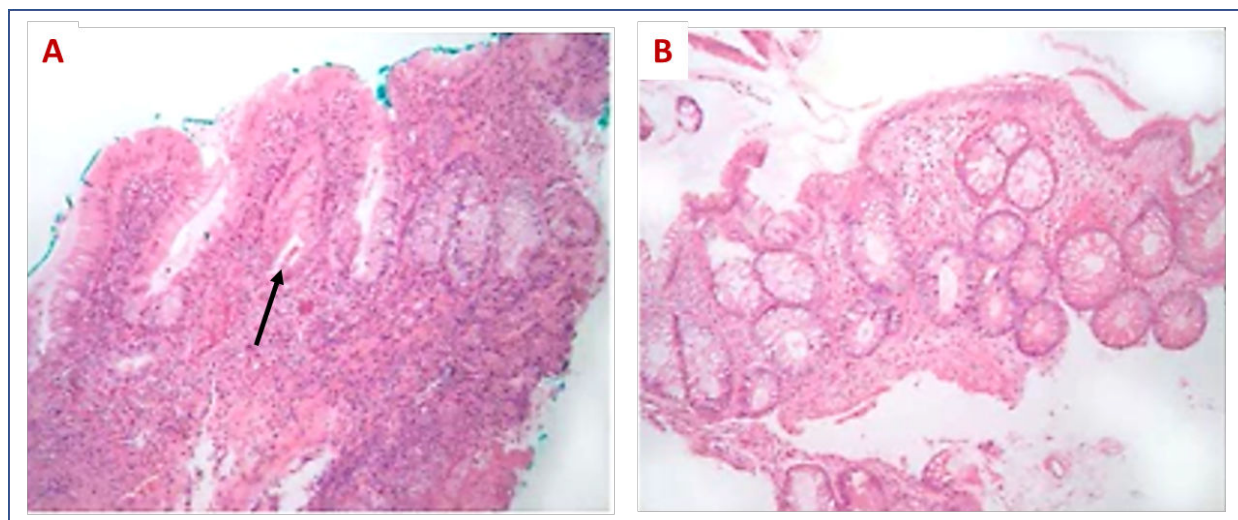


Figure 2:2007 Sigmoid Colon Biopsies (microscopic views of the mucosa): (A) Pre-treatment biopsy (corresponding to Figure 1A) reveals moderately active chronic colitis with crypt architectural distortion and disarray, a moderate-to-marked chronic inflammatory infiltrate within the lamina propria, and a crypt abscess (arrow). (B) Six-weeks post treatment biopsy (corresponding to Figure 1C) shows resolution of active inflammation, a marked decrease in the mononuclear inflammatory infiltrate within the lamina propria, replenished mucin within the colonic epithelium, and a residuum of only mild crypt architectural disarray—an indicator of prior mucosal damage followed by repair.

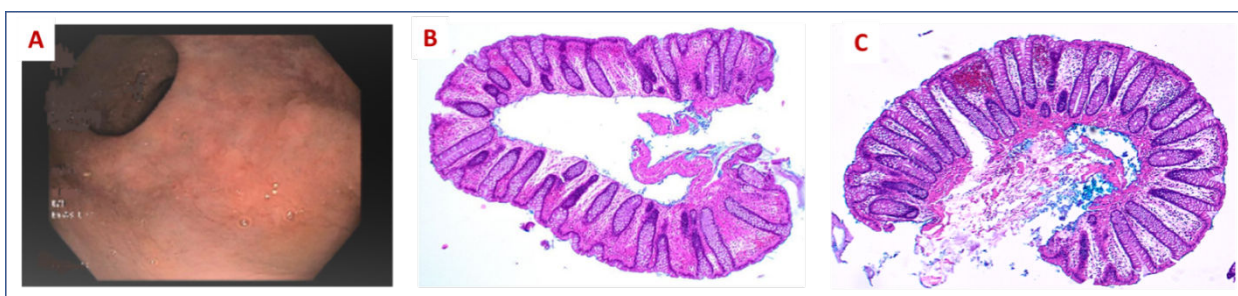

Figure 3:2019 Colonoscopy and Microscopic Appearance of Colorectal Mucosa. (A) Normal endoscopic appearance of rectal mucosa. (B and C) Normal microscopic appearance of rectal mucosa and distal colon biopsy, respectively (low power views).

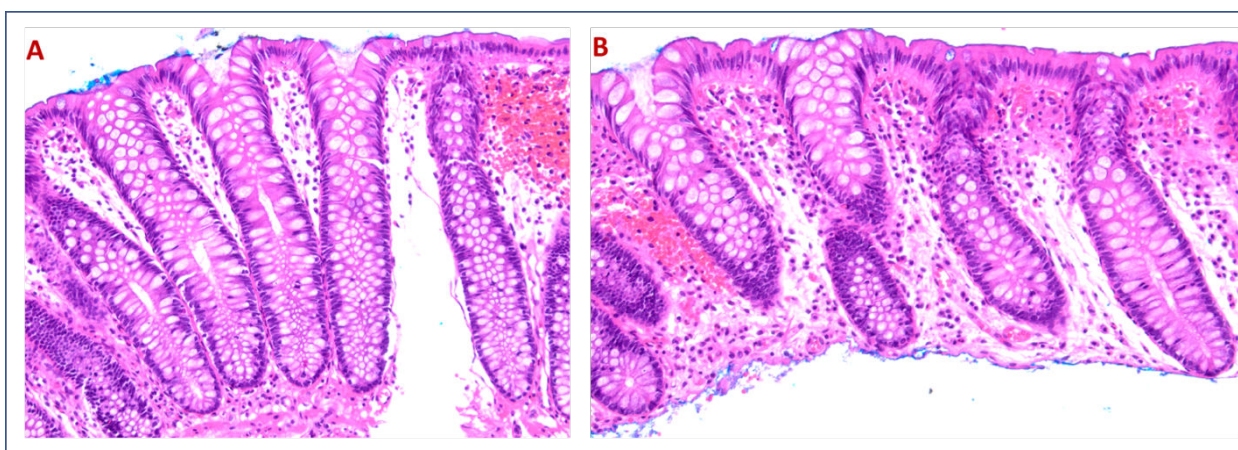


Figure 4:2019 Biopsies (normal microscopic appearance of colorectal mucosa): (A) High power view of rectal mucosa depicted in Figure 3B.(B) High power view of distal colon biopsy depicted in Figure 3C. Both show no cryptitis or crypt abscesses, no increase in mononuclear inflammatory cells within the lamina propria and no crypt architectural distortion. No other histologic features characteristic of inflammatory bowel disease are present in the mucosa of the rectum and distal colon biopsies.

Discussion

The prevailing hypothesis attributes UC to a faulty immune system that suddenly attacks the large intestine or its microbiome causing white blood cells (mainly neutrophils) to stream into the colonic epithelium resulting in inflammation and colitis. The exact immune

abnormality has never been established despite intense ongoing research since the mid-20th century when autoimmunity was initially investigated as a cause of this disease [13]. Since then, several descriptive iterations have evolved to convey a putative causal immunological dysfunction in order to explain UC such as, immune dysregulation, disordered immunity, or colonic immuno-deficiency, all

of which lack definitive experimental evidence and continue to remain speculative in nature [14,15].

An alternative evidence-based pathogenesis, proposed in 2005, posits that excess H_2O_2 produced by colonic epithelial cells lining the inner surface of the large intestine initiates inflammation after diffusing through the cell membrane to the extracellular space. Hydrogen peroxide's unique properties of cell membrane permeability, long life, potent oxidizing potential, and neutrophilic chemotactic capability combine to promote oxidative disintegration of colonic epithelial tight junctional proteins (facilitating mucosal bacterial penetration) while simultaneously attracting white blood cells into the colonic epithelium, both of which lead to colonic inflammation and eventual ulcerative colitis [16].

This novel theory of UC is supported by studies demonstrating significantly elevated levels of H_2O_2 in the mucosal lining of the large intestine of individuals with UC prior to the onset of inflammation implying a causal role in the pathogenesis of this disease [17]. The observation that reducing H_2O_2 can completely heal colonic inflammation in a large percentage of patients with refractory UC provides additional evidence supporting the conclusion that colonic H_2O_2 is the upstream cause of inflammation in this disease. This interpretation is supported by studies in animal models reporting mucosal inflammation that is histologically indistinguishable to human UC after rectal installation of H_2O_2 [18]. Ulcerative colitis is also reported to be a reproducible occurrence in humans after H_2O_2 was inadvertently introduced into the large intestine of several patients undergoing colonoscopy [19]. Additionally, glutathione peroxidase (GPx) knock-out murine models that are unable to neutralize H_2O_2 develop colitis analogous to human UC (GPx is the main enzyme needed to neutralize H_2O_2) [20].

This new theory of ulcerative colitis greatly facilitates achieving and maintaining remission because, for the first time, all exacerbating environmental factors can be classified as oxidative stressors that increase colonocyte hydrogen peroxide. This allows for a mechanistic explanation to identify environmental oxidative stress exposure, which can be anticipated to increase colonocyte H_2O_2 . Thus, the onset and relapse of UC is no longer unpredictable but occurs subsequently to oxidative stress exposure with a defined mechanism, which identifies H_2O_2 as the initiating causal agent of the colitis. Induction is achieved by elimination of extracellular colonocyte H_2O_2 and remission is maintained by simultaneously normalizing intracellular colonocyte H_2O_2 .

This greatly simplifies the overall treatment of UC. Currently, there are 46 different clinical practice treatment guidelines advocated for the treatment of outpatient UC based on location of disease, drug history, and severity of inflammation [21-23]. In contrast, treatment aimed at restoration of colonic redox homeostasis has the same goal regardless of location or severity of inflammation -- which is the reduction of colonic H_2O_2 that data support as the upstream causal factor in the development of UC. Refocusing efforts to restore colonic redox homeostasis significantly simplifies therapy and engenders the possibility of a functional cure. Oxidative stressors can be gleaned from a social and dietary history in addition to laboratory evaluation [10].

Although remission may be achieved in a sub-set of patients with drugs directed at the immune response, not all remission is the same.

Histologic remission achieved with immunosuppression, immunomodulating or biologic agents (biologics) obscures the underlying increase in colonocyte H_2O_2 -induced oxidative stress and, after years of exposure, cellular H_2O_2 will eventually permeate and overcome nuclear antioxidant (reductive) protective mechanisms leading to oxidative nuclear DNA mutations in tumor suppression and oncogenes that promote colorectal cancer [24,25].

This is supported by a recent study, which reported an over 70% increase in the prevalence of colonic cancer and precancerous lesions (dysplasia) in UC patients receiving chronic immunosuppressive agents such as calcineurin inhibitors and anti-TNF (tumor necrosis factor) biologic agents [25,26]. Other studies report new and worsening extra-intestinal manifestations in up to 30% of patients with inflammatory bowel disease after receiving certain biologic agents [27]. This implies that there is a higher standard of healing in UC than just the absence of inflammation. The data suggest that this higher standard of healing is defined by normal colonic epithelial H_2O_2 because elevated H_2O_2 can initiate relapse, interfere with normal colonocyte biochemical functionality and facilitate the development of colon cancer. Thus, the use of long-term immunosuppression/modulation or biologics for the treatment of ulcerative colitis may be shifting the burden of disease from tractable colonic inflammation to refractory disease in addition to colon cancer, which is difficult to detect early and, consequently, carries a higher mortality rate [28].

Diagnostics can also benefit from this new understanding of ulcerative colitis. Currently, microscopic diagnosis depends on visually recognizing characteristic histologic findings such as cryptitis and crypt abscesses, which the data imply is secondary to the neutrophilic chemotactic effect of hydrogen peroxide as it diffuses out of colonic epithelial cells to the extracellular microenvironment. As studies have shown, direct measurement of mucosal hydrogen peroxide is possible and may be pathognomonic for ulcerative colitis [17]. This advances the diagnosis of ulcerative colitis from an empirical qualitative and subjective realm into a quantitative science.

Although the patient had been taking balsalazide 1.5 g bid for years prior receiving the novel therapy in 2007 and daily since then, this sub-therapeutic dose is not known to induce or maintain remission in ulcerative colitis and is not felt to have significantly contributed to his histologic remission soon after receiving the novel therapy in 2007 or during the 12-year follow-up colonoscopy with biopsy. As mentioned above, the patient reports completely normal bowel movements during this 12-year period. We also considered the possibility of a spontaneous remission but believe this to be highly unlikely due to his 39-year history of unresponsive/refractory disease to standard medical therapy and the rapid complete mucosal (histologic) healing occurring soon after administration of this novel therapy followed by 12 years of normal bowel movements culminating in documented histologic remission at the 12-year follow-up colonoscopy and biopsy.

Conclusion

After nearly four decades of poorly responsive disease culminating in refractory ulcerative colitis in the patient presented herein, prolonged (12 years) of complete mucosal healing with re-establishment of histologically normal mucosa were obtained by the

restoration of colonic epithelial redox homeostasis, which accompanies therapeutic reduction of colonic hydrogen peroxide. There is compelling evidence that ulcerative colitis is caused by excess colonocyte hydrogen peroxide as a result of impaired redox homeostasis secondary to uncompensated oxidative stress exposure.

Taken together, the available theoretical, experimental and clinical evidence implicating a causal role for colonocyte hydrogen peroxide in the pathogenesis of ulcerative colitis strongly suggest that the appropriate treatment should be aimed at restoration of colonic redox homeostasis by reduction of colonic hydrogen peroxide prior to considering long-term immunosuppression or immune modulation with biologics or other agents, which carries serious adverse effects and an increased risk of colon cancer.

Conflict of Interest

The authors declared no conflicts of interest with respect to the authorship and/or publication of this article.

References

- Magro, F, Gionchetti P, Eliakim R and Ardizzone S, et al. "Third European evidence-based consensus on diagnosis and management of ulcerative colitis. Part 1: definitions, diagnosis, extra-intestinal manifestations, pregnancy, cancer surveillance, surgery, and ileo-anal pouch disorders". *Journal of Crohn's and Colitis* 11(2017):649-70.
- Ungaro, R, Mehandru S, Allen PB and Peyrin-Biroulet L "Ulcerative colitis." *Lancet*. 389(2017):1756-1770.
- Ng, SC, Shi HY, Hamidi N and Underwood FE et al. "Worldwide incidence and prevalence of inflammatory bowel disease in the 21st century: a systematic review of population-based studies." *Lancet* 390(2017): 2769-2778.
- Alatab, S, Sepanlou SG, Ikuta K and Vahedi H et al. "The global, regional, and national burden of inflammatory bowel disease in 195 countries and territories, 1990–2017: A systematic analysis for the Global Burden of Disease Study 2017." *The Lancet Gastroenterology & Hepatology*. 5(2020): 17-30.
- Lichtenstein GR, Shahabi A, Seabury SA, Lakdawalla DN, Espinosa OD, Green S, Brauer M, Baldassano RN. Lifetime Economic Burden of Crohn's Disease and Ulcerative Colitis by Age at Diagnosis. *Clinical Gastroenterology and Hepatology*. 2019 Jul 18. <https://doi.org/10.1016/j.cgh.2019.07.022> (article in press)
- Rubin, DT, Dubinsky MC, Panaccione R and Siegel CA et al. "The impact of ulcerative colitis in patients' lives compared to other chronic diseases: a patient survey." *Digestive Diseases and Sciences* 55(2010):1044-1052.
- Calvet, X, Argüelles-Arias F, López-Sanromán A and Cea-Calvo L et al. "Patients' perceptions of the impact of ulcerative colitis on social and professional life: Results from the Uc-liFe Survey of Outpatient Clinics in Spain." *Patient Preference and Adherence* 12(2018):181-1823.
- Vadstrup, K, S Alulis, A Borsi and J Olsen et al. "DOP78 Intestinal surgery rates in ulcerative colitis and Crohn's disease in the era of biologics: A Danish Nationwide Register Study from 2003 to 2016." *Journal of Crohn's and Colitis* 14(2020):S116-117.
- Liu, ZX, Kiran RP, Bennett AE and Ni RZ et al. "Diagnosis and management of dysplasia and cancer of the ileal pouch in patients with underlying inflammatory bowel disease." *Cancer* 117(2011):3081-92.
- Pravda, J. "Radical induction theory of ulcerative colitis." *World Journal of Gastroenterology* 11(2005): 2371-2384.
- Pravda, J, Weickert MJ and Wruble LD. "Novel Combination Therapy Induced Histological Remission in Patients with Refractory Ulcerative Colitis." *Case Series Report J Inflamm Bowel Dis Disor* 4(2019):130.
- Regueiro, M, Loftus EV, Steinhardt HA and Cohen RD. "Clinical guidelines for the medical management of left-sided ulcerative colitis and ulcerative proctitis: summary statement." *Inflammatory Bowel Diseases* 12(2006): 972-978.
- Broberger, O and Perlmann P. "Autoantibodies in human ulcerative colitis." *J Exp Med* 110(1959):657-674.
- Kirsner, JB. "Historical origins of current IBD concepts." *World Journal of Gastroenterology* 7(2001): 175-84.
- Ferguson, A. "Ulcerative colitis: How can we test theories of immune dysregulation?" *European Journal of Gastroenterology & Hepatology*. 8(1996):101-04.
- Pravda, J. "Can Ulcerative Colitis be Cured?" *Discovery Medicine*. 27(2019):197-200.
- Santhanam, S, Venkatraman A and Ramakrishna BS. "Impairment of mitochondrial acetoacetyl CoA thiolase activity in the colonic mucosa of patients with ulcerative colitis." *GUT* 56(2007):1543-1549.
- Sheenan, J and Brynjolfsson G. "Ulcerative colitis following hydrogen peroxide enema." *Lab Invest* 9(1960):150-167.
- Meyer, CT, Brand M and DeLuca VA. "Hydrogen peroxide colitis: a report of three patients." *J Clin Gastroenterol* 3(1981):31-35.
- Esworthy, RS, Aranda R, Martin MG and Doroshov JH. "Mice with combined disruption of Gpx1 and Gpx2 genes have colitis." *Am J Physiol Gastrointest Liver Physiol* 281(2001): G848-855
- Rubin, DT, Ananthakrishnan AN, Siegel CA and Sauer BG et al. "ACG clinical guideline: ulcerative colitis in adults." *American Journal of Gastroenterology* 114(2019):384-413.
- Ko, CW. "AGA clinical practice guidelines on the management of mild-to-moderate ulcerative colitis." *Gastroenterology*. 156(2019):748-764.
- Feuerstein, JD, Isaacs KL, Yechezkel Schneider Y and Siddique SM et al. "AGA Clinical Practice Guidelines on the Management of Moderate to Severe Ulcerative Colitis." *Gastroenterology* 2020 article in press.
- Seril, DN, Liao J, Yang GY and Yang CS. "Oxidative stress and ulcerative colitis-associated carcinogenesis: studies in humans and animal models." *Carcinogenesis*. 24(2003):353-62.
- Qi, L, Wu XC and Zheng DQ. "Hydrogen peroxide, a potent inducer of global genomic instability." *Current Genetics* 8(2019):1-5.
- Uchino, M, Ikeuchi H, Hata K and Okada S et al. "Changes in the rate of and trends in colectomy for ulcerative colitis during the era of biologics and calcineurin inhibitors based on a Japanese nationwide cohort study." *Surgery today* 15(2019):1-8.
- Dimopoulos, C, Hung K, Procto D and Ruggiero E et al. "Effects of vedolizumab on extraintestinal manifestations in inflammatory bowel disease." *Gastroenterology*. 158(2020):S32-33.
- Sunkara, S, Swanson G, Forsyth CB and Keshavarzian A. "Chronic inflammation and malignancy in ulcerative colitis." *Ulcers* (2011).

How to cite this article: Pravda, Jay, Richard Gordon and Pamela B. Sylvestre. "Sustained Histologic Remission (Complete Mucosal Healing) 12 Years after One-Time Treatment of Refractory Ulcerative Colitis with Novel Combination Therapy: A Case Report." *J Inflamm Bowel Dis Disor* 5 (2020): 132. doi: 10.37421/JIBDD.2020.5.132