

Staining Potentials of Indigenous *Hibiscus sabdariffa* Calyx, *Lawsonia inermis* Leaves and *Vitex Doniana* Stem Barks on Liver and Kidney Tissues

Nnaemeka Okolie^{1*}, Ngokere AA² and Enweani IB²

¹Masters in Histopathology at Imo State University Owerri, Nigeria

²Department of Medical Laboratory Science, Nnamdi Azikiwe University, Awka, Nigeria

Abstract

Tissues acquired from the bodies of human or animals are transpicuous after tissue processing. Without tissue staining, the individual components of these tissues cannot be seen and appreciated. Haematoxylin extracted from the heartwood of a small tree, Haematoxylin campechlanum (Logwood) alongside synthetic eosin, constitutes the most commonly used Hematoxylin and Eosin staining method in histopathology laboratories. In view of the hazards associated with the use of synthetic stains and the escalating cost of foreign dyes, it has become essential to seek for natural, economic, easy to use, biodegradable, safe (to both human and environmental health) and more eco-friendly alternatives or supplements to the routine Haematoxylin and eosin stains. Thus, the present study is aimed at evaluating the staining potentials of indigenous *Hibiscus sabdariffa* calyx, *Lawsonia inermis* leaves and *Vitex doniana* stem barks on liver and kidney tissue slides. Ethanolic, aqueous, mordant and non mordant sohex extracts of the plant products were substituted for haematoxylin (as primary stains) in the modified haematoxylin and eosin methods. Results revealed that the three plant products imparted various intensities of pink or pale pink colouration on the cytoplasm of the constituent cells without any form of nuclear staining at a concentration of 100mg/ml. Observed acidic nature of all the three plant extracts was probably responsible for their failure to stain the nucleus in keeping with the general staining principle that only basic stains do clour the acidic nucleus. It is recommended that more studies be carried out to provide methods for increasing the pH of the extracts to the alkaline (basic) side of neutrality for effective nuclear staining.

Keywords: Hibiscus sabdariffa • Lawsonia inermis • Vitex doniana • Ethanolic extracts • Aqueous extracts

Introduction

All tissues and their constituent cells are usually transparent and colorless; different structures cannot be easily distinguished from each other when examined with the conventional light microscope. Fortunately, histological techniques used for the distinction of tissues component commonly cause two changes in the tissue, either an alteration of contrast or an alternation in colour. These changes can be achieved by staining method. Successful staining methods are both specific and sensitive. Specificity or selectivity is the ability to discriminate between individual tissue components and to colour one or a few of these, leaving others unstained. Tissues acquired from the bodies of human or animals are transpicuous after tissue processing. Without tissue staining, the individual components of these tissues cannot be seen and appreciated. Hence dyes help in diagnosis of ailment because they allow for easy identification of normal and pathological tissue structures by coloring the various components of the tissues.

Haematoxylin is extracted from the heartwood of a small tree, Haematoxylin campechlanum (Logwood), which originated in Mexico and has been cultivated in Jamaica. It is one of the most widely used dyes in histology and will be described later but in its natural form it

***Address for Correspondence:** Nnaemeka Okolie, Professor of Parasitology with Masters in Histopathology at Imo State University Owerri, Nigeria, Tel:+2348033761933; E-mail: profnnadegreat@gmail.com

Copyright: © 2021 Okolie N. This is an open-access article distributed under the terms of the Creative Commons Attribution License, which permits unrestricted use, distribution, and reproduction in any medium, provided the original author and source are credited.

Received 24 February 2021; **Accepted** 11 March 2021; **Published** 18 March 2021

has little or no staining capacity and requires oxidation to haematein, either naturally by contact with air or chemically with an oxidizing agent such as sodium iodate or mercuric oxide. Together with Eosin, haematoxylin forms Hematoxylin and Eosin staining method and is the most commonly used staining method in histopathology laboratories. Hematoxylin and eosin staining method is the most widely and commonly used staining method in histopathology. It plays a crucial role in diagnosis of tissues Hematoxylin is natural while eosin is synthetic. These dyes are not produced locally but in foreign countries and are imported to Nigeria. The high cost of importation of these dyes together with the biological hazards of using synthetic dyes has made the search for natural, less expensive, safer, non-allergic, non-toxic and safer alternative dyes of utmost priority. The most routinely used dyes in histopathology are haematoxylin and Eosin. The use of these dyes and other synthetic dyes is restricted due to the discovery of their hazardous nature, especially eosin. Also most developing countries can no longer afford the ever-increasing cost of these dyes. Consequently, the need for evaluation of staining potentials of indigenous plant products which are domestically available, easy to prepare and use and resistance to fading becomes paramount.

Due to the necessity and importance of staining in histopathology, the hazards of using synthetic dyes and the escalating cost of foreign dyes, it has become essential to seek for natural, economic, easy to use, biodegradable, easily available, safe to both human and environmental health and more eco-friendly alternatives or supplements to the routine Haematoxylin and eosin stains, hence the importance of the present study. Although staining potentials of either aqueous or ethanolic extracts of *Hibiscus sabdariffa*, and *Lawsonia inermis* have been slightly studied and documented, a comparism

of staining efficacy of aqueous and ethanolic extracts have not been extensively investigated. To the best of the author's knowledge, there is only one published article on the use of both ethanolic and aqueous methods of extraction [1]. Also, there was no previous attempt to evaluate the staining potentials of each of the plant products in combination with others for probably improved staining results nor were there studies aimed at investigating the stability of the extracts after preparation. Pathological features of tissues had not been previously highlighted nor the effects of mordant on the staining efficiency been investigated. Determination of optimal staining concentrations are yet to be elucidated.

The calyx of *Hibiscus* is a very important dye producing parts of the plants. It contains dye coloring substance which has previously been used extensively and locally in African communities to color fabrics, fibres and textiles. Extracts obtained from plant, *Lawsonia inermis* and *Vitex doniana* hold much potential as a future source of cheaper stain. In this study, three indigenous dye yielding plants will be selected for the purpose of obtaining their aqueous and alcoholic dye extracts which will invariably be applied to histological staining of selected pathological and normal liver and kidney tissues at varying concentrations and pH in an attempt to investigate their usefulness as potential sources of stains in histopathology.

The aim of the study is to investigate the staining potential of the aqueous and ethanolic extracts from calyx of *H. sabdariffa*, leaves of *Lawsonia inermis* and stem barks of *Vitex doniana* on pathological and normal Liver and Kidney. The above listed plants have been found to be readily available, the dyes are also cheaper to extract from these plants. The exorbitant cost of importation of foreign dyes together with the various biological and ecological hazards of the use of synthetic dyes has made the use of locally sourced dyes in staining of tissues necessary and inevitable. This study will hopefully help to form the basis for more analysis and research for a broader recognition of the natural products from plants as a viable source of histological dyes.

Literature Review

Hibiscus sabdariffa is a shrub belonging to Kingdom Plantae, Phylum Angiosperm, Class Eudicots, Order Malvales, Family Malvaceae, Genus *Hibiscus*, Species *sabdariffa*. It is a species of hibiscus thought of as being found in Asia (India to Malaysia) or tropical Africa. The leaf of *Hibiscus sabdariffa* is said to contain protein, carbohydrates, fat, fibre, ash, calcium, phosphorus, iron, thiamine, betacarotene, riboflavin, niacin and ascorbic acid (vitamin C). It also contains α -terpinyl acetate, anisaldehyde, β -sitosterol, β -D-galactoside, isopropyl alcohol, methanol, benzyl alcohol, ethanol and malic acid [2]. The flower produces a yellow dye; the major pigment identified is daphniphylline. The flower is also made up of chemical components such as carbohydrates, arabinans, mannose, sucrose, thiamine, xylose, mucilage, niacin, pectin, protein, fat, riboflavin, β -carotene, citric acid, ascorbic acid, malic acid, maleic acid, hibiscic acid, oxalic acid, tartaric acid, glycolic acid, utalonic acid, delphinidin, gossypetin, resin, dietary fiber, mineral and ash [3].

The dried calyces is made up of the flavonoids such as hibiscitin and hibiscetin, gossypetin and sabdaretin. It also contains alkaloids, β -sitosterol, anthocyanin, citric acid, cyanidin-3-rutinoside, delphinidin,

galactose, pectin, protocatechuic acid, quercetin, stearic acid and wa.. The calyces were found to be high in acids and pectin. It has been shown through analysis of the calyces that it contains crude proteins and minerals such as iron, phosphorus, calcium, magnesium, manganese, aluminium, sodium, potassium, mucilage, citrate, ascorbic acid and gossypetin. The seeds contain proteins (18.8 to 22.3%), fats (19.1 to 22.8%) and dietary fibre (39.5 to 42.6%). The seeds were also discovered to be rich in mineral content. Some of the minerals found in the seed includes: phosphorus, magnesium, calcium, lysine and tryptophan. Seed oil is rich in unsaturated fatty acids (about 70%). The most abundant unsaturated fatty acid is linoleic acid. Seeds are also made up of nitrogen, fatty oil, cellulose, pentosans and starch [4]. Steroids and tocopherols have also been reportedly found in the seed oil. The fruits contain α -terpinyl acetate, pectin, ascorbic acid, calcium oxalate, caprylic acid, citric acid, acetic acid, ethanol, formic acid, pelargonic acid, propionic acid, isopropyl alcohol, methanol, benzyl alcohol, 3-methyl 1-butanol, benzaldehyde and minerals. The root contains tartaric acid and saponin.

The calyx of *Hibiscus sabdariffa* is a very important dye-yielding material. It has a red color as earlier stated. The calyx contains the flavonoids (hibiscitin and hibiscetin) as its principal component as could be seen initially from the phytochemicals of the plants. A red colored dye is produced when the chemical component of the calyx is extracted. Several investigations have been carried out on the dyeing properties of the red colored calyx. Some of these are as follows:

(i) The watery extract of roselle with various modifications was applied on the testicular tissue section of a rabbit. Best staining results were observed when iron alum or potassium alum were used to mordant the extract [5].

(ii) Methanolic extract of *Hibiscus sabdariffa* was applied to stain tissues with fungal infection and diagnostic results were obtained [6].

(iii) Extract from *Hibiscus sabdariffa* was used in the staining of histological sections from the small intestine.

(iv) Formalin fixed paraffin wax embedded tissue sections were stained using *Hibiscus sabdariffa* extracts mixed with ferric chloride and glacial acetic acid and efficiency of the solution as a progressive nuclear stain substitute for hemalum in Hematoxylin and Eosin staining procedure was reported

(v) It was reported by Eman A Hashim [7] that the purified acidic part of *Hibiscus sabdariffa* could be used in place of eosin because this part has almost the same physical and chemical characteristics to the eosin stain [7].

(vi) Staining of fungal specimens was performed using aqueous and alcoholic extracts of *Hibiscus sabdariffa*. The study has shown that the red dye produced from the calyx of *Hibiscus sabdariffa* has high affinity for mycological organisms and positive staining results have been produced [8].

Lawsonia inermis (Henna, also known as El-Henna, Egyptian priest, and mignonette tree. is a perennial shrub native to North Africa, Asia and Australia. It is naturalized and cultivated in the tropics of America, Egypt, India and parts of the Middle East [9]. It is widely distributed across the Northern and Southern parts of Nigeria. Henna is mostly grown in home gardens and commercial production

is limited to a few places in India, Pakistan, Iran, Egypt, Libya, Niger, Nigeria and Sudan [10].

The dyeing agent in henna is Lawsone or 2 hydroxy 1, 4 naphthoquinone (naphthalenedione), which is present in dry leaves at a concentration of 0.5 – 2% (Figure 1).

It attaches itself strongly to proteins, and as a result the dye is very fast [11]. Other components in henna such as flavonoids (luteoline, acacetine) and garlic acid contribute as organic mordant to the colouring process; carbohydrates (vegetable gelatin, mucilage) give the henna paste a suitable consistency to attach to hair and also possibly play a role in the penetration of lawsone into the hair and other tissues. The stem flowers yield 0.01 – 0.02% essential oils mainly and -lonones, which can be used as a basis for perfumes. The seeds contain 10% of non-dyeing viscous oil, composed mainly of oleic, linoleic and stearic acids. The leave extract showed antitumour and tuberculostatic effect in tests with mice. The extract of dye from *Lawsonia* in ethyl alcohol and water could be used effectively to stain lignified plant tissues when employed in single staining [12-20]. Henna leaves (cold or hot aqueous) extract when oxidized, could be used as a suitable substitute to the usual counter stain used in gram staining procedure [20-23]. Aqueous and ethanolic extract of *Lawsonia* were used to stain epidermal cells of *Allium cep L* [13].

Vitex doniana (Black plum)

Vitex doniana belongs to the Kingdom Viridiplantae (green plants), phylum Streptophyta (land plants), class Magnoliopsida (dicotyledons), order Lamiales (dicotyledonous flowering plants), family Lamiaceae (Flowering plants), genus *Vitex*, species *Vitex doniana*. Common names of *Vitex doniana* are as follows: black plum, African oak (English), dinya (Hausa), ucha koro (Igbo) and oori-nla (Yoruba). It is a medium-sized deciduous tree, 8-25m high with a heavy rounded crown and a clear bole up to 5 m. It has a rough bark; pale brown or grayish-white, rather smooth with narrow vertical fissures [14].

Phytochemical analysis of *Vitex doniana* revealed the presence of the following active compounds: alkaloids, saponins, tannins, Anthraquinones, flavonoids, terpenoids and cardiac glycosides. Alkaloids have pharmacological activity. Saponins are essential in soap production. Tannins play a role in plant protection from predators and could also serve as pesticide. Anthraquinones are sources from which most synthetic dyes are derived. Flavonoids are responsible for plant colouration and pigmentation. Terpenoids are used extensively for their aromatic qualities and play a role in traditional herbal remedies. Cardiac glycosides have therapeutic uses in the treatment of cardiac failure.

Liver is the largest organ present in vertebrates and some other

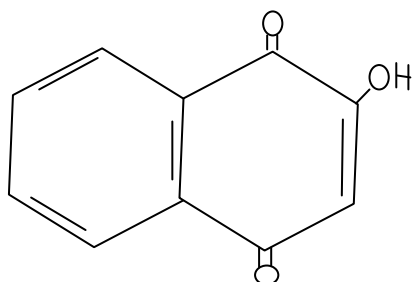


Figure 1. C₁₀H₆O₃ (2-hydroxy-1, 4-naphthoquinone).

animals. It plays a number of vital roles which include production of biochemical substances useful in the digestion of food, detoxification and the synthesis of protein, hormone production, and decomposition of red blood cells. Liver is located just before the diaphragm in the abdominal pelvic region. It is responsible for metabolic regulation, haematological regulation, and bile production. Pathology of liver include liver Cirrhosis, alcoholic Liver disease, alcohol hepatitis, alcohol abuse, hepatocellular and Changio Carcinoma and hereditary diseases to mention but a few have presented an impressive record of the pathology of the tissues. Kidneys are a pair of bean-shaped organs which perform useful regulatory functions in most animals and man. They constitute an integral part of urinary system and also perform the following haemostatic functions: the regulation of electrolytes, maintenance of acid –base balance and regulation of pressure through the instruments of salt and water balance [15]. Kidneys filter blood by removing wastes from blood and diverting them to the urinary bladder. They also produce urine by excreting wastes such as urea and ammonium. Other functions of the kidney include reabsorption of water, glucose and amino acids, production of hormones such as calcitriol, erythropoietin and rennin [16]. Kidney is situated at the back of the abdominal cavity within the retroperitoneum where it receives blood from paired renal arteries and drains same into the paired renal vein. Urine is excreted from each of the kidneys into another paired structure known as the ureter which in turn empties into the urinary bladder [17,18]. Patients with kidney diseases commonly present the following clinical conditions; nephritic and nephrotic syndromes, renal cysts, acute kidney injury, chronic kidney disease, urinary tract infection, nephrolithiasis and urinary tract obstruction [19-20]. Apart from the most commonly encountered renal cell carcinoma in adults, other forms of kidney cancers exist [21-25].

Materials and Methods

Materials and methodology employed in this study is in accordance with the standard operating procedures (SOPs) applied at the Histopathology Department of the Imo State University, Owerri. Study area chosen for this study was the Histopathology Department of Imo State University, Owerri, Nigeria. Owerri is the capital city of Imo State in South Eastern Nigeria. Located on latitudes 502511 50.23n and longitudes 70211 149.33E. It covers approximately 40 square miles in (100 km²). The climate of the area which enhances the growth and thriving of the plant products is tropical with annual rainfall of about 1000mm and temperature range of between 22.7°C and 33.7°C. Igbo is the predominant ethnicity in the area. The study population employed the use of some classically selected organs such as liver and kidney, obtained from some autopsy samples received from the Histopathology Department of the Federal Medical Centre Owerri. Plant samples were obtained from Nnewi and Owerri, Eastern Nigeria, identified at the herbarium of the Botany Department of Imo state University and given voucher numbers.

Sample size determination

Sample size determination was carried out using the method of Ari (2017) as follows:

$$SS = (Z^2 \times p (1-p)) / ME^2$$

Where,

SS = sample size

Z = the Z score for 95% confidence interval (as obtained from statistical table) which is 1.96

p = the standard deviation of the population (due to the fact that autopsy and biopsy samples population were unknown, the standard deviation of the population (P) was assumed to be 0.5)

ME = Margin of error which is 5% (5/100) = 0.05

Substituting, the sample size becomes:

$$1.962 \times (0.5 (1-0.5)) / 0.052 = 385$$

Ethical approval

In view of the fact that tissue specimens will be prepared from autopsy samples and stained with indigenous plant products to determine the suitability or otherwise of the plant products as histopathological stains, ethical approval for the purpose of procuring autopsy samples was obtained from Federal Medical Centre, Owerri. The confidentiality and anonymity of the research respondents was ensured by assigning numbers to the autopsy samples without indicating the names or identification of the deceased from where they will be obtained. The only information which is provided in the research is the pathological conditions of the samples.

An informed consent without pressures such as coercion, threats or persuasion was obtained from the next of kin of the deceased from whom the samples were collected. Prior to this, every detail regarding the purpose of the research, absence of harm and how anonymity was to be ensured was fully communicated to them. This was necessary in order to guide against feeling of deception, exploitation, shame or being wronged.

Tissue processing

Pathological and normal liver and kidney tissues (3mm thick) were obtained from the teaching hospital. Rapid manual tissue processing was applied as follows: The organs were immediately fixed in 10% neutral buffered formalin for 48 hours. They were cut up into small representative portions, put into properly labeled tissue cassettes and subjected to the tissue processing. The tissues were dehydrated through the indicated grades and changes of ethanol for the stipulated period as follows: 70% ethanol (for 2 hours), 90% ethanol I (for 2 hours), absolute ethanol III (for 1-2 hours), absolute ethanol III (for 1-2 hours), absolute ethanol IV (for 1-2 hours). The tissues were cleared in two changes of Xylene (Xylene I for 2 hours, Xylene II for 2 hours). Solid paraffin wax was cut into tiny bits and placed in a stainless steel plate. The wax was heated using a hot-air oven to 2°C above the melting point of paraffin wax and sufficient quantity of the molten wax was poured into the moulds so as to adequately cover the tissue.

The tissues were oriented centrally in the block moulds containing the molten paraffin wax using warm forceps to ensure that tissues are cut in the right planes during microtomy. The mould containing paraffin wax was then covered using the base of the tissue cassette so as to allow the blocks to solidify against the back of the cassette. The molten wax was then allowed to cool using an ice bath. When the blocks set, they were removed from the moulds using forceps. Excess wax was removed from the body of the cassette for easy

microtomy. The tissue was placed into the moulds containing three changes of paraffin wax for the following indicated period of time; paraffin I (for 2 hours), paraffin II (for 2 hours), paraffin III (for 4 hours). The blocks were trimmed using a rotary microtome (SHANDON AS325) to expose the tissue surface and placed in an ice bath before sectioning with the microtome. Sectioning was done at 5 microns and the sections were then floated onto a hot water bath set at 10°C below the melting point of paraffin wax. Albumenized slides were then used to pick up the floating sections from the water bath. A hot plate was used afterwards to attach the sections firmly to the slides. The sections, after passing through the bake-on process were kept for staining.

Staining procedure

Staining with plant products as a primary stain The slide was dewaxed in xylene and taken to water. It was stained with plant extract staining solution for 35 to 60 minutes, washed in tap water, stained with eosin for 2 minutes. The slide was dehydrated in ascending grades of alcohol (50%, 75%, 95% and Absolute), cleared in xylene and mounted with DPX.

Extraction of plant products

Ethanol extraction method: Plant products were sun dried for 48 hrs and crushed using a laboratory blender. One hundred grams (100 g) of the rough powdered material was soaked in 1000 ml of absolute ethanol giving a concentration of 100 mg/ml, macerated and filtered with chess material and whatman No.1 filter paper and the solvent was removed with rotary evaporation at 50°C to obtain the dye extract or paste.

Aqueous extraction method: 100g of the powdered plant products were soaked in 1 litre of boiled distilled water (100mg/ml). It was left for 1 hour and the solution was then filtered using whatman No. 1 filter paper. The filtrate was dried in a hot air oven for 3 days to remove residual water. The residue was then removed, weighed and stored in an airtight container. For each extract, two staining solutions were prepared. (a) Without mordant. (b) With mordant and other reagents added. The compositions of the two staining solutions are given below.

(a) Plant product solution without mordant: Extract: 1 g, solvent (water or alcohol): 10 ml

(b) Plant product solution with mordant: Extract: 1 g, solvent (water or Alcohol): 10 ml, alum: 0.5 g, acetic acid: 1ml. Few drops of iodine. The solution was boiled and allowed to cool before staining. The ph was adjusted by either the addition of acetic acid or Sodium carbonate drop by drop until an acidic or alkaline ph is obtained.

Preparation of plant materials

Fresh leaves of *Lawsonia inermis* were collected and washed thoroughly under running tap water before drying. The calyces of *Hibiscus sabdariffa*, and fresh barks of *Vitex doniana* were air-dried properly for 7 days. They were subjected to grinding with the aid of a mechanical grinder to powdery form, sieved and stored in a dry container. The powder was then divided into two parts. Aqueous and alcoholic extractions were then carried out on the powdered material using sohex extraction method to acquire a pure extract, which was used for staining.

Experimental design

Phase one: This phase was for determination of the optimal staining concentration of the three plant products.

Preparation of various concentrations of the extracts

1g of each of the plant extracts was dissolved in 10ml of absolute alcohol to give a concentration of 100mg plant product/ml of absolute alcohol. Four different concentrations were made as follows 100% (100mg/ml), 75% (75 mg/ml), 50% (50 mg/ml) and 25% (25 mg/ml).

An breakdown of the research protocol for each plant product was as follows (Table 1):Composition of *Vitex* staining solution were as follows

Concentration of extract used	= 100 mg/ml
Aqueous <i>Vitex</i> solution	= pH 5.1
Ethanollic <i>Vitex</i> solution	= pH 5.2
Alum	= 0.3g x 2
Acetic acid	= 3 drops
Ammonia	= 3 drops
Iodine	= 2 drops

The stain was used as counter (secondary) acidic stain [12].

Phase two: Phase two was for the staining potentials of 100 mg/ml freshly prepared plant extracts. During this phase, specific methods for extraction of various plant extracts and specific staining methods were adopted. Again, the plant extracts acted as a primary stain (*H. sabdariffa*, *Lawsonia inermis*, *Vitex doniana*). As a primary stain, the indicated plant products replaced haematoxylin while eosin was still applied as a counter stain in the modified Haematoxylin and eosin technique.

Intensity and clarity of staining with the plant products

Every stained slide was observed by 6 persons under tutelage of renowned histopathologists (Prof. Obioma Okechi of Abia State University and Prof. O.G. Avwioro of Delta State University according to the method and check list of Walker (2006). The check lists for reporting the intensity and clarity of the stained slides were as follows:

1. Deeply stained and clear, optimal nuclear staining observed
2. Moderately stained, clear, moderate nuclear staining observed
3. Lightly stained, slightly clear, slight nuclear staining observed
4. Very lightly stained, lacks clarity, no nuclear staining

The category with the highest observed frequency was reported

for every stained slide

Phase three: Phase three was for the determination of the durability of the plant extracts. Here, the extracts were applied to the tissue slides six months after extraction and their staining potentials compared to the slides in phase two when the extracts were freshly prepared. The methodology adapted during this phase is that of phase two. Also, each of the plant products was used as a mono-stain to stain the tissues without involvement of eosin

Procedure for staining slides with plant products as mono-stains

The slides were dewaxed in xylene and taken to water. They were stained with mordant and non mordant *Hibiscus sabdariffa* staining solution for 35 minutes or *Lawsonia inermis* for 40 minutes or *Vitex* solution for 60 minutes. The slides were washed in water, dehydrated in ascending grades of alcohol (50%, 75%, 95% and Absolute), cleared in xylene and mounted with DPX.

Microscopy and photomicrography

Sections were viewed and photomicrograph using Leica Binocular Microscope DM 1000 in-built digital camera. The photomicrograph of pathological and normal tissues stained with dyes extracted from the various plant materials were taken using x 100 magnifications and printed by an inkjet printer. Eroschenko (2013) provided a guide for the labeling of the photomicrographs.

Results

Staining with freshly prepared *Hibiscus* extract solution as a primary stain (both aqueous and alcoholic) without mordant gave the cytoplasm of the tissues a pink colouration, but the nucleus was not stained (Table 2, plates 1 and 2). Addition of mordant and acetic acid produced the same result but with increased intensity and clarity. In contrast, staining with the conventional haematoxylin and eosin stains produced a very deep pinkish colouration as well as deep blue staining nucleus (plates 8 and 9). Nuclear staining was not observed when all the *Lawsonia inermis* (aqueous, ethanolic, mordant, non-mordant, with addition of ammonia and/or acetic acid) extracts were used as primary stain in place of haematoxylin in the study. Also, in all the cases, the cytoplasm portrayed moderate intensity of either pale pink or pink colouration (plates 3 and 4, Table 3). Staining results obtained with *Vitex doniana* as a primary stain revealed no nuclear staining (Table 4, plates 5 to 7). Table 5 summarized the staining intensities and clarity of features in tissue slides stained with freshly prepared different forms (ethanolic, aqueous, mordant and non-mordant) of each of the plant products (*Hibiscus sabdariffa*, *Lawsonia inermis* and *Vitex doniana*) alongside eosin.

Table 1. Protocol for determination of effective concentration of plant extract.

Serial no	Groups of Tissue Slides	Concentration of Each of the Extracts								Total
		100 MG/ML		75 MG/ML		50 MG/ML		25 MG/ML		
		WM	WOM	WM	WOM	WM	WOM	WM	WOM	
A	Pathological Liver tissue	1	2	3	4	5	6	7	8	8
B	Pathological Liver tissue	1	2	3	4	5	6	7	8	8
C	Normal kidney Tissue	1	2	3	4	5	6	7	8	8
D	Pathological Kidney tissue	1	2	3	4	5	6	7	8	8

WM: With addition of mordant; WOM: Without the addition of mordant

Table 2. Staining results obtained with fresh extracts of *Hibiscus sabdariffa* as a primary stain.

Staining group	Staining result obtained
Aqueous <i>H. sabdariffa</i> extract without mordant	Very clear pink cytoplasm. All the distinctive morphological features of kidney and liver were seen. However, there were no nuclear staining.
Aqueous <i>H. sabdariffa</i> extract with alum (mordant) and ascertic acid	Improved cytoplasm stain. Distinctive morphological features seen. Also, there were no nuclear staining.
Ethanollic <i>H. sabdariffa</i> extract without mordant.	Pale pink cytoplasm. All the distinctive morphological features of kidney and liver were seen. Also, there were no nuclear staining.
Ethanollic <i>Hibiscus</i> extract with mordant	Improved cytoplasm stain. Distinctive morphological features seen. Also, there were no nuclear staining.
Aqueous <i>H. sabdariffa</i> extract with ammonia added	More improved cytoplasm staining. Distinctive morphological features seen. Also, there were no nuclear staining.
Ethanollic <i>H. sabdariffa</i> extract with ammonia added	More improved cytoplasm staining. Distinctive morphological features seen. Also, there were no nuclear staining.

Table 3. Staining results obtained with fresh extracts of *Lawsoniainermis* as a primary stain.

Staining Group	Staining Result Obtained
Aqueous <i>Lawsonia</i> extract without mordant	Pale pink cytoplasm. Distinctive morphological features of liver and kidney were seen. But no nuclear staining.
Aqueous <i>Lawsonia</i> extract with alum and acetic acid	Improved cytroplasm stain. Distinctive morphologic features seen. But no nuclear staining.
Ethanollic <i>Lawsonia</i> extract without mordant	Pale pink cytoplasm. Distinctive morphological features seen. But no nuclear staining.
Ethanollic <i>Lawsonia</i> extract with alum and acetic acid	Good cytoplasm stain. Distinctive morphological features seen. But no nuclei staining.
Aqueous <i>Lawsonia</i> extract with alum and Ammonia added	More improved cytoplasm staining. Distinctive morphological features seen. But no nuclei staining.
Ethanollic <i>Lawsonia</i> extract with Alum and Ammonia added	Excellent cytoplasm staining, distinctive morphological features seen. But no nuclei staining seen.

Table 4. Staining results obtained with fresh extracts of *Vitexdoniana* as a primary stain.

Solution	Result
Aqueous <i>Vitex</i> extract without mordant	No nuclear staining with well stained cytoplasm and clearly shown morphologic features.
Ethanollic <i>Vitex</i> extract without mordant.	No nuclear staining. Cytoplasm stains well showing morphologic features.
Aqueous <i>Vitex</i> extract with alum and acetic acid.	No nuclear staining. Cytoplasm is deeply stained showing morphologic features.
Ethanollic <i>Vitex</i> extract with alum and acetic acid.	No nuclear staining. Well stained cytoplasm with morphologic features seen.
Aqueous <i>Vitex</i> extract with alum and ammonia.	No nuclear staining. Well stained cytoplasm with morphologic features seen.
Ethanollic <i>Vitex</i> extract with alum and ammonia.	No nuclear staining. Cytoplasm staining reveals tissue morphology.

Table 5. Staining intensity and clarity of freshly prepared plant extracts alongside eosin.

Solution	Result
Ethanollic <i>Hibiscus</i> extract with mordant	Moderately stained, clear, no nuclear staining
Ethanollic <i>Hibiscus</i> extract without mordant	Moderately stained, clear, no nuclear staining
Aqueous <i>Hibiscus</i> extract with mordant	Moderately stained, clear, no nuclear staining
Aqueous <i>Hibiscus</i> extract without mordant	Moderately stained, clear, no nuclear staining
Ethanollic <i>Lawsonia</i> extract with mordant	Very lightly stained, lacks clarity, no nuclear staining
Ethanollic <i>Lawsonia</i> extract without mordant	Very lightly stained, lacks clarity, no nuclear staining
Aqueous <i>Lawsonia</i> extract with mordant	Very lightly stained, lacks clarity, no nuclear staining
Aqueous <i>Lawsonia</i> extract without mordant	Very lightly stained, lacks clarity, no nuclear staining
Ethanollic <i>Vitex</i> extract with mordant	Lightly stained, slightly clear, no nuclear staining
Ethanollic <i>Vitex</i> extract without mordant	Lightly stained, slightly clear, no nuclear staining
Aqueous <i>Vitex</i> extract with mordant	Lightly stained, slightly clear, no nuclear staining
Aqueous <i>Vitex</i> extract without mordant	Lightly stained, slightly clear, no nuclear staining

When each of the tissue slides was stained with only a single stain (mono staining) irrespective of the form and type of the plant extract, there was a drastic reduction in the intensities and clarity of features. All the various forms of all the plant products (*Hibiscussabdariffa*, *Lawsonia inermis* and *Vitex doniana*) produced very lightly stained slides without clarity and nuclear staining. After staining tissue slides with 6-month old plant extracts, reduction in the intensities and clarity of features were observed in those stained with *Hibiscus sabdariffa*, when compared with freshly prepared extracts alongside eosin.

Apart from ethanolic and aqueous extracts of *Hibiscus sabdariffa* with mordant which showed lightly stained and slightly clear tissue slides without nuclear staining, the rest of the extracts produced very lightly stained slides without clarity and nuclear staining (Tables 2-5).

The observations were conducted by 6 persons according to the method of Walker (2006) [14] and supervised by Prof. O.O. Okechi of Department of Medical Laboratory Science, Abia State University and Prof. O.G. Awuoro of Delta State University, Nigeria (Figures 2-10).

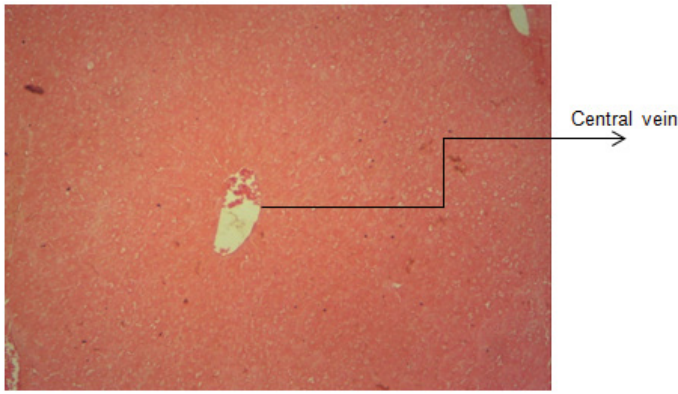


Figure 2. Plate 1. Normal liver tissue stained with fresh *Hibiscus* ethanolic extract as a primary stain (with ammonia added, x100) to show red cytoplasm, no nuclear staining.

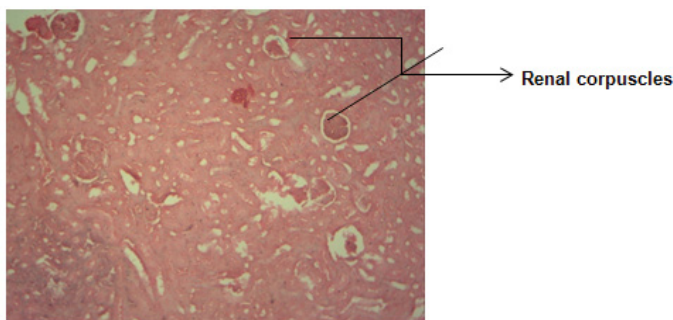


Figure 3. Plate 2. Normal kidney tissue stained with fresh *Hibiscus* aqueous extract as a primary stain (with ammonia added, x100) to show brown cytoplasm staining, no nuclear staining.

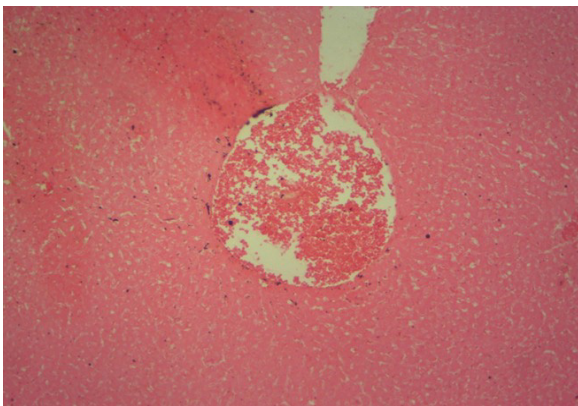


Figure 4. Plate 3. Normal liver tissue stained with fresh 100 mg/ml aqueous *Lawsoniainermis* extract as a primary stain (with mordant and ammonia, x100)

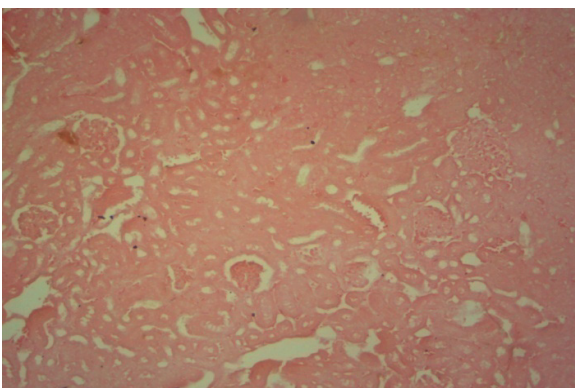


Figure 5. Plate 4. Normal kidney tissue stained with fresh 100mg/ml ethanolic *Lawsoniainermis* extract as a primary stain (with mordant and ammonia, x100)

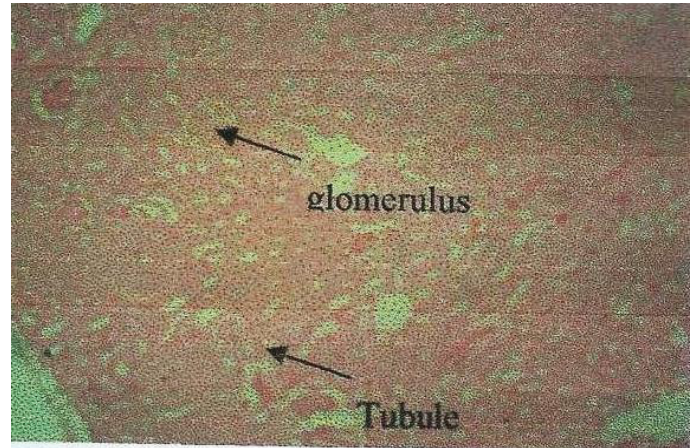


Figure 6. Plate 5. Normal kidney tissue stained with fresh ethanolic *Vitex* extract (without mordant) to show fairly stained cytoplasm but no nuclear staining. (x100)

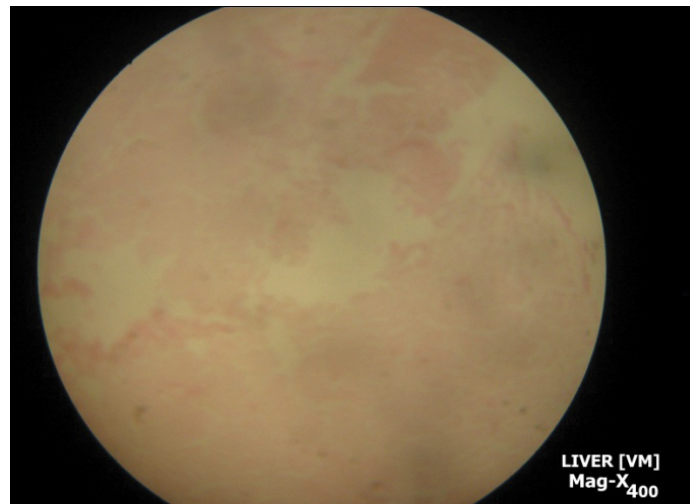


Figure 7. Plate 6. Pathological liver tissue slide stained with a 6-month old extract of non mordant *Vitexdoniana* extract as primary stain and eosin as secondary stain.

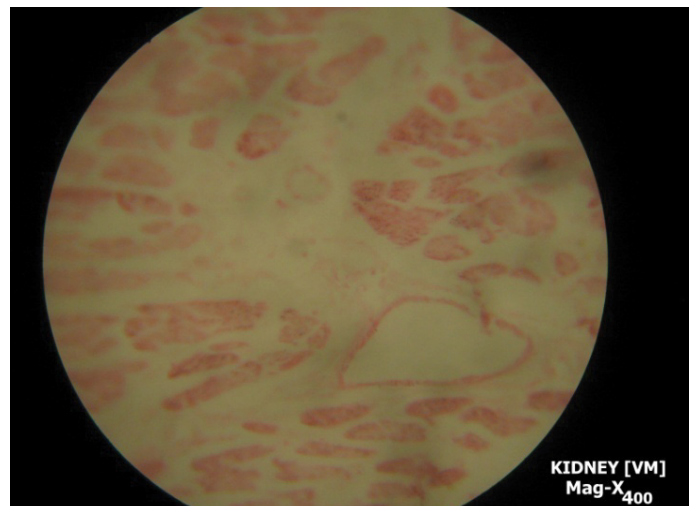


Figure 8. Plate 7. Pathological kidney slide stained with a 6-month old mordant *Vitexdoniana* extract.

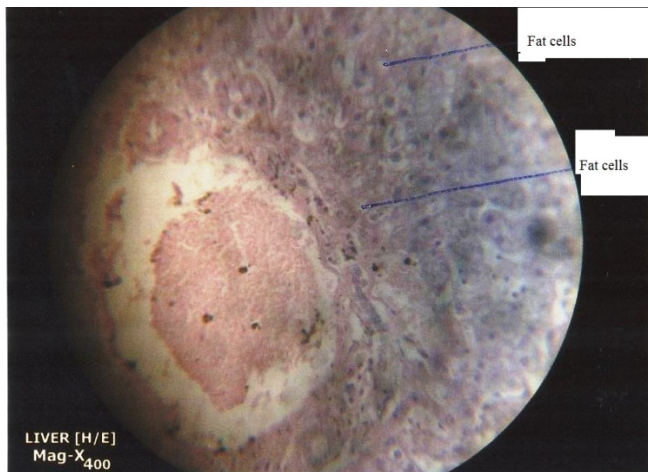


Figure 9. Plate 8. Pathological Liver tissue slide stained with haematoxylin and eosin stains to demonstrate fatty cell infiltration (fatty changes).

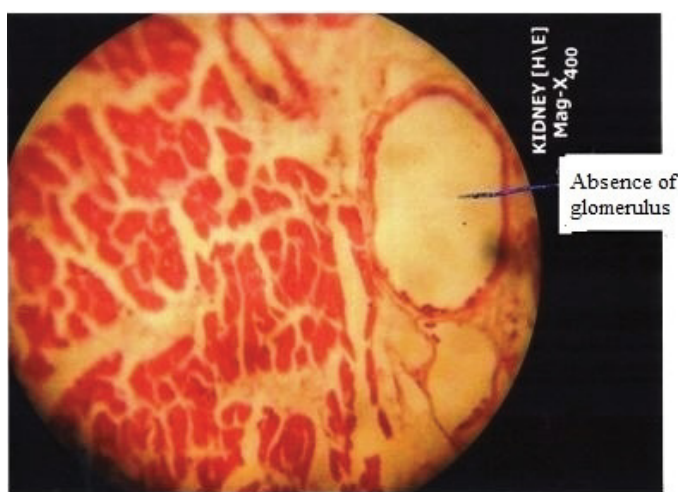


Figure 10. Plate 9. Pathological Kidney tissue slide stained with haematoxylin and eosin. Agglomerulus kidney discerned.

Discussion

In recent times, there has been an upsurge in demand for dyes obtained from natural sources. This is due to the toxic nature of the synthetic dyes coupled with the high cost of production and importation. Dyeing of tissues by stains (natural or synthetic) is dependent on binding or link to tissues without which they will simply be rinsed out of the tissue when the section is washed in another reagent. Ionic bonding, which involves electrostatic attraction between oppositely charged ions, is the most important form of bonding in histological staining. Cellular structures are selectively stained with various natural and synthetic dyes. Some of these tissue structures require combination of stains to demonstrate their presence. Acidity, alkalinity and mordant have been reported to affect some stains.

Hibiscus extract (100 mg/ml, aqueous and ethanolic) apparently acted as acidic stain in the study; hence it could not stain the nucleus which is an acidic structure. This observation is at variance with those of [7] who reported that *Hibiscus sabdariffa* calyx stained fungal mycelia red against light red background. Addition of mordant and acetic acid increased the acidity of the staining solution; this

probably increased the intensity and clarity of eosin (a counter stain) on the cytoplasm (a basic structure). Addition of acetic acid to the *Hibiscus* extract (with mordant) was aimed at making the solution more acidic. The increased acidity showed increased staining of the cytoplasm but no nuclear staining. This observation probably implied that *Hibiscus* extract is naturally an acid stain hence it could not stain the acidic nucleus. It has already been established that acidic tissue elements (e.g. nucleus) would have affinity for basic stains while cytoplasm, which is basic in nature, would have affinity for acid dyes [12,20]. Staining with *Hibiscus sabdariffa* was previously carried out but with varying results [4,6]. Haematoxylin in combination with eosin (a synthetic dye) is used for the demonstration of general tissue structures such as muscle fibre, connective tissues etc in histology. Nuclei of cells take up the haematoxylin stain and appear dark violet/blue in color. Cytoplasm or red blood cells take up eosin and appear pink. In the present study, the tissues, which were stained with H & E, stain showed good nuclear and cytoplasm differentiation as the nucleus stains dark violet/blue and the cytoplasm pink/red. There was no obscurity to the nucleus caused by addition of the counter-stain and the tissue morphology was clearly shown.

Lawsonia inermis extract (aqueous and ethanolic, used as a primary stain) probably served as either acidic or basic stain depending on the pH of the solution as it has been reported that when cytoplasm or nuclear structures are of interest, an appropriate pH that would favour the uptake of the stain would have to be selected. Originally (after extraction), it had an acidic pH. Addition of mordant and acetic acid further decreased the pH of the staining solution (making it more acidic) hence it could not stain the nucleus. This suggests that although mordanting does enhance nuclear-mordant dye affinity, *Lawsonia* is naturally an acidic stain and as such could not stain the acidic nuclear component of the tissue but stained only cellular cytoplasm. Addition of ammonia (pH 11.6) to the extracted mordant solution was done to increase the pH to the alkaline side of neutrality. The alkalized solution showed improved staining of the acidic nucleus in line with the established fact that basic stains stain the acidic constituent of the cell such as nucleus [23].

Vitexdoniana extract (100 mg/ml and used as primary stain) showed no nuclear affinity. When the extract, which was mixed with potassium alum as a mordant and alkalized with ammonia, was applied on the liver and kidney tissue sections and counterstained with eosin, the nuclear/cytoplasm differentiation was poor and the eosin counter stain seemed to stain all the structures uniformly resulting in the so-called "pink disease". Alum mordant was added to the solution to increase the nuclear affinity to the dye as it has been reported that the use of a mordant could enhance the nuclear-mordant-dye affinity [24,25], but there was no observed nuclear uptake of the dye; the nucleus remain unstained. This may indicate that *Vitexdoniana* extract cannot act as an alternative or supplementary stain to haematoxylin irrespective of the presence of a mordant and basic status. 6 month old extracts gave significantly reduced staining intensities and clarity of normal and pathological liver and kidney features when compared with freshly prepared extracts. This observation may be explained on the basis of deterioration of the plant products after 6 months of extraction.

Conclusion and Recommendations

In conclusion, whereas ethanolic or aqueous, mordant or non mordant extracts of freshly prepared *Hibiscus sabdariffa* and *Lawsonia inermis* extracts may possess slight staining potentials, they cannot act as alternative to haematoxylin since when they replaced haematoxylin in some aspects of the present study; absence of nuclear staining and distinction, reduced intensities and clarity of normal and pathological features of kidney and liver were observed.

Lawsonia inermis, a naturally occurring acid stain could not stain the nucleus when used as a primary stain until it was alkalinized by the addition of ammonia after which it showed improved staining of acidic nuclear components of the tissues in line with the established fact that basic stains stain the acidic constituent of the cell such as nucleus.

Aqueous and ethanolic extracts of *Vitex doniana* as a primary stain showed no affinity to nucleus even when rendered basic with ammonia and used with alum as mordant. This suggests that *Vitex doniana* may not have possessed qualities of good histological stains. Further studies should be done to show how the cytoplasm and nuclear staining characteristics of the plant products could be enhanced. Such studies include optimum staining pH, optimum staining temperature and spectrophotometric analysis. Staining characteristics of the extracts on other types of tissues such as connective tissue components should be investigated.

References

- Ahmed Amel and Bushra Abakar. "Evaluation of Thyroid Abnormalities using Ultrasonography and Radionuclide Scintigraphy." PhD diss., Sudan University of Science and Technology (2018).
- Duke, James A. "Ecosystematic data on economic plants." *Int J Crude Drug Res* 17 (1979): 91-109.
- Watt, JM and Breyer B. "The medicinal and poisonous plants of southern and eastern Africa" (2nd ed). Edinburg, London (1962).
- Rao, P Udayasekhara. "Nutrient composition and biological evaluation of mesta (*Hibiscus sabdariffa*) seeds." *Plant Foods Hum Nutr* 49(1996): 27-34.
- Egbujo EC, Adisa OJ and Yahaya AB. "A Study of the Staining Effect of Roselle (*Hibiscus sabdariffa*) on the Histologic Section of the Testis." (2008).
- Ihuma JO, Asenge GH, Abioye JOK, and Dick SK. "Application of methanolic extracts from *Hibiscus sabdariffa* Linn as a biological staining agent for some fungal species." *IJPAES* 2(2012): 254-259.
- Hashim Eman A. "The Use of Watery Extract of Kujarat Flowers *Hibiscus Sabdariffa* as a Natural Histological Stain." *IqNJM* 5 (2006).
- Abubakar S, Usman AB, Etim V and O. Nnadi, et al. "Application of organic dyes from roselle calyx (*Hibiscus sabdariffa* Linn) for mycological staining." *Indian J Innovations Dev* 1 (2012): 687-690.
- Elmanama Abdelraouf A, Amany A Alyazji and Abu-Gheneima NA. "Antibacterial, antifungal and synergistic effect of *Lawsonia inermis*, *Punicagranatum* and *Hibiscus sabdariffa*." *Ann Intern Med* 7(2011).
- Awet G and Tapapillekoyiet S. "Lawsonia inermis L". National museums of Kenya, Naerobi, Kenya, (2005): 722.
- Semwal Ruchi Badoni, Deepak Kumar Semwal, Sandra Combrinck and Catherine Cartwright-Jones, et al. "Lawsonia inermis L.(henna): Ethnobotanical, phytochemical and pharmacological aspects." *J Ethnopharmacol* 155 (2014): 80-103.
- Awioro OG, Aloamaka PC, Ojiana NU and Oduola T. "Extracts of *Pterocarpus* as a histological stain for collagen fibres." *Afr J Biotechnol* 4(2005): 460-462.
- Aguoru CU, Okpe FO, and Olasan JO. "Comparative staining efficacy of safranin and *Lawsonia inermis* L. aqueous ethanolic leaf extract on epidermal cells of *Allium cepa* L." *Int J Curr Res Biosci Plant Biol* 2(2015): 108-111.
- Orwa C, Mutua A, Kindt R and Jamnadass R, et al. "Agroforestry Database: a tree reference and selection guide. Version 4." *Agroforestry Database: a tree reference and selection guide. Version 4.* (2009).
- Walter F, PhD. Boron. "Medical Physiology: A Cellular And Molecular Approach". Elsevier/Saunders (2004):201 .
- Walter F, PhD and Boron. "Medical Physiology: A Cellular And Molecular Approach." Elsevier/Saunders (2004): 201.
- Jin Chao, Fei Shi, Dehui Xiang, and Bin Zhang et al. "3D fast automatic segmentation of kidney based on modified AAM and random forest." *IEEE Transactions on Medical Imaging* 35(2016): 1395-1407.
- Cotran Ramzi S, and Vinay Kumar. "Nelson Fausto; Robbins, Stanley L.; Abbas, Abul K.(2005). Robbins and Cotran pathologic basis of disease . St. Louis, MO: Elsevier Saunders." ISBN. 0-7216-0187-1: 878.
- Vize Peter D, Adrian S Woolf, and Jonathan BL Bard, eds. "The kidney: from normal development to congenital disease." Elsevier (2003).
- Baker FJ, and Silverton RE. "The theory of staining.Introduction to medical laboratory technology." (1976): 385-391.
- Braide W, Akobundu C, Nwaoguikpe RN, and Njiribaeko LC. "The use of extracts from four local Nigerian plants for the staining of selected bacteria and moulds." *Afr J Microbiol Res* 5 (2010): 79-86.
- Chukwu OOC, Odu CE, Chukwu DI and Hafiz N, et al. "Application of extracts of Henna (*Lawsonia inermis*) leaves as a counter stain." (2011).
- Gulrajini ML, Gupta D, Ray Maukik S. (1999): Studies on dyeing with Natural dyes: part 1-Dyeing of annatto on nylon and polyester. *Indian J Fibre Textile Res* 24(2) 131-135.
- Hafiz H, Chukwu OOC, and Nura S. "The potentials of henna (*Lawsonia inermis* L.) leaves extracts as counter stain in gram staining reaction." *BAJOPAS* 5 (2012): 56-60.
- Marshall PN, and Horobin RW. "Measurements of the affinities of basic and "mordant" dyes for various tissue substrates." *Histochemie* 36 (1973): 303-312.

How to cite this article: Nnaemeka Okolie, Ngokere AA and Enweani IB. "Staining Potentials of Indigenous *Hibiscus sabdariffa* Calyx, *Lawsonia inermis* Leaves and *Vitex Doniana* Stem Barks on Liver and Kidney Tissues." *J Cytol Histol* 12 (2021): 563.