

# Ruptured Hematosalpinx: An Unconventional Cause of Hemoperitoneum in Early Pregnancy

Carrington Kambasha\*, Neelam Prasad, Pradumna Jamjute and Haissam Moukarram

Consultant in Obstetrics and Gynaecology at North Cumbria University Hospitals NHS Trust, UK

## Abstract

Hemoperitoneum with an adnexal mass in reproductive age group women points to a life-threatening differential diagnosis of a ruptured ectopic pregnancy. Rarely isolated tubal pathology such as tubal torsion with hematosalpinx may mimic such a picture and the diagnosis is difficult in hemodynamically compromised patients. This is a case report of isolated hematosalpinx without torsion in early pregnancy which was histologically confirmed following surgical management.

**Keywords:** Hematosalpinx • Hemoperitoneum • Early pregnancy

## Introduction

Acute abdomen in reproductive age females is a common gynaecological clinical presentation in the emergency setting. Differential diagnosis in this group of patients includes gynaecological causes such as an ectopic pregnancy, ovarian torsion, miscarriage, ovarian cyst accidents and pelvic inflammatory disease. Non-gynaecological causes include acute appendicitis, nephrolithiasis and urinary tract infections. Isolated tubal pathology leading to hematosalpinx without congenital anatomical deformity is rare. We present a case of a 28-year-old primigravida with isolated hematosalpinx masquerading an ectopic pregnancy. Hematosalpinx without torsion in pregnancy is an enigma, whilst rare, will be useful differential in day to day clinical scenario.

## Case Report

A 28-year-old primigravida woman with a positive pregnancy test presented to the Accident and Emergency Department with an 8 day history of lower abdominal pain and self-reported passage of suspected products of conception 4 days prior. Patient denied vaginal bleeding. On examination, patient was apyrexial and tachycardiac with abdominal examination revealing right iliac fossa tenderness with guarding and rigidity. An emergency transvaginal ultrasonography demonstrated an empty uterine cavity with free fluid in pouch of Douglas and around both adnexa. A 30 × 17 mm adnexal mass was seen with mixed echoes giving an impression of ruptured ectopic pregnancy (Figure 1). Her bloods were unremarkable with a serum beta HcG of 211. As patient was clinically unstable, an emergency diagnostic laparoscopy was performed.

Intra-operative findings included a 10 × 20 mm right tubal ampullary mass with associated active bleeding and 400 ml of hemoperitoneum. The left fallopian tube, both ovaries and uterus were normal. Right salpingectomy was performed with resolution of the active bleeding. Day 2 post-operatively complained of worsening lower abdominal pain and vaginal bleeding. CT abdomen/pelvis with contrast performed showed post-operative changes with no radiological evidence of bleeding. Patient had an uneventful recovery following a brief inpatient stay. Repeat serum HcG was <1 IU/L at the patient's

**\*Address for Correspondence:** Kambasha C, Department of Obstetrics and Gynecology, Glan Clwyd Hospital, North Wales NHS Trust, Rhyl, North Wales, UK, E-mail: Carrington.kambasha@doctors.org.uk

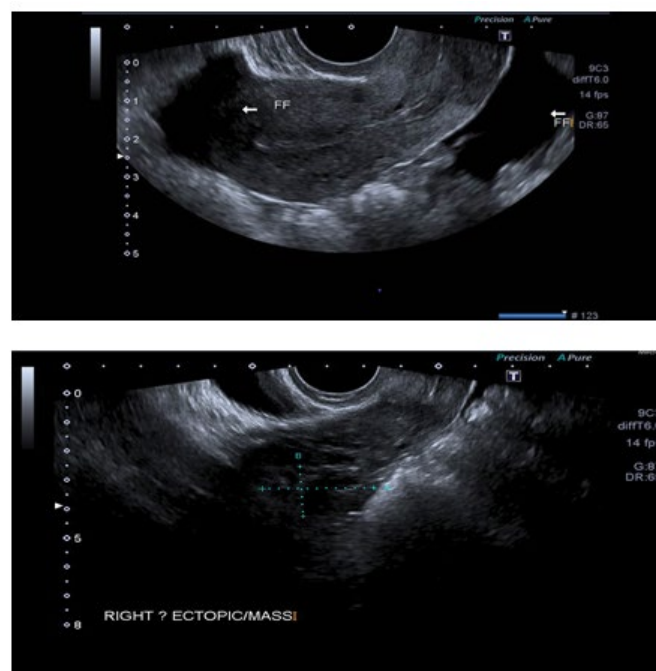
**Copyright:** © 2021 Kambasha C, et al. This is an open-access article distributed under the terms of the Creative Commons Attribution License, which permits unrestricted use, distribution, and reproduction in any medium, provided the original author and source are credited.

Received 17 May 2021; Accepted 31 May 2021; Published 07 June 2021

3-week follow-up. She subsequently had a successful uncomplicated pregnancy a year later. Histological report revealed complete transverse section of the fallopian with normal histological features. The lumen was filled with blood with no evidence of products of conception, inflammation, endometriosis or malignancy. The final histological diagnosis was that of a hematosalpinx.

## Discussion

Isolated hematosalpinx in pregnancy is a rare diagnosis and it is an enigma. It poses diagnostic and management dilemma, however the importance of reporting such a clinical case report lies in the fact that it presents similarly to an ectopic pregnancy. To date, hematosalpinx with torsion is well documented; however there is paucity of its existence with no associated torsion. Incidence of isolated fallopian tube torsion is estimated at 1 per 1.5 million women [1]. Recent literature review shows evidence of 19 cases of isolated fallopian tube torsion in pregnancy treated surgically from 1936 to 2009 [2]. Up until now, we report the first case of isolated hematosalpinx with no torsion. The



**Figure 1.** A 30 × 17 mm adnexal mass was seen with mixed echoes giving an impression of ruptured ectopic pregnancy.

aetiology of isolated tubal haemorrhage remains elusive, that the risk factors may be within the tubes like anatomically longer or spirally twisted tubes or acquired predisposing conditions like, infection, hydrosalpinx, neoplasms. Motility abnormalities like deranged ciliary motion or abnormal peristalsis may be an underlying cause which may be present during pregnancy. Sometimes adhesions with neighbouring organs like uterus and ovarian may pose some risk to tubal haemorrhage. Endometriosis may be an underlying cause but, in this case, there was no surgical or histopathological evidence of endometriosis [2-4].

Similar clinical features are common with other more common medical conditions and give the physician a tough list of differentials, which includes ectopic pregnancy, ovarian cyst accidents (like haemorrhage, torsion, rupture) acute pelvic inflammatory disease, tubo-ovarian abscess, degenerating fibroids, among gynaecological causes besides surgical causes like acute appendicitis, urolithiasis, intestinal obstruction or perforation. Laboratory values are nonspecific and help in the differential diagnosis. However imaging parameter help us make pre-operative diagnosis. The ultrasound is handy tool in such situation and helps us make a plan of management especially in unstable patients. In haemodynamically stable patients doppler ultrasound and MRI may have some diagnostic relevance. However final diagnosis is only possible after histological examination. The management however remains the same, salpingectomy if the other tube is healthy. In all cases reported earlier surgical management is done and in the current era minimal invasive surgery is preferred mode of surgery even in pregnancy [5].

---

## Conclusion

Hemoperitoneum is a life-threatening condition in pregnancy. Hematosalpinx clinically mimics ruptured ectopic pregnancy. All adnexal masses in pregnancy are not ectopic pregnancy and isolated tubal disease must be a differential in all cases of acute hemoperitoneum in reproductive age group females.

---

## References

1. Ole Hart, Hansen. "Isolated Torsion of the Fallopian Tube." *Acta Obstet Gynecol Scand* 49 (1970): 3-6.
2. Massimo Origoni, Paolo Cavoretto, Enrico Conti and Augusto Ferrari. "Isolated Tubal Torsion in Pregnancy." *Eur J Obstet Gynecol Reprad Biol* 146 (2009): 116-120.
3. Krissi, Haim. "Fallopian Tube Torsion: Laparoscopic Evaluation and Treatment of a Rare Gynecological Entity." *J Am Board Fam Pract* 14 (2001): 274-277.
4. Antoniou, Nain. "Isolated Torsion of the Fallopian Tube: A Case Report and Review of the Literature." *Clin Exp Obstet Gynecol* 31 (2004): 235-238.
5. Sidiropoulou, Zacharoula. "Acute Abdomen in Pregnancy due to Isolated Fallopian Tube Torsion: The Laparoscopic Treatment of a Rare Case." *World J Clin Case* 2 (2014): 724-727.

**How to cite this article:** Carrington Kambasha\*, Neelam Prasad, Pradumna Jamjute and Haissam Moukarram. "Ruptured Hematosalpinx: An Unconventional Cause of Hemoperitoneum in Early Pregnancy." *Clin Case Rep* 11 (2021): 1446.