

Rare Case of Mobius Syndrome: A Case Report

Gregory Ngo* and Roy Chowdhury

Department of Pediatrics, Delaware County Memorial Hospital, Drexel Hill, United States

Abstract

Moebius syndrome is a rare birth defect that mainly affects the muscles that control facial expression and eye movement. It is caused by the absence or underdevelopment of the sixth and seventh cranial nerves, which control eye movements and facial expression. Moebius syndrome can affect the cranial nerves that control the muscles of the tongue, jaw, larynx, and throat, as well as those that create speech.

Keywords: Moebius syndrome • Cleft palate • Cranial nerves • Eye movement

Introduction

As a result, children with moebius syndrome may have difficulty with articulation and resonance. Severe forms of moebius syndrome may also necessitate the use of a special bottle or feeding tube to provide sufficient nourishment [1]. Feeding issues, on the other hand, tend to improve with age as youngsters learn correct motor control. Physical and speech therapy can assist youngsters in gaining more control over their speaking and eating, as well as improving overall coordination and motor abilities.

- Moebius syndrome symptoms
- People with moebius syndrome experience
- Weakness or complete paralysis of the facial muscles
- Trouble swallowing or sucking
- Difficulties with speech and frequent drooling
- Inability to form facial expressions, including smiling, frowning, raising eyebrows, puckering lips or closing eyes
- Cleft palate
- Dental problems
- Hand and foot problems including club foot and missing or fused fingers (syndactyly)
- Hearing problems
- High palate
- Irritated and dry eyes
- Motor delays
- Poland's syndrome (chest wall and upper limb anomalies)
- Strabismus (crossed eyes)

The condition is distinguished by neurological impairments palsies of numerous cranial nerves of the brain stem of varying and

degree at the same time. The primary nerves involved are the sixth (CN VI) and seventh (CN VII), resulting in aberrant staring and mask-like facies. Babies with this condition are frequently described as being unable to smile or suck [2]. This can lead to bonding issues for the mother, and such parents should seek the advice of behavioural specialists.

Other neurons linked to the condition include the fifth (CN V), eighth (CN VIII), tenth (CN X), and twelfth (CN XII). When limb anomalies are present, the disorder is referred to as Poland-Moebius. Due to neurological abnormalities, reduced blinking rate and eye.

The aetiology is unknown, however transient vascular anomalies during early intrauterine life are thought to be involved in the pathophysiology. Because of their vaso-active properties, drugs such as cocaine misuse during pregnancy and the early abortion agent misoprostol (common in Latin America) have been linked to an increased prevalence of the condition [3]. Finally, the known teratogen thalidomide was previously implicated. Although no common gene has been implicated, a number of autosomal dominant and X-linked genes have been discovered.

Case Presentation

An 8-month-3-week-old, ex 37.6-week dichorionic diamniotic twin female, was referred by ent to our hospital for an in-office feeding evaluation for mobius syndrome. Prenatal history was significant for polyhydramnios, intrauterine growth restriction and ASD/PFO. Postnatal history was significant for dysmorphic facies including a shortened upper lip frenulum, micrognathia, asymmetric facies, and poor feeding [4]. She received occupational therapy, physical therapy and speech therapy through early intervention due to delayed motor skills and inability to sit unsupported.

*Address for Correspondence: Gregory Ngo, Department of Pediatrics, Drexel Hill, United States; E-mail: ngogreg1@gmail.com

Copyright: © 2023 Ngo G, et al. This is an open-access article distributed under the terms of the creative commons attribution license which permits unrestricted use, distribution and reproduction in any medium, provided the original author and source are credited.

Received: 21 August, 2019, Manuscript No. JPNM-23-103328; **Editor assigned:** 26 August, 2019, Pre QC No. P-103328; **Reviewed:** 09 September, 2019, QC No. Q-103328; **Revised:** 14 June, 2023, Manuscript No. R-103328; **Published:** 12 July, 2023, DOI: 10.37421/2472-100X.2023.8.232

She received bilateral myringotomy and pressure equalization tube placement for middle ear and Eustachian tube dysfunction.

Impairments in facial function related with FP may include issues eliciting appropriate facial expressions of emotion, whether genetic, congenital or acquired. Throughout the lifespan, the typical facial expression of emotion carries significant emotional information and is therefore essential for successful social interactions. Additionally, the formation of strong attachment bonds and efficient communication depend on facial imitation and good responses to baby facial emotional signals. Others may interpret problems with facial display of emotion as boredom, a lack of confidence or indifference. There may thus be less fruitful or successful social contacts as a result of this incorrect assessment of the emotional state.

The stigma faced by children and young people with visible differences in facial appearance has been well documented and the discrimination that goes along with it may have negative effects on quality of life, self-esteem and body image. This is in addition to the communication difficulties linked to impaired facial expression. A focus group of teenagers with moebius syndrome, for instance, experienced problems with social engagement, prejudice, poor confidence and bullying. An emotional condition can therefore lead to less beneficial or successful social contacts. The Poland-Moebius syndrome is a combination of these features with congenital lack of the pectoral muscles and ipsilateral hand abnormalities. Although the cause of the neurologic abnormalities in moebius syndrome is unknown, it does not appear plausible that a single pathogenetic pathway is responsible.

The pathogenesis and etiology of the Moebius sequence appeared to be multifactorial. It is postulated to be due to vascular disruption in the brain during prenatal development leading to hypoplasia or agenesis of the cranial nerve nuclei during fetal development. Sporadic mutations in *PLXND1* and *REV3L* genes have also been identified in a number of patients and confirmed to cause a constellation of findings consistent with Moebius syndrome when introduced in animal models. In rare cases, familial patterns have been reported. Most likely, Moebius syndrome is multifactorial, which means that both genetic and environmental factors play some causative role.

Due to the rarity of the disorder, it can be challenging to understand the signs and symptoms of Moebius syndrome. When patients with Moebius syndrome are not well-known to others, the lack of facial expression can be annoying or seen as indifferent, bored, or melancholy. Drooling and dysarthric speech are two additional moebius syndrome characteristics that may increase the likelihood of social rejection, result in stigmatisation, or be mistaken for an intellectual handicap. Verbal and nonverbal behaviour can make up for a lack of facial expression, although laboured and less automatic expressive behaviour might impede the flow of natural conversation (Figures 1-5).

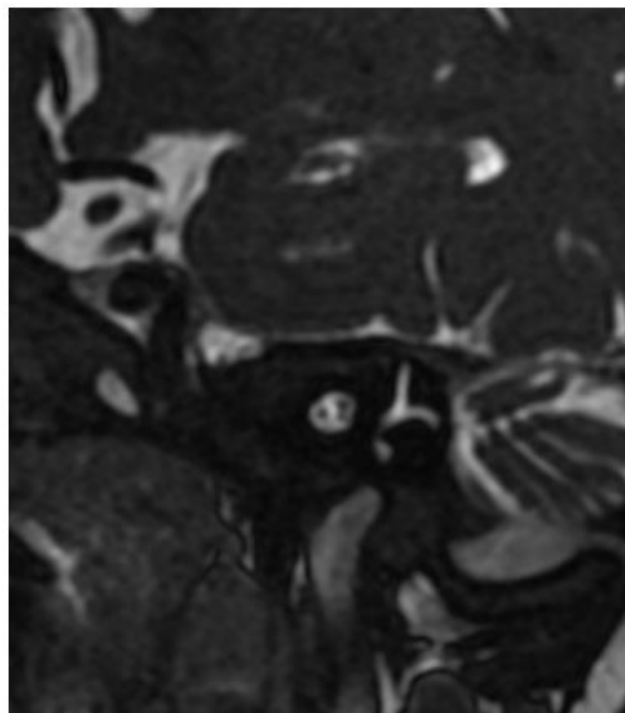


Figure 1. Left 3D-FIESTA perpendicular to the long axis of the IAC demonstrates absent CN7.

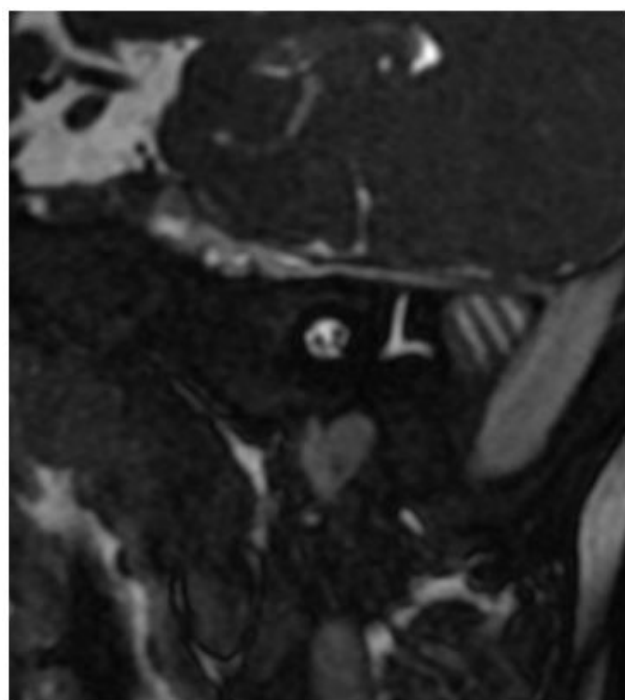


Figure 2. Left 3D-FIESTA perpendicular to the long axis of the IAC demonstrates absent CN7.



Figure 3. 3D-FIESTA perpendicular to the long axis of the IAC demonstrates normal anatomy with the CN7 at the top left anterior position, cochlear nerve at the bottom left anterior position, the superior vestibular nerve at the top right posterior position, and the inferior vestibular nerve at the bottom right posterior position.

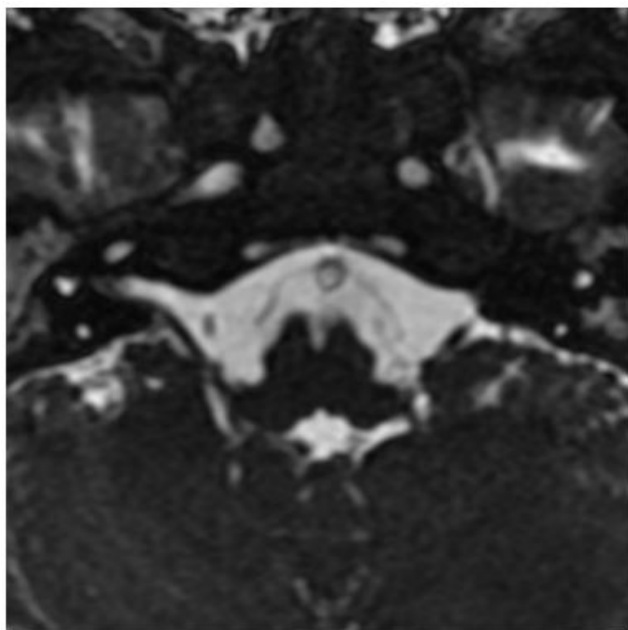


Figure 4. Axial 3D-FIESTA demonstrates the normal CN8 bilaterally with absent CN7.

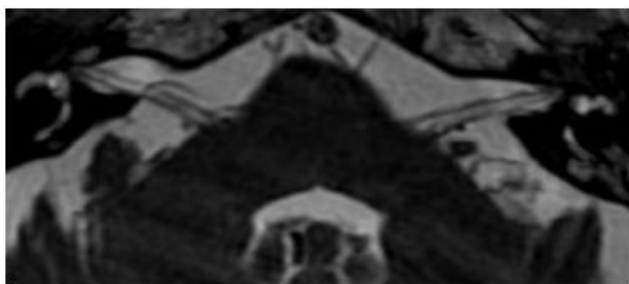


Figure 5. Axial 3D-FIESTA demonstrates the bilateral normal anatomy with CN8 posteriorly and CN7 anteriorly.

Results and Discussion

Moebius syndrome (Congenital facial diplegia) is an exceedingly rare neurological disorder characterized by hypoplasia or aplasia of the facial nerve (CN7) and abducens nerve (CN6) nuclei [5-7]. Clinical manifestation consists of bilateral palsy of the facial nerve (Cranial nerve 7, often concurrent with palsy of other closely associated cranial nerves). The disease is non-progressive. The inheritance pattern and etiology of this disorder is under investigation, but has been hypothesized to involve cranial nerve nuclei dysgenesis, brain stem dysgenesis, disruption of neurovascular structures and/or trauma during birth. The most supported etiology is fetal transient ischemic or hypoxic insult. It is associated with Poland syndrome. While the exact incidence of Moebius syndrome within the United States is unknown, it is estimated to affect 1 in every 50,000 live newborns, with equal frequency among males and females.

Timely diagnosis of Moebius syndrome is extraordinarily challenging for the healthcare provider, as clinical presentation widely varies depending on individual nerve(s) involved and severity of palsy. As complete or partial facial nerve palsy is essential for diagnosis, incomplete closure of eyelids, drooling, and lack of facial expression in the newborn are some of the first most commonly observed symptoms of the disorder [8-10]. Involvement of the cranial nerve(s) of the eye results in concurrent gaze palsy, with the abducens nerve being the most commonly involved, causing adduction of the eye(s). While less frequently observed, palsy of the vestibulocochlear nerve may result in hearing deficit and vertigo, while hypoglossal nerve involvement presents as hypoplasia of the tongue and speech abnormalities. A wide spectrum of craniofacial structural abnormalities, limb malformations, and cognitive developmental disability may also be noted.

Conclusion

In addition to absent facial and abducens nerves, reported MRI findings include pontine and medullary hypoplasia with straightening of the floor of the fourth ventricle as a result of absence of the facial colliculus, cerebellar hypoplasia, calcification of the pons and absence of the middle cerebellar peduncles. Treatment for facial paresis involves reconstructive plastic surgery with muscle transplantation. Moebius syndrome is a rare case of aplastic or hypoplastic CN7 and CN6. It is important to identify the presence of these nerves on 3D-FIESTA in a patient with facial or abducens nerve palsy.

References

1. Kumar, Dhavendra. "Moebius Syndrome." *J Med Genet* 27 (1990): 122.
2. Sudarshan, Alexander and William D Goldie. "The Spectrum of Congenital Facial Diplegia (Moebius Syndrome)." *Pediatr Neurol* 1 (1985): 180-184.
3. Lammens, M., Ph Moerman, Jean-Pierre Fryns, J M Schroder and D Spinnewyn, et al. "Neuropathological Findings in Moebius Syndrome." *Clin Genet* 54 (1998): 136-141.

4. Stabile, M, M L Cavaliere, G Scarano and A Fels, et al. "Abnormal BAEP in a Family with Moebius Syndrome: Evidence for Supranuclear Lesion." *Clin Genet* 25 (1984): 459-463.
5. Verzijl, Harriette TFM, Bert van der Zwaag, Johannes RM Cruysberg and George W Padberg. "Mobius Syndrome Redefined: A Syndrome of Rhombencephalic Maldevelopment." *Neurol* 61 (2003): 327-333.
6. Meyerson, Marion D, and David R Foushee. "Speech, Language and Hearing in Moebius Syndrome: A Study of 22 Patients." *Dev Med Child Neurol* 20 (1978): 357-365.
7. Gillberg, Ch and I Winnergard. "Childhood Psychosis in a Case of Moebius Syndrome." *Neuropediatrics* 15 (1984): 147-149.
8. Pitner, Samuel E, James E Edwards and William F McCormick. "Observations on the Pathology of the Moebius Syndrome." *J Neurol Neurosurg Psychiatr* 28 (1965): 362.
9. Ferguson, Scott. "Moebius Syndrome: A Review of the Anaesthetic Implications." *Pediatr Anesth* 6 (1996): 51-56.
10. Legum, Cyril, Victor Godel and Pinhas Nemet. "Heterogeneity and Pleiotropism in the Moebius Syndrome." *Clin Genet* 20 (1981): 254-259.

How to cite this article: Ngo, Gregory and Roy Chowdhury. "Rare Case of Mobius Syndrome: A Case Report." *J Pediatr Neurol Med* 8 (2023): 232.