

# Radiosurgery with CyberKnife in Primary Orbital MALT Lymphoma: A Case Report

Vasko Graklanov<sup>1,3</sup>, Popov Veselin<sup>2,3</sup> and Grudeva-Popova Janet<sup>2,3</sup>

<sup>1</sup>First Department of Internal Diseases, Medical University, Plovdiv, Bulgaria

<sup>2</sup>Department of Clinical Oncology, Medical University, Plovdiv, Bulgaria

<sup>3</sup>First Department of Internal Diseases, UMHAT, "SV. Georgi", Plovdiv, Bulgaria

## Abstract

MALT lymphoma constitutes one half of all orbital malignancies. Ocular adnexal lymphoma of MALT-type (OAML) may affect critical structures in the orbit and can become therapeutic challenge. Surgery, radiotherapy or chemotherapy, alone or in combined modalities can be used as treatment options based on the individual patient variables as well as the site, stage and surgical accessibility of the OAML. This case confirms that radiosurgery with CyberKnife is an effective and safe therapeutic option in patients with OAML reducing the collateral damage to a minimal rate.

**Keywords:** CyberKnife • Radiosurgery • Mucosa-associated lymphoid tissue lymphoma • Ocular adnexal lymphoma of MALT-type

## Introduction

The concept of Mucosa-Associated Lymphoid Tissue (MALT) lymphoma first described by Isaacson et al. is now recognized as distinct clinical-pathological and molecular entity [1]. According World Health Organization (WHO) classifications, Marginal Zone Lymphoma (MZL) consists of three subtypes: Splenic MZL; Nodal MZL; and Extra-nodal MZL, also called MALT lymphoma [2]. MALT lymphoma accounts for 5-8% of all B-cell lymphomas [3] and constitutes one half of all orbital malignancies [4]. Ocular Adnexal Lymphoma of MALT-type (OAML) can affect conjunctiva, the retrobulbar soft tissue, the lacrimal gland, the eyelid and the lacrimal sac [5]. Although radiation therapy is the primary modality of treatment many issues remain unresolved due to the various types of ocular involvement, radiation techniques and side effects.

## Case Presentation

A 76-year-old Caucasian female patient presented with pain in the right eye. Two years before the patient had the same symptoms. The computed tomography at that time detected lesion in the right retrobulbar space. Excisional biopsy was performed and the pathological report was consistent with lipoma. At present the physical exam showed exophthalmos of the right eye. No enlarged lymph nodes and no significant findings on systemic examination were found. Routine blood investigations were within normal limits. Computed tomography of the head revealed a lesion in the right retrobulbar space. Excisional biopsy was performed and the immunophenotyping of the material showed phenotype CD20+, BCL2+, BCL6-, CD5-, CD3-, CD10-, cyclin D1-, and ki-67 proliferation index of 15%. In context with the microscopic appearance the final pathology report revealed the diagnosis of extranodal Marginal Zone Lymphoma (MZL/MALT). Further staging with chest, abdominal and pelvic computed tomography and bone marrow biopsy were done. No enlarged lymph nodes and no bone marrow involvement were found, which was consistent with a clinical stage IE. After discussion of her medical case, a multidisciplinary team decision was to start treatment with 4 cycles of high dose

Dexamethasone plus anti-chlamidial antibiotic therapy. From January 2019 till April 2019 the patient was treated with 4 cycles of high dose Dexamethasone. The control CT of the head showed stable disease.

## Radiosurgery with CyberKnife

The multidisciplinary team decision was radiosurgery with CyberKnife as a second line therapy because this therapy option has the capacity to minimize irradiation of nearby critical structures. Before starting the treatment an orbital Magnetic Resonance Imaging (MRI) of the right retrobulbar mass was performed (Figure 1). Patient head was immobilized with a thermoplastic mask before CT/MRI imaging fusion. The nearby critical structures (eyes, lens, lacrimal glands, optic nerves and optic chiasm) were contoured. The dose was prescribed such that 96.8% of the PTV received 100% of the prescribed dose of 20 Gy. The prescribed dose was delivered in 4 fractions, 5 Gy daily. The radiation used for radiosurgery was 6 MeV photons. There was no significant acute toxicity registered. The months after the radiosurgery with CyberKnife no exophthalmos was detected, and the control CT showed very good response to the treatment (Figure 2).

## Results and Discussion

Even though the Ocular Adnexal Lymphoma of MALT-type (OAML) is the most common type of eye lymphoma with approximately 45-75% of all cases, [6-8] patients with OAML have a better prognosis than those with other types of eye lymphomas due to its indolent course. Recently an association between Chlamydia psittaci chronic infection and OAML lymphomas was established. Also further evidences suggested that a complete or partial regression can be achieved in some cases of ocular adnexal MALT lymphoma using anti-chlamidial antibiotic therapy [9,10]. To date no specific guidelines for the management of OAML lymphomas has been published. Based on the

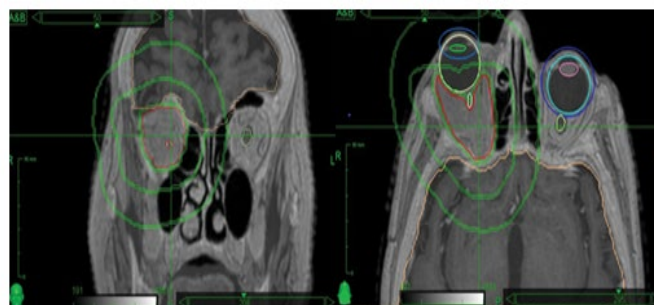


Figure 1. Images of pre-treatment CT/MRI.

**\*Address for Correspondence:** Graklanov V, First Department of Internal Diseases, Medical University-Plovdiv, Bulgaria, E-mail: dr.graklanov@yahoo.com

**Copyright:** © 2021 Graklanov V, et al. This is an open-access article distributed under the terms of the Creative Commons Attribution License, which permits unrestricted use, distribution, and reproduction in any medium, provided the original author and source are credited.

Received 02 June 2021; Accepted 15 June 2021; Published 22 June 2021

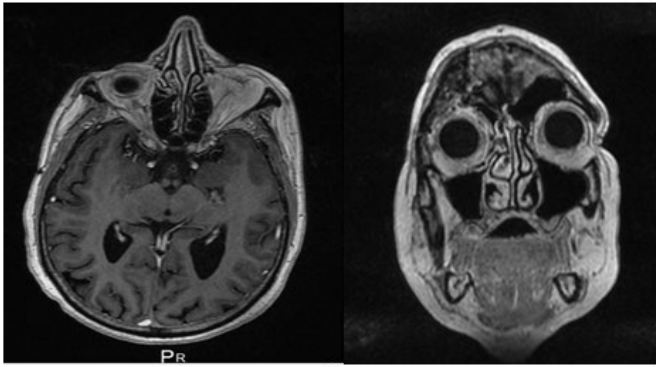


Figure 2. Images of post-treatment CT.

individual patient variables as well as the site, stage and surgical accessibility of the OAML three types of treatment options: surgery, radiotherapy or chemotherapy, alone or in combined modalities has been investigated.

Surgery as the only treatment modality is only appropriate for stage one pseudo-encapsulated conjunctival and lachrymal gland MALT lymphomas and generally is not an option due the difficulty of complete resection and high relapse rates [11,12]. Due to the excellent local control rates after local radiotherapy there are insufficient published data regarding the use of chemotherapy in patients with OAML. Although a few studies have shown the efficacy of the combination chemotherapy, most often, chemotherapy is administered after either surgery or radiotherapy failure or in patients with advanced stages [13]. Conventional Radiation therapy has proven to be effective for the treatment of ocular MALT lymphoma in many publications [14-16]. Different radiotherapy modalities such as External-Beam Radiotherapy (EBRT), brachytherapy or robotic fractionated-radiosurgery (CyberKnife) can be applied [17]. Reducing the collateral damage to a minimal rate radiosurgery with CyberKnife is an effective and safe therapeutic option in patients with OAML.

## Conclusion

As the rates the Ocular Adnexal MALT Lymphoma (OAML) are increasing nowadays a new effective and save therapeutic options are more than needed. Conventional local radiation therapy is the preferred therapeutic option with proven efficacy in the treatment of OAML. According to previous published data and the result of our case, treatment using radiosurgery with CyberKnife is an effective therapeutic modality with an acceptable toxicity profile.

## References

1. Peter Isaacson and Dennis H. Wright. "Malignant Lymphoma of Mucosa-Associated Lymphoid Tissue: A Distinctive Type of B-Cell Lymphoma." *Cancer* 52 (1983): 1410-1416.
2. Jaffe, Elaine. "The 2008 WHO Classification of Lymphomas: Implications for Clinical Practice and Translational Research." *Hematol Am Soc Hematol Educ Prog* 10 (2009): 523-531.
3. Ian W. Flinn and Jesus G. Berdeja. "Blood and Bone Marrow Transplantation for Patients with Hodgkin's and Non-Hodgkin's Lymphoma." *Blood* 89 (1997): 3909-3918.
4. Curtis E. Margo and Zuber D. Mulla. "Malignant Tumors of the Orbit: Analysis of the Florida Cancer Registry." *Ophthalmol* 19 (1998): 835-846.
5. Keisuke Sasai and Hirohiko Yamabe. "Non-Hodgkin's Lymphoma of the Ocular Adnexa." *Acta Oncol* 40 (2001): 485-490.
6. Nancy L Harris and Judith A Ferry. "Ocular Adnexal Lymphoma: Clinical Behavior of Distinct World Health Organization Classification Subtypes." *Int J Radiat Oncol Biol Phys* 57 (2003): 1382-1391.
7. Gerardo F. Graue, Paul T. Finger, Elizabeth Maher and David Della Rocca, et al. "Ocular Adnexal Lymphoma Staging and Treatment: American Joint Committee on Cancer versus Ann Arbor." *Eur J Ophthalmol* 23 (2013): 344-355.
8. Jenkins, Chunghyun. "Histological Features of Ocular Adnexal Lymphoma (REAL Classification) and their Association with Patient Morbidity and Survival." *Br J Ophthalmol* 84 (2000): 907-913.
9. Andres J. Ferreri, Maurizio Ponzoni, Massimo Guidoboni and Antonia A. Lettini, et al. "Evidence for an Association between Chlamydia Psittaci and Ocular Adnexal Lymphoma." *J Natl Cancer Inst* 96 (2004): 586-594.
10. Dandan Zhang, Lina Dong, Haiyan Li and Hasi Jin, et al. "Ocular Adnexal Mucosa-Associated Lymphoid Tissue Lymphoma in Northern China: High Frequency of Numerical Chromosomal Changes and No Evidence of an Association with Chlamydia Psittaci." *Leuk Lymphoma* 51 (2010): 2031-2038.
11. Andrés J. M. Ferreri, Riccardo Dolcetti, Silvia Govi and Maurizio Ponzoni. "Ocular Adnexal MALT Lymphoma: An Intriguing Model for Antigen-Driven Lymphomagenesis and Microbial-Targeted Therapy." *Ann Oncol* 19 (2007): 835-846.
12. Olga, Ésik. "A Retrospective Analysis of Different Modalities for Treatment of Primary Orbital Non-Hodgkin's Lymphomas." *Radiother Oncol* 38 (1996): 13.
13. Piero, Galieni. "Localized Orbital Lymphoma." *Haematol* 82 (1997): 436-439.
14. Melanie C. Smitt and Sarah S. Donaldson. "Radiotherapy is Successful Treatment for Orbital Lymphoma." *Int J Radiat Oncol Biol Phys* 26 (1993): 59-66.
15. Masatoshi Hasegawa, Masaru Kojima, Mariko Shioya and Yoshio Tamaki, et al. "Treatment Results of Radiotherapy for Malignant Lymphoma of the Orbit and Histopathologic Review According to the WHO Classification." *Int J Radiat Oncol Biol Phys* 57 (2003): 172-176.
16. Jayant S. Goda, Mary Gospodarowicz, Melania Pintilie and Woodrow Wells, et al. "Long-Term Outcome in Localized Extranodal Mucosaassociated Lymphoid Tissue Lymphomas Treated with Radiotherapy." *Cancer* 116 (2010): 3815.
17. Maria Antonietta Blasi, Alessandra C. Tiberti, Paola Valente and Michela Laguardia, et al. "Intralesional Interferon-Alpha for Conjunctival Mucosa-Associated Lymphoid Tissue Lymphoma: Long-Term Results." *Ophthalmol* 119 (2012): 494-450.

**How to cite this article:** Vasko Graklanov, Popov Veselin, Grudeva-Popova Janet. "Radiosurgery with CyberKnife in Primary Orbital MALT Lymphoma: A Case Report." *Clin Case Rep* 11 (2021): 1448.