

Prone Positioning for Posterior Fossa Tumors Resection: New Experience in Iraq

Haitham H Shareef*

Division of Neurosurgery, Al-Hussein Teaching Hospital, Nasiriyah, Iraq

Abstract

Background: Brain tumors are the second most common malignancy in children. About one third occurred in toddlers under the age of 3, and about two-thirds are located in the posterior fossa. Lesions in the posterior cranial fossa are difficult problems to the neurosurgeon and the anesthetist. Surgical damage to vital medullary centers and air embolism are the main dangers.

Aim: The neurosurgical default work and training in Iraq is directed toward the sitting position to resect posterior fossa tumor using the classical Sugita skull fixation system. In this paper we will clarify the use of prone position instead of sitting position to treat such cases.

Material and Methods: A prospective study was done on five cases of pediatric posterior fossa tumors operated on at Al Hussein Teaching Hospital of Nasiriyah using the prone position with the aid of the Mayfield skull fixation system instead of Sugita.

Results: One case diagnosed as medulloblastoma, one case diagnosed as a dermoid cyst, and three cases diagnosed as cerebellar astrocytoma with minimum operative and post-operative complications. One case developed postoperative cerebellar mutism, one case developed concealed CSF leak which resolved spontaneously.

Keywords: Brain tumor • Medulloblastoma • Cerebellar mutism • Pediatric

Introduction

Brain tumors are the second most common malignancy in children. About one third occurred in toddlers under the age of 3, and about two-thirds are located in the posterior fossa. Lesions in the posterior cranial fossa are difficult problems to the neurosurgeon and the anesthetist [1]. Surgical damage to vital medullary centers and air embolism are the main dangers.

Cerebellar Astrocytoma

- 2nd most common posterior fossa tumor in children
- Most malignant
- Considered a PNET (primitive neuroectodermal tumor)
- Typically arises from the granular layer of the inferior medullary velum of the vermis
- Poorly defined mass filling the 4th ventricle arises from the roof of it
- High density on CT scan
- On MRI, tend to be more homogenous in signal than cerebellar astrocytoma and ependymoma
- On T2, tend to be more hypointense to mildly hyperintense
- Poorly defined border between the mass and the vermis
- Propensity for seeding within the intracranial and intraspinal CSF spaces
- Unlike other posterior fossa tumors, medulloblastomas are

*Address for Correspondence: Haitham H Shareef, Division of Neurosurgery, Al-Hussein Teaching Hospital, Nasiriyah, Iraq, Tel: +964781560315; E-mail: haithamalgyzy2004@hotmail.com.

Copyright: © 2020 Shareef HH. This is an open-access article distributed under the terms of the Creative Commons Attribution License, which permits unrestricted use, distribution, and reproduction in any medium, provided the original author and source are credited.

Received 20 May, 2020; Accepted 25 May, 2020; Published 01 June, 2020

hypercellular and as a result, show restricted diffusion on DWI sequences

Brainstem Glioma

- Most commonly astrocytomas of moderate aggressiveness; most commonly in the pons
- Unlike other PFT, the lesion tends to present with cranial nerve abnormalities, pyramidal tract signs or cerebellar dysfunction
- May cause circumferential enlargement of the brainstem or grow in the exophytic fashion
- MRI tends to demonstrate a homogenous high signal on T2 weighted images
- Nonenhancing
- 4th ventricle pushed posteriorly
- Hydrocephalus uncommon

Ependymoma

- Relatively slow-growing, typically benign tumors that arise from the ciliated ependymal cells that line the ventricles
- 2/3 occur in the 4th ventricle
- When they do occur in the 4th ventricle, they arise from and have a broad connection with the floor of the 4th ventricle, opposite to the roof involvement seen in medulloblastoma. Therefore, the border between the lesion and the floor of the 4th ventricle is often poorly defined.
- May fill and grow out of the 4th ventricle via the foramina into the cisterna magna and spinal canal
- The lesion appears very heterogeneous and enhances heterogeneously on CT and MRI
- Well defined, lobulated margins

- Calcifications are seen on CT in 70% of cases

Aim

The neurosurgical default work and training in Iraq is directed toward the sitting position to resect posterior fossa tumor using the classical Sugita skull fixation system [1]. In this paper we will clarify the use of prone position instead of sitting position to treat such cases.

Material and Method

A prospective study done on five cases of pediatric posterior fossa tumors operated on at Al Hussein Teaching Hospital of Nasiriyah using the prone position with the aid of the Mayfield skull fixation system instead of Sugita. Preoperative preparation was one for all cases and those patients were thoroughly investigated by head CT scan, brain MRI, and all routine investigations required for preoperative checking [2]. Three cases presented with obstructive hydrocephalus (those diagnosed later as cerebellar astrocytoma) therefore Ventriculo-peritoneal shunt was performed for the two weeks prior to the scheduled suboccipitalcraniectomy. Two cases (those diagnosed later as medulloblastoma and dermoid cyst) did not need V-P shunt because there was no evidence of obstructive hydrocephalus. All five operated on using prone position with the skull fixated by Mayfield three pin-holder [3]. Suboccipitalcraniectomy was the procedure of choice to resect posterior fossa tumors either median or paramedian approach. Total resection was done in the case of medulloblastoma and dermoid cyst while near-total or subtotal resection done for the cases of cerebellar astrocytomas. Postoperative radiotherapy was done for all patients except that with a dermoid cyst and provided that patient age is more than four years to minimize the post-radiation complications. Follow up period is from 6 months to 2 years with regular Head CT scan and Brain MRI to exclude tumor recurrence. The mean age of the patients was five years, two females and three males, all of them were from ThiQar governorate [4] (Figure 1).

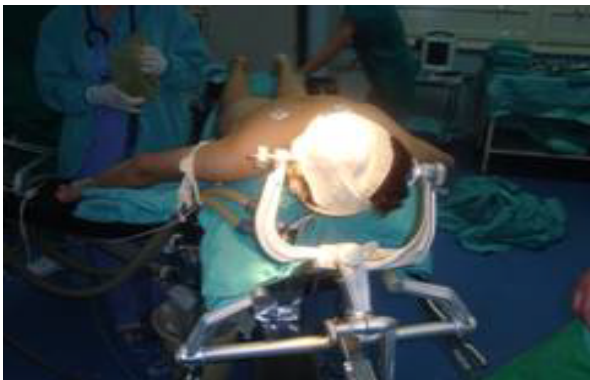


Figure 1. Use of prone position instead of sitting position to treat neurosurgical cases.

Result

All five cases were operated on by prone position using the Mayfield 3-pin holder.

Intraoperative course

Venous Air Embolism (VAE) was not encountered in all cases during the Intraoperative periods, severe bleeding was encountered in one case only diagnosed later as medulloblastoma and control of bleeding was done. Lesser hand fatigue and tremor was experienced with the prone position in comparison to that of sitting position [4].

Postoperative course

Only one case developed the syndrome of cerebellar mutism which

was treated conservatively and resolved spontaneously, also one case developed postoperative concealed CSF leak (pseudomeningocele) treated conservatively and resolved spontaneously. Pneumocephalus has occurred in all cases and needs no surgical intervention [5].

Histopathological examinations revealed three cases of cerebellar astrocytoma, one case of medulloblastoma, and one case of dermoid cyst. Pediatric posterior fossa tumors can be resected by prone position using Mayfield 3-pin holder with uneventful Intraoperative course and good post-operative results [6].

Discussion

General intraoperative considerations

Positioning: In general, a prone position with chest and hip rolls placed to avoid abdominal compression. Pin fixation is typically used to maintain head position. Caution should be taken when placing pins in young children or in patients with long-standing hydrocephalus who may have a thin cranium. Younger children and infants may be positioned in a padded horseshoe with caution taken to avoid pressure on the face or eyes.

While head flexion is helpful for surgical exposure, breath sounds and airway pressures should be checked carefully after positioning to ensure that the endotracheal tube has not been kinked [7].

Blood loss: Can be rapid and life-threatening. Extreme caution must be taken when opening the dura in the posterior fossa, particularly in young children who may have enlarged dural venous sinuses. Tumor bleeding during resection can also be extensive, particularly for malignant tumors such as medulloblastoma. All patients should have an arterial line and appropriate venous access. In the event of extensive blood loss, coagulopathy and thrombocytopenia should be ruled out and aggressively corrected if diagnosed [8].

Neurophysiological monitoring: Is controversial. Most useful in patients with lateral tumors involving the cerebellopontine angle or focal tumors intrinsic to the brainstem.

Prolonged postoperative intubation: may be considered for patients who require long operations, receive multiple units of blood, or who have extensive manipulation of cranial nerves and may not be able to protect their airways [9].

Midline suboccipital craniectomy: the common surgical procedure performed for children with infratentorial tumors. The basic surgical steps for a midline suboccipital craniectomy for tumor resection are outlined below:

- Midline incision from the external occipital protuberance to below the spinous process of C2
- Dissection through ligamentum nuchae, a relatively avascular tissue between the suboccipital muscles, and placement of self-retaining retractors to move muscles laterally
- Separation of muscle from the occipital bone, posterior arch of C1, and superior half of the posterior arch of C2. In infants, dissection over C1 should be especially cautious, as the posterior arch may not be fully ossified
- Wide craniectomy from just below the estimated location of the transverse sinus to the opisthion
- Removal of the posterior arch of C1 should be considered, especially for large tumors with significant inferior extension
- Dural opening, typically in a Y-shaped fashion, with caution regarding the presence of enlarged occipital and circular venous sinuses

- Drainage of CSF from the cistern magna and introduction of magnifying loupes
- Identification of normal vascular structures (vertebral artery and PICA) and cranial nerves bilaterally
- Gentle elevation of the cerebellar tonsils to identify the floor of the fourth ventricle, and placement of a cottonoid paddy if possible to protect the brainstem and spinal cord
- Intraventricular tumors that extend far superiorly may require resection of the inferior portion of the cerebellar vermis to avoid extensive cerebellar retraction
- Tumors that extend to the lateral cisterns may be reached using the cerebellomedullary fissure (telovelar) approach without vermian resection [10]

Tumors are typically resected using a combination of bipolar coagulation with suction. Orientation regarding the floor of the fourth ventricle is always maintained to avoid injury to the brainstem. Small amounts of tumor clearly attached to or invading the brainstem, or firmly attached to cranial nerves, are not resected [4].

Conclusion

It is the time to convert the routine neurosurgical attitude in Iraq from using sitting position into the prone position also to change the classical Sugita skull holder into Mayfield holder. Mayfield 3-pin holder gives a satisfactory skull fixation in addition to its compatibility with brain retractors such as Fukushima and Leila retractors.

Another comparative study should be conducted to see the differences in results and outcomes between sitting position and prone position for resection of pediatric posterior fossa tumors and analyzing data from both neurosurgical and anesthetic point of view.

Conflict of Interest

The authors declared no conflicts of interest with respect to the authorship and/or publication of this article.

References

1. JB, Allibone, Harkness WJ, and Hayward RD. "Craniotomy-related complications in a pediatric neurosurgery unit- A prospective study." *Br J Neurosurg* 13 (1999): 148-153.
2. LE, Becker, and Halliday WC. "Central nervous system tumors of childhood." *Perspect Pediatr Pathol* 10 (1987): 86-134.
3. PC, Bucy. "Exposure of the posterior or cerebellar fossa." *J Neurosurg* 24 (1966): 820-832.
4. R, Hayward. "Posterior fossa craniotomy: An alternative to craniectomy." *Pediatr Neurosurg* 31 (1999): 330.
5. Greenberg, Mark. "Greenberg: Handbook of Neurosurgery, Eighth Edition." (2016): 1-1784.
6. S, Setti. "Rengachary: Principles of Neurosurgery, Second Edition." (2005)
7. DJ, Culley, Berger MS, Shaw D, and Geyer R. "An analysis of factors determining the need for ventriculoperitoneal shunts after posterior fossa tumor surgery in children." *Neurosurgery* 34 (1994): 402-408.
8. KM, David, Casey ATH, Hayward RD, and Harkness WF, et al. "Medulloblastoma: Is the 5-year survival rate improving? A review of 80 cases from a single institution." *J Neurosurg* 86 (1997): 13-21.
9. JR, Farwell, Dohrmann GJ, and Flannery JT. "Central nervous system tumors in children." *Cancer* 40 (1977): 3123-3132.
10. SG, Harner, Beatty CW, and Bersold EMJ. "Impact of cranioplasty on headache after acoustic neuroma removal." *Neurosurgery* 36 (1995): 1097-1100.8.

How to cite this article: Haitham H Shareef. "Prone Positioning for Posterior Fossa Tumors Resection: New Experience in Iraq." *J Clin Neurol Neurosurg* 3 (2020): 108. doi: 10.37421/JCNN.2020.3.108