

Papilledema and Diplopia Due to Meningioma Inside the Superior Sagittal Sinus: Case Report and Review of the Literature

Marta Rico Pereira* and Carlos Asencio Cortés

Department of Neurosurgery, Hospital Santa Creu i Sant Pau, Barcelona, Spain

Abstract

Small lesions invading or compressing dural sinuses are frequent but secondary intracranial hypertension is not very common, with few examples reported in the literature. This event may be explained in the setting of anatomic variants in pattern of venous sinus circulation. We present the case of a patient who presented with papilledema and loss of visual acuity due to a small meningioma located inside the superior sagittal sinus (SSS). The patient underwent a lumboperitoneal shunt placement with recovery of symptoms. Literature available is also reviewed.

Keywords: Meningioma • Superior sagittal sinus • Intracranial hypertension • Papilledema • Lumbo-peritoneal shunt

Introduction

Intracranial hypertension due to small lesions compressing or invading venous sinuses is not a common event, despite the high frequency of meningiomas affecting dural sinuses. They may become symptomatic when there are anatomical variants or significant dominance on one side [1].

Meningiomas located inside venous sinuses are not common; treatment is more challenging in this case and venous sinus opening may lead to significant neurological complications.

We report the case of a patient who presented with papilledema and diplopia due to a small meningioma located in the posterior third of the superior sagittal sinus, treated with a lumbo-peritoneal shunt placement with recovery of symptoms. The role of variants in venous sinus circulation are discussed, as well as treatment modalities [2].

Case Report

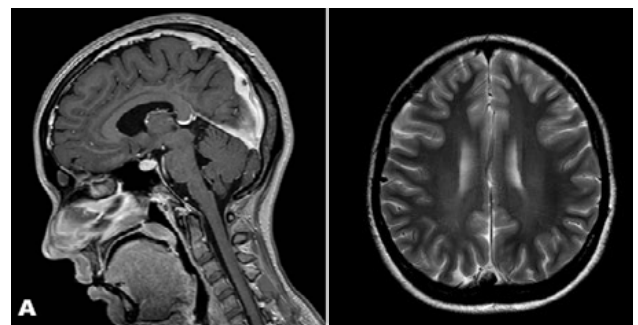
A 22-year-old female patient, otherwise healthy, presented with severe headache, visual impairment and vomiting, in addition to diplopia due to paresis of the sixth cranial nerve, all suggestive of intracranial hypertension. A brain CT scan was performed with no apparent intracranial lesions. Ophthalmological examination revealed the presence of papilledema [3].

Given the clinical suspicion of intracranial hypertension, a lumbar puncture was performed with pressure measurement, resulting in 37 mmHg and 30 ml of cerebrospinal fluid were evacuated. After that, the patient presented significant transient clinical improvement.

Magnetic Resonance revealed a small lesion in relation to the posterior third of the superior sagittal sinus, with a size of 12 x 10 x 10 mm, hyperintense in T2 and FLAIR sequences and hypointense in T1. The lesion showed homogeneous enhancement after Gadolinium administration, suggestive of meningioma. Superior sagittal sinus invasion and stenosis by the meningioma

was observed. On the other hand, no optic nerve sheath or Meckel cavum anomalies were observed, all suggestive of idiopathic or benign intracranial hypertension (Figure 1 a and b) [4].

Given the findings in the MRI, a selective arteriography of both internal carotids and left vertebral arteries was performed (Figure 2). Arterial phase did not show intracranial hypervascularization or other relevant findings. Venous phase confirmed moderate and segmental stenosis of the posterior third of the superior sagittal sinus due to the meningioma, as well as slowed global intracranial cerebral venous circulation time, especially in relation to the



Figures 1A and 1B: Brain MRI in T1 sequence after administration of Gadolinium in sagittal and axial sections, showing a lesion in relation to the posterior third of the superior sagittal sinus, with homogeneous enhancement after Gadolinium administration, suggestive of meningioma.

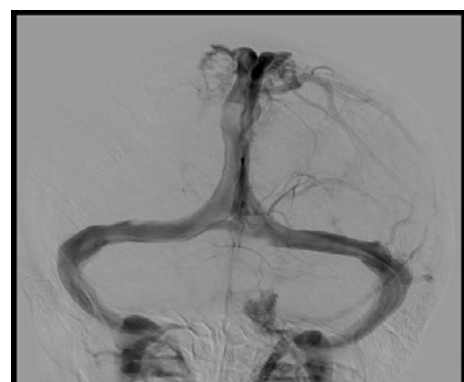
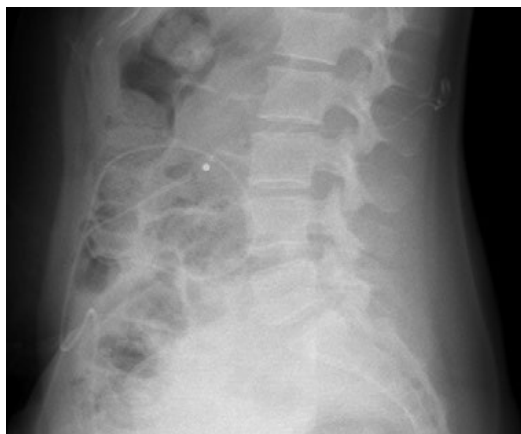
Figure 2: Cerebral angiography of both carotid arteries and left vertebral artery in venous phase and sagittal projection, showing moderate and segmental stenosis of the distal third of the superior sagittal sinus due to the meningioma.

***Address for Correspondence:** Marta Rico Pereira, Department of Neurosurgery, Hospital Santa Creu i Sant Pau, Barcelona, Spain; E-mail: mricop@santpau.cat

Copyright: © 2021 Pereira M R, et al. This is an open-access article distributed under the terms of the Creative Commons Attribution License, which permits unrestricted use, distribution, and reproduction in any medium, provided the original author and source are credited.

Received 02 February, 2021 **Accepted** 16 February, 2021 **Published** 23 February 2021



Figures 3A and 3B: Simple abdominal radiography in anteroposterior and lateral projections after placement of lumbo-peritoneal.

cortical veins draining to the superior sagittal sinus [5].

On the other hand, an anatomical variant was observed: the right Labbé vein was hypoplastic, with compensatory hypertrophy of Trolard vein. This finding explained the intensity clinic presented by the patient.

Results

After evacuation of CSF through lumbar punctures, the patient experienced significant clinical improvement. Therefore, she was proposed to undergo surgical intervention by placing a lumbo-peritoneal shunt with programmable valves, Strata Medtronic Iberica SA (E45750), with correct postoperative evolution (Figure 3 a and b) [6]. Intracranial hypertension symptoms remitted. Subsequent ophthalmologic examination showed marked improvement of papilledema and the patient reported subjective visual improvement.

MRI after one month was performed showing stability of the lesion. Available therapeutic options to address meningioma were evaluated, including surgical resection, endovascular techniques through stent placement 4, 6, 8 and radiosurgery 3, 7, the latter being considered the best in this case, given its characteristics (size and risk associated with both resection and stent placement at this location) [7].

Currently, the patient does not present symptoms of intracranial hypertension, she occasionally suffers from paresthesias in lower extremities suggesting seizures and she is under antiepileptic treatment.

The last MRI showed stability of the meningioma with re-expansion of the superior sagittal sinus comparing with the MRI before lumbo-peritoneal shunt placement. At the present time the patient has not received treatment by radiosurgery given the stability and correct evolution she presents [8].

Discussion

Intracranial hypertension secondary to lesions invading or compressing venous sinuses is well known. Different lesions may produce this complication (metastatic tumors, epidermoid cyst, meningioma) and they become symptomatic more frequently if anatomic variants in the pattern of venous circulation are present.

Meningiomas represent the most frequent intracranial tumor. Location

inside dural venous sinuses is not very common. In this situation, the possible occurrence of intracranial hypertension due to small lesions may lead to ophthalmologic symptoms. On the other hand, this location makes tumor resection more challenging with greater associated risks.

The pattern of venous sinus circulation may be very variable and this may explain the exceptional occurrence of intracranial hypertension despite the high frequency of invasion or compression of dural sinuses by different lesions.

In our case, the right Labbé vein was hypoplastic, with compensatory hypertrophy of Trolard vein, explaining the symptoms with the partial stenosis of the superior sagittal sinus.

In our case, given the patient's symptoms we decided to place a lumbo-peritoneal shunt with programmable valves. However, given the location in the posterior third of the superior sagittal sinus, it was decided not to proceed to the definitive treatment, taking into account the patient clinical stability as well as stability of the meningioma in the imaging controls.

Conclusion

Intracranial hypertension secondary to a meningioma located in the superior sagittal sinus is an uncommon entity. In its management, CSF shunts should be considered for symptomatic management. The definitive treatment of the lesion may be managed by surgical techniques, endovascular techniques or radiosurgery, depending on the location and size. In case of stable and small lesions in an asymptomatic patient, conservative management is a good option.

References

- Kreßner, Maika, Arit Felix, Riepl Wolf and Meixensberger Jurgen. "Prognostic Factors of Microsurgical Treatment of Intracranial Meningiomas-A Multivariate Analysis." *PLoS One* 13 (2018): e0202520.
- Sindou Marc P, Alvernia Joreg E. "Results of Attempted Radical Tumor Removal and Venous Repair in 100 Consecutive Meningiomas Involving the Major Dural Sinuses." *J Neurosurg* 105 (2006): 514-525.
- Vachhrajani, Shobhan, Andrew Jea, John Rutka and Susan Blaser. Meningioma with dural venous sinus invasion and jugular vein extension. *J Neurosurgery Pediatrics* 2 (2008): 391-396.
- Han, Moon Soo, Kim Yeong Jin, Moon Kyung Sub and Lee Kyung Hwa. "Lessons from Surgical Outcome for Intracranial Meningioma Involving Major Venous Sinus." *Medicine (Baltimore)* 95(2016): e4705.
- Ding, Dale, Xu Zhiyuan, McNeill Ian T and Yen Chun Po. "Radiosurgery for Parasagittal and Parafalcine Meningiomas." *J Neurosurgery* 119 (2013): 871-877.
- Mariniello, Geeny, Giamundo Alio, Donzelli Robert and Severino Russo. Intracranial Hypertension due to Meningioma of the Unique Transverse Sinus. *Neuroradiol J* 26 (2013): 209-212.
- Kondziolka, Douglas, Mathieu David, Lunsford L Dade and Juan J. Martin. "Radiosurgery as Definitive Management of Intracranial Meningiomas." *Neurosurgery* 62 (2008): 53-58.
- Donnet Aguilar, Metellus Paul and Levrier Owlal. "Endovascular Treatment of Idiopathic Intracranial Hypertension: Clinical and Radiologic Outcome of 10 Consecutive Patients." *Neurology* 70 (2008): 641-647.

How to cite this article: Pereira, Marta Rico and Carlos AsencioCortés. "Papilledema and Diplopia Due to Meningioma Inside Superior Sagittal Sinus. Case Report and Review of the Literature." *Clin Case Rep* 11 (2021): 1419