

## Management of Multiple Gingival Recession Defects in Aesthetic Zone with VISTA Technique: A Case Report

Saket K\*, Rekha SM and Sushama RG

Department of Periodontics, Vokkaligara Sangha Dental College and Hospital, Bengaluru, Karnataka, India

### Abstract

Gingival recession is a common condition which involves apical migration of the gingival margin leading to exposure of the root surfaces. The condition has a multifactorial etiology and is commonly associated with trauma caused by inappropriate brushing technique and damage caused by periodontal disease. If not managed, the exposed root surface can become prone to development of root caries, hypersensitivity and can also compromise the patient aesthetically when the defect sites are present in the aesthetic zone. This report describes a case of multiple gingival recessions treated with minimally invasive VISTA (Vestibular Incision Subperiosteal Tunnel) technique in the aesthetic zone.

**Keywords:** Periodontal disease; Gingival recess; Root caries; Tooth; VISTA

### Introduction

Gingival recession is a condition which involves destruction of both soft and hard tissues around the tooth and eventually leads to an apically positioned gingival margin. The exposed root surfaces are more prone to root caries, hypersensitivity and also a source of esthetic concern which may compromise the patient's quality of life. To manage gingival recession, researchers have devised an array of surgical techniques and biomaterials. However, most of the devised techniques involve sulcular incision or vertical release incision which can lead to unfavourable healing outcomes. VISTA (Vestibular Incision Subperiosteal Tunnel Approach) is a new technique which uses an approach from the vestibule to treat multiple gingival recessions. Due to the vestibular approach, the technique overcomes the disadvantages inherent in other root coverage procedures such as sulcular incisions and vertical releasing incisions which can cause unfavourable healing [1,2].

Till date, autogenous soft tissue graft has been considered as the gold standard for the management of gingival recession cases. However, autogenous grafting has its limitations as it creates a second surgical site which may be an unpleasant experience to the patient. Also, especially in cases of multiple gingival recession involving two or more teeth, the quantity of graft available is limited & such cases cannot be attempted in a single sitting [3]. In order to minimize these disadvantages, biodegradable biologically active substances such as acellular dermal matrix allograft (ADM), enamel matrix derivate (EMD), platelet-rich plasma (PRP), platelet-rich fibrin (PRF) and more have been developed [4,5]. The platelet-rich fibrin (PRF) was first introduced for the first time by Choukroun et al. in 2001 and is regarded as a second-generation platelet concentrate. This autogenous biomaterial slowly releases growth factor which lasts for at least 7-28 days. The growth factor promotes the healing of the tissue and to some extent have also found to aid in regeneration [6].

This case report evaluates the clinical outcomes of the treatment of multiple adjacent gingival recessions with VISTA technique in combination with PRF membrane.

### Case Presentation

#### Clinical presentation

A 36-year-old female patient was referred to the department of periodontics for treatment of multiple gingival recession defects in the

maxillary anterior teeth. A comprehensive periodontal evaluation of the patient was done, which revealed multiple Millers class I and class II gingival recession defects in the maxillary anterior region extending from tooth #13 to tooth #23.

#### Case management

At the initial visits, thorough scaling and root planning was performed and measurement of extent of gingival recession was done using a UNC-15 probe (Figure 1). Patient was also advised to maintain good oral hygiene (Table 1).

After 2 weeks, patient was recalled and re-evaluated. Treatment was discussed with the patient and it was determined to perform a root coverage procedure on the maxillary anterior teeth (6 teeth, from #13 to #23). After administration of local anaesthetic, a vestibular access incision was made 2 mm lateral from the midline of the maxillary frenum. This incision was made to provide access to the entire anterior dento-maxillary unit (Figure 2). An Orban's interdental knife along with a periosteal elevator was used to reflect a partial thickness flap from the point of incision till the gingival margin. The angulation of the Orban's interdental knife allows for adequate adaptation of the instrument for the tunnel preparation. After creation of the tunnel, the preparation was evaluated with a UNC-15 probe to ensure that no

Teeth	Recession Measurement Baseline	Recession Measurement 6 Months
13	1.5 mm	0 mm
12	2 mm	0 mm
11	2.5 mm	0 mm
21	2 mm	0.5 mm
22	2.5 mm	1 mm
23	2.5 mm	0 mm

**Table 1:** Root coverage in relation to tooth #13, #12, #11 and #23, improvement in the position of the gingival margin in relation to tooth #21 and #22.

\*Corresponding author: Saket K, Department of Periodontics, Vokkaligara Sangha Dental College and Hospital, Bengaluru, Karnataka, India, Tel: +91-99-86623110; E-mail: [drsaketkashayp1989@gmail.com](mailto:drsaketkashayp1989@gmail.com)

Received: March 02, 2019; Accepted: April 15, 2019; Published: April 18, 2019

Citation: Saket K, Rekha SM, Sushama RG (2019) Management of Multiple Gingival Recession Defects in Aesthetic Zone with VISTA Technique: A Case Report. Oral Health Case Rep 5: 152. doi:10.4172/2471-8726.1000152

Copyright: © 2019 Saket K, et al. This is an open-access article distributed under the terms of the Creative Commons Attribution License, which permits unrestricted use, distribution, and reproduction in any medium, provided the original author and source are credited.

tissue is attached to the underlying periosteum which may hinder the adaptation of PRF membrane (Figure 3).

Platelet Rich Fibrin (PRF) was then prepared by using 20 ml of the patient blood. Blood was drawn from the antecubital fossa and was transferred to a vacutainer tube and placed in centrifuge. The freshly prepared platelet-rich fibrin (PRF) membrane was inserted from the vestibular incision into the prepared tunnel and slowly guided coronally (Figures 4 and 5). The membrane was adjusted to extend at

least 3-4 mm beyond the bony dehiscence's overlying the root surfaces. Once the membrane was in position, the mucogingival complex was then advanced coronally and stabilized in the new position with a continuous papillary sling suture (Figure 6). Direct loop sutures were placed at the vestibular opening. Periodontal dressing was placed to cover the surgical site. Patient was prescribed analgesics and was put on strict oral hygiene maintenance. Suture removal was done 10-day post operatively. Patient was recalled after 6 months and follow-up was done.

### Clinical outcome

Patient was evaluated after 6 months and measurement of the level

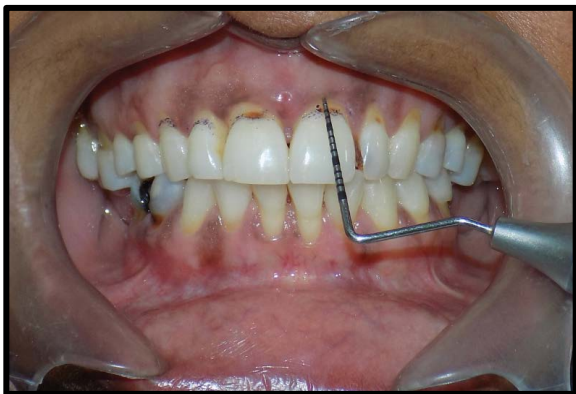


Figure 1: Scaling, root planning and measurement of extent of gingival recession by using a UNC-15 probe.

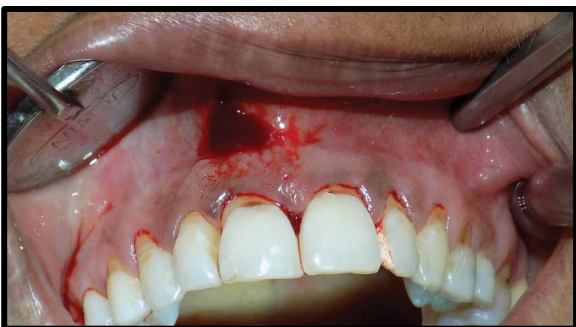

Figure 2: Performance of a root coverage procedure on the maxillary anterior teeth (6 teeth, from #13 to #23) and vestibular access incision was made 2 mm lateral from the midline of the maxillary frenum to provide access to the entire anterior dento-maxillary unit.

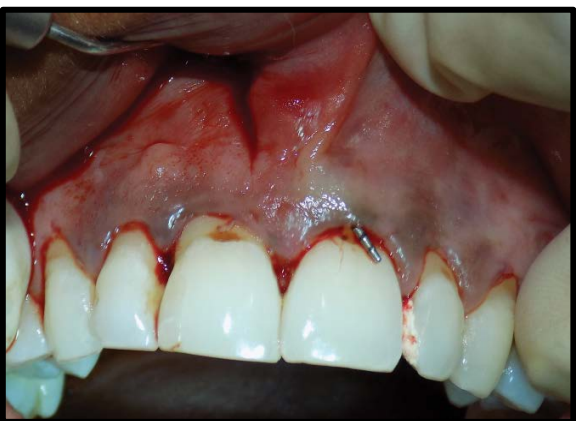

Figure 3: Evaluation of the tunnel with a UNC-15 probe to ensure that no tissue is attached to the underlying periosteum which may hinder the adaptation of PRF membrane.

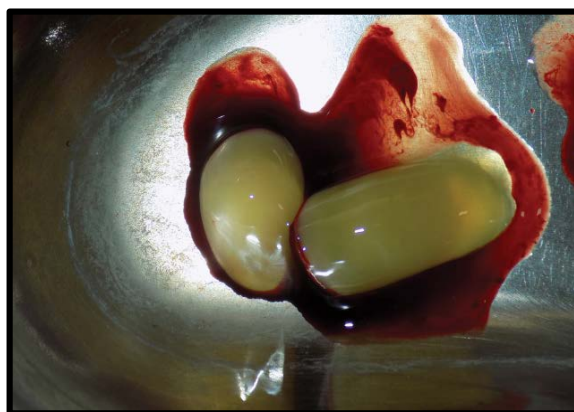


Figure 4: The freshly prepared platelet-rich fibrin (PRF) by the patient blood was inserted from the vestibular incision into the prepared tunnel.

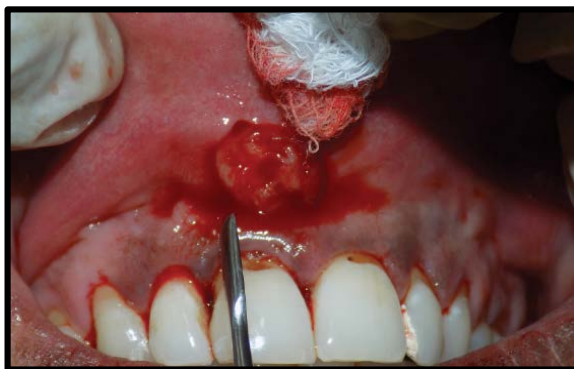

Figure 5: The platelet-rich fibrin (PRF) slowly guided coronally.

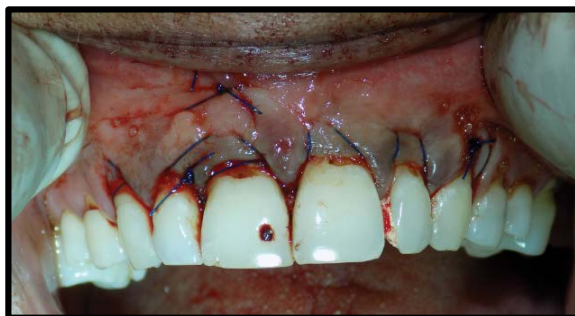
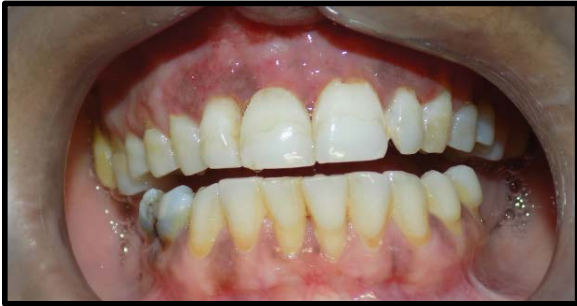

Figure 6: Adjustment of membrane beyond the bony dehiscence's overlying the root surfaces, the mucogingival complex was then advanced coronally and stabilized in the new position with a continuous papillary sling suture.



**Figure 7:** The mean root coverage of 88.4% within 6 months of surgery: Healing phase.

of the gingival margin was performed using a UNC-15 probe. All sites treated with the VISTA approach showed significant degree of root coverage. Four of the six sites treated showed complete root coverage and the patient reported and overall improvement in aesthetics. 6 months after the procedure, the results were stable, and patient did not report post-operative discomfort.

## Discussion

This case report demonstrated the effectiveness of the minimally invasive VISTA technique and the use of PRF for the management of gingival recession defects in the aesthetic zone. There was a significant improvement in the percentage root coverage 6 months post operatively. There was complete root coverage in relation to tooth #13, #12, #11 and #23. There was also significant improvement in the position of the gingival margin in relation to tooth #21 and #22 (Table 1). There was reduction in the recession height from 2 mm to 0.5 mm in relation to #21 and 2.5 mm to 1 mm in relation to #22. Patient also reported satisfactory improvement in the aesthetics. The mean root coverage of 88.4% was obtained 6 months after the surgery. Patient did not report any discomfort during the healing phase and was overall satisfied with the outcome (Figure 7). This is comparable to the improvement reported in the earlier studies on PRF+CAF5 [7].

The management of gingival recession is one of the most important aspects of periodontal therapy. The conventional school of thought aimed at management of periodontal disease by elimination of the etiology and preservation of the periodontal structures. However, with the increasing aesthetic demands, there has been a shift to contain or restore the patient aesthetics as well [8,9]. A number of factors can contribute to the apical migration of gingival margin such as trauma, age changes in the periodontal tissue and periodontal disease. The goal of periodontal therapy should include the elimination of the etiology along with restoring the periodontal structure to their adequate form and function.

There are number of procedures which have been used for the management of gingival recession defects, however, management of defects involving multiple teeth has always been a challenge [8,9]. Recent studies have found that the use of growth factors along with VISTA techniques can be an effective tool in the management of multiple gingival recession defects in the aesthetic zone. Moreover, PRF contains a number of growth factors such as platelet derived growth factor (PDGFs), epidermal growth factor (EGF), transforming growth factor beta (TGF- $\beta$ ), vascular endothelial growth factor (VEGF), insulin like growth factor-1 (IGF-1) which further aid in hard and soft tissue healing [10,11]. Also, these growth factors have been shown to accelerate bone repair and promote fibroblastic proliferation along

with increase in tissue vascularization. Placements of PRF membrane in recession defects have been found to repair gingival defects, re-establish the continuity and integrity of the keratinized gingiva and increasing the gingival thickness. PRF consists of a fibrin matrix polymerized in a tetra molecular structure, with incorporation of platelets, leucocytes, cytokines, and circulating stem cells which aid in hard and soft tissue healing and regeneration [12].

The minimally invasive VISTA approach, combined with a PRF, has a number of advantages for the successful treatment of multiple recession defects, most importantly the maintained blood supply which is compromised in the coronally advanced techniques which involve vertical incisions. Moreover, the inherent disadvantage of the creation of a palatal donor site after harvesting of autologous soft tissue graft can be overcome by the use of appropriate biomaterial. PRF is autogenous in origin, has shown evidence for soft tissue healing and can be a promising biomaterial for periodontal therapy [13].

However, larger sample size and a longer follow-up time are required for effective evaluation of PRF along with the minimally invasive VISTA to evaluate its true potential. The technique shows promising results & can be an effective approach in the management of gingival recession in the aesthetic zone.

## Conclusion

Various treatment options exist for the treatment of gingival recession; however, treatment of multiple gingival recessions is always a greater challenge compared to single recession defects. VISTA technique used in our study is aimed at overcoming the shortcoming of other treatment options and gives better results. However, further studies with large sample size and longer duration are advised to determine the success and predictability of this technique.

## Competing Interests

The authors declare that they have no competing interests.

## References

1. Alghamdi H, Babay N, Sukumaran A (2009) Surgical management of gingival recession: A clinical update. *The Saudi Dental Journal* 21: 83-94.
2. Agarwal DR, Gurav AN, Shete AR, Shetgar S (2015) The VISTA approach to treat gingival recession in esthetic zone: A case report. *IJHSR* 5: 410-414.
3. Monnet-Corti V, Santini A, Glise JM, Fouque-Deruelle C, Dillier FL, et al. (2006) Connective tissue graft for gingival recession treatment: Assessment of the maximum graft dimensions at the palatal vault as a donor site. *J Periodontol* 77: 899-902.
4. Balaji VR, Ramakrishnan T, Manikandan D, Lambodharan R, Karthikeyan B, et al. (2016) Management of gingival recession with acellular dermal matrix graft: A clinical study. *J Pharmacy & Bioallied Sciences* 8: S59.
5. McGuire MK, Scheyer ET, Schuppach P (2009) Growth factor-mediated treatment of recession defects: A randomized controlled trial and histologic and microcomputed tomography examination. *J Periodontol* 80: 550-564.
6. Dohan DM, Choukroun J, Diss A, Dohan SL, Dohan AJ, et al. (2006) Platelet-rich fibrin (PRF): A second-generation platelet concentrate. Part I: Technological concepts and evolution. *Oral Surg Oral Med Oral Pathol Oral Radiol Endod* 101: e37-e44.
7. Jankovic S, Klokkevold P, Dimitrijevic B, Kenney EB, Camargo P (2012) Use of platelet rich fibrin membrane following treatment of gingival recession: A randomized control clinical trial. *Int J Periodontics Restorative Dent* 32: e41-50.
8. Oates TW, Robinson M, Gunsolley JC (2003) Surgical therapies for the treatment of gingival recession: A systematic review. *Ann Periodontol* 8: 303-320.
9. Anilkumar K (2009) Platelet-rich-fibrin: A novel root coverage approach: Case report. *JISP* 13: 50-54.

- 
10. Chatterjee A, Sharma E, Gundanavar G, Subbaiah SK (2015) Treatment of multiple gingival recessions with vista technique: A case series. *J Indian Soc Periodontol* 19: 232-235.
  11. Anitua E, Sanchez M, Orive G, Andia I (2007) The potential impact of the preparation rich in growth factors (PRGF) in different medical fields. *Biomaterials* 28: 4551-4560.
  12. Agarwal K, Chandra C, Agarwal K, Kumar N (2013) Lateral sliding bridge flap technique along with platelet rich fibrin and guided tissue regeneration for root coverage. *J Indian Soc Periodontol* 17: 801-805.
  13. Shori T, Kolte A, Kher V, Dharamthok S, Shirao T (2013) A comparative evaluation of the effectiveness of subpedicle acellular dermal matrix allograft with subepithelial connective tissue graft in the treatment of isolated marginal tissue recession: A clinical study. *J Indian Soc Periodontol* 17: 78-81.