

# Kounis Syndrome in a Patient Following AstraZeneca COVID-19 Vaccination

Asif Mohamed Farook\* and Dilshan Priyankara

Department of Critical Care Medicin, National Hospital of Sri Lanka, Colombo, Sri Lanka

## Abstract

Kounis syndrome also known as allergic angina syndrome is defined as the occurrence of an acute coronary syndrome concomitantly with hypersensitivity reaction. It was first described in 1991 by Kounis and Zavras. It is a rare syndrome and is often an under diagnosed phenomenon as physicians are unaware of the condition. We discuss a 54 years old female Sri Lankan patient who developed Kounis syndrome following Oxford Astra Zeneca COVID-19 vaccination. The patient initially developed anaphylaxis following the Astra Zeneca COVID-19 vaccine and subsequently developed acute coronary syndrome secondary to anaphylaxis. Patient was treated appropriately and eventually recovered from her condition. This syndrome should be suspected when there is concurrent acute coronary syndrome with allergic reactions. Care givers should be aware of its pathophysiology as treatment of either of the two may worsen the other injury.

**Keywords:** Case report • Kounis syndrome • Anaphylaxis • Allergic angina syndrome

## Introduction

Kounis syndrome is not rare but under diagnosed and often misdiagnosed leading to inappropriate treatment. It has rarely been discussed and reported in literature [1]. It is estimated the incidence of this syndrome among all allergic patients was nineteen per one hundred thousand. It has been reported in every geographical location, age group and every race [2].

It is a rare syndrome and is often an under diagnosed phenomenon as physicians are unaware of the condition. We discuss a 54 years old female Sri Lankan patient who developed Kounis syndrome following Oxford Astra Zeneca COVID-19 vaccination.

## Case Presentation

Our patient is a 54 years old health care worker of Sri Lankan origin with a history of hypertension, ischemic heart disease stable angina and bronchial asthma on inhalers. She also has a significant history of allergies including multiple drug allergies along with an episode of contrast induced severe anaphylaxis 2 years back. On the morning of presentation, she was administered the Astra Zeneca COVID-19 vaccine and was under observation. Fifteen minutes later developed severe anaphylaxis. Immediately intramuscular 1:10000 adrenaline was administered. Due to poor response repeated intramuscular adrenaline given. Fluid resuscitation done with normal

saline boluses. Despite treatment her symptoms were slow to improve, arterial blood gas showed severe metabolic acidosis and was started on an epinephrine infusion. Symptoms of the patient gradually improved with this. She was transferred to our hospital for further management and observation of recurrence of anaphylaxis. On arrival to the ICU, she was clinically stable. On arrival she complained of severe retrosternal chest pain. An electrocardiogram done immediately showed horizontal ST segment depression of >3 mm in the inferior leads (II, III, AVF). Considering these clinical and electrical findings, the diagnosis of acute coronary syndrome concomitant with anaphylactic reaction Kounis syndrome was suspected. Anti-ischemic treatment was initiated. As she had clinical features of heart failure appropriate treatment was initiated. Bed side transthoracic echocardiography was done which showed moderate left ventricular dysfunction (EF-40%) with inferior wall hypokinesia. Her troponin I levels were extremely high 17.61 ng/ml (<0.5) and IgE levels were elevated 895.7/iu/ml. Her anti-anaphylactic treatment was continued. Cardiology team suggested medical management of her acute coronary syndrome as there is a history anaphylaxis to contrast agents. She was clinically stable and discharged on day seven of illness [3].

## Results and Discussion

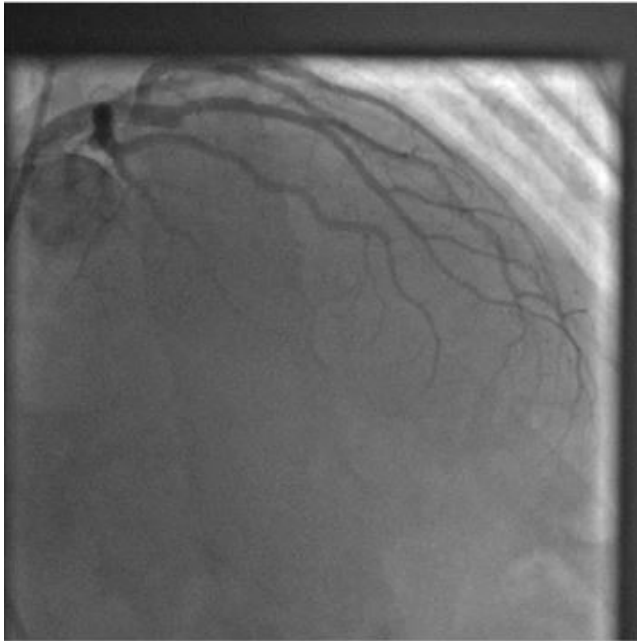
It was first described in 1991 by Kounis and Zavras. Many environmental exposures and drugs can cause Kounis syndrome. It

\*Address for Correspondence: Asif Mohamed Farook, Department of Critical Care Medicin, National Hospital of Sri Lanka, Colombo, Sri Lanka, Tel: 94770745445; E-mail: asif\_farook@yahoo.com

Copyright: © 2023 Farook AM, et al. This is an open-access article distributed under the terms of the creative commons attribution license which permits unrestricted use, distribution and reproduction in any medium, provided the original author and source are credited.

Received: 29 September, 2022, Manuscript No. JIB-22-76269; Editor assigned: 03 October, 2022, PreQC No. JIB-22-76269 (PQ); Reviewed: 14 October, 2022, QC No. JIB-22-76269; Revised: 28 November, 2022, Manuscript No. JIB-22-76269 (R); Published: 06 January, 2023, DOI: 10.37421/2476-1966.2023.8.185

is not rare but underdiagnosed and often misdiagnosed leading to inappropriate treatment. It has rarely been discussed and reported in literature [4]. It is estimated the incidence of this syndrome in the among all allergic patients was nineteen per one hundred thousand. It has been reported in every geographical location, age group and every race (Figure 1).



**Figure 1.** Coronarography showing total mid-left anterior descending artery occlusion (Thrombolysis in myocardial infarction grade flow 0).

The mechanism of Kounis syndrome is not well understood until now. Several pathophysiological mechanisms described to explain acute coronary syndrome in anaphylactic reactions. The main pathophysiological mechanism is vasospasm of epicardial coronary arteries due to release of inflammatory mediators during allergic reaction. Release of inflammatory mediators such as histamine, leukotrienes, prostaglandins, platelet activation factors from mastocytes and other inflammatory cells leads to anaphylactic activation and leads to vaso spastic angina and myocardial infarction. Another contributing factor in anaphylaxis which may worsen cardiac injury is prolonged hypotension, especially in patients with critical coronary stenosis. In whom hypotension provokes myocardial ischemia. Risk factors for Kounis syndrome include previous allergy, previous cardiovascular disease, hypertension, diabetes, and smoking [5].

Diagnosis of Kounis syndrome is based on clinical manifestations. Many cases are missed or underdiagnosed due to unawareness of physicians. ECG will show infarction/ischemia suggestive of acute coronary syndrome most commonly in the inferior leads. Serum troponin, Serum tryptase, IgE will be elevated. Coronary angiogram is usually normal.

In the management of Kounis syndrome we should consider myocardial revascularization in conjunction with the treatment of allergic reaction. The difficulty lies in the fact that the treatment of either of the entities may worsen the other injury. There are no clear guidelines for the treatment of Kounis syndrome up to now. Most of the recommendations are based on individual case reports.

Adrenaline is the medication of choice to relieve life threatening anaphylaxis, but the paradox is it may aggravate myocardial ischemia and can cause coronary vasospasm and arrhythmias especially if administered intravenously. Thus, intramuscular route of administering adrenaline is preferred in these patients. For the treatment of allergic reactions both H<sub>1</sub> and H<sub>2</sub> antihistamines and Ranitidine can be used. Bolus use of these drugs can cause hypotension and compromise coronary flow. Thus, these drugs should be given slowly. Steroids are often used in allergic reactions but may impair wound healing causing myocardial wall thinning and cardiac aneurysm. Fluid resuscitation is an important aspect of management of distributive shock, Patients with acute coronary syndrome are at risk of pulmonary oedema and haemo dynamic instability so fluid resuscitation should be done cautiously. Aspirin has a key role in the management of angina but that it can induce or worsen anaphylaxis. In anginal pain opioids have a key role as an analgesic, anxiolytic, but their use may lead to mast cell degranulation which may aggravate anaphylaxis. As such they should be prescribed cautiously.

Primary percutaneous coronary intervention is the preferred reperfusion strategy in the acute coronary syndrome. If it cannot be performed thrombolysis should be considered.

## Conclusion

Kounis syndrome is a rarely recognized and underdiagnosed condition. Physicians should be aware of this condition and suspect it whenever they present concurrently with angina and anaphylaxis. This is a medical emergency and immediate treatment should be initiated for both conditions. The treatment of Kounis syndrome is challenging because treatment of either of the two can lead to worsening of the other injury. The treatment of this condition is a fine balancing act and extra precaution should be taken before initiation of certain medications. There are no standard guidelines for the management of Kounis syndrome.

## Acknowledgements

Not applicable

## References

1. Omri, Majdi, Hajer Kraiem, Olfa Mejri, and Mounir Naija, et al. "Management of Kounis syndrome: two case reports." *J Med Case Rep* 11 (2017): 1-6.
2. Sciatti, Edoardo, Enrico Vizzardi, Dario S Cani, and Assunta Castiello, et al. "Kounis syndrome, a disease to know: Case report and review of the literature." *Monaldi Arch Chest Dis* 88 (2018): 898.
3. Cevik, Cihan, Kenneth Nugent, Goutam P Shome, and Nicholas G Kounis, et al. "Treatment of Kounis syndrome." *Int J Cardiol* 143 (2010): 223-226.
4. Kounis, Nicholas G. "Kounis syndrome: an update on epidemiology, pathogenesis, diagnosis and therapeutic management." *Clin Chem Lab Med* 54 (2016): 1545-1559.
5. Fassio, Filippo, Laura Losappio, Dario Antolin-Amerigo, and Silvia Peveri, et al. "Kounis syndrome: a concise review with focus on management." *Eur J Intern Med* 30 (2016): 7-10.

**How to cite this article:** Farook, Asif Mohamed and Dilshan Priyankara. "Kounis Syndrome in a Patient Following Astrazeneca COVID-19 Vaccination." *J Immuno Biol* 8 (2023): 185.