

# Keratomalacia in a Patient with Vitamin A Deficiency

Roheen Zabih Ur Rahman<sup>\*</sup>, Saleh Mirwais and Hamid Naim

Department of Ophthalmology, Kabul University of Medical Science, Kabul, Afghanistan

## Abstract

**Purpose:** To report the clinical finding of a patient with bilateral keratomalacia arising from severe vitamin- A deficiency from a malnourished diet.

**Results:** A 2-years old female with severe malnutrition presented with 3 weeks of watering and tonic blepharospasm affecting the right and left eyes. She exhibited hypertrichosis, severe weight loss, abnormal hairs with complete corneal melt in the right and left eyes and inflamed iris tissue in the right eye. She was treated with high dose vitamin A, but the right eye required evisceration and tarsorrhaphy was done in the left eye.

**Conclusion:** The visual morbidity associated with xerophthalmia secondary to vitamin A deficiency can be devastating. Vitamin A deficiency is prevalent in developing and war thorn countries. A good history taking and review of systems are valuable in evaluating malnourished patients with corneal melt.

**Keywords:** Keratomalacia • Xerophthalmia • Vitamin A deficiency

## Introduction

Vitamin A deficiency is the leading cause of preventable childhood blindness and increase the risk of death from common childhood illnesses such as diarrhea. Vitamin A deficiency is estimated to affect more than 250 million children worldwide, with nearly 3 million suffering xerophthalmia every year, of who between a quarter and half a million go blind [1]. A fat-soluble vitamin, 90% of vitamin A is stored in the liver [2]. Human deficient in vitamin-A grew poorly, suffered more persistent or severe infections, and subsequently develops characteristic ocular manifestations termed "xerophthalmia". Vitamin-A is required to maintain specialized epithelia (such as in the cornea and conjunctiva). Vitamin-A deficiency can be caused by different etiologies and may lead to severe complications including keratomalacia, or melting of the corneal stroma, that may result in corneal scarring or perforation when the deficiency is not treated urgently [3]. We report a rare case of patient with bilateral corneal melt arising from severe vitamin-A deficiency secondary to malnutrition related to lack of appropriate diet [3].

## Case Presentation

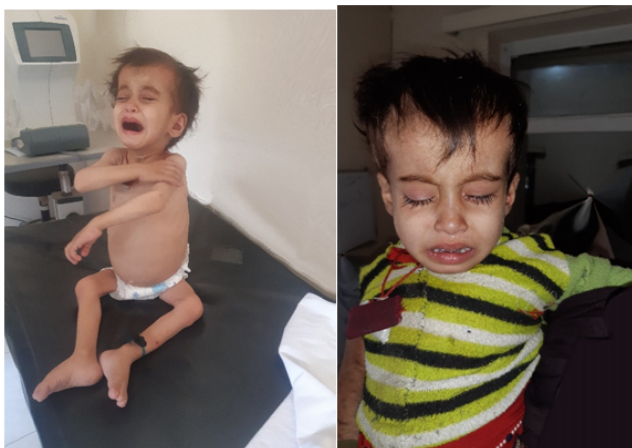A two-year-old female child presented to out patient department of university eye hospital (Kabul University of Medical Science, Kabul, Afghanistan). According to patient parent's history, in the last three weeks the patient has progressive pain, tearing and tonic blepharospasm that she cannot open her eyes. The child weighed 10 kg and measured 60 cm in height. The patient was carried to provincial hospital and due to lack of ophthalmologist she was then referred to University Eye Hospital at Kabul [4].

The patient parents were living in a remote district under control of insurgents, where no medical facilities are present and even no vaccination campaign are allowed, it is worthwhile that during vaccination campaign supplemental vitamin-A is also given to children under age of 5 years. The socio-economic situation of the parents was not good, as the child father was disabled with no stable payment, meanwhile family planning was not observed. On presentation the patient was cachectic and irritable, the hairs were thin and pale, and hypertrichosis was found (Figure 1) [5].

<sup>\*</sup>Address to Correspondence: Roheen Zabih Ur Rahman, Department of Ophthalmology, Kabul University of Medical Science, Kabul, Afghanistan, Tel: 9386637018; E-mail: zabih.roheen@gmail.com

**Copyright:** © Rahman RZU, et al. This is an open-access article distributed under the terms of the creative commons attribution license which permits unrestricted use, distribution and reproduction in any medium, provided the original author and source are credited.

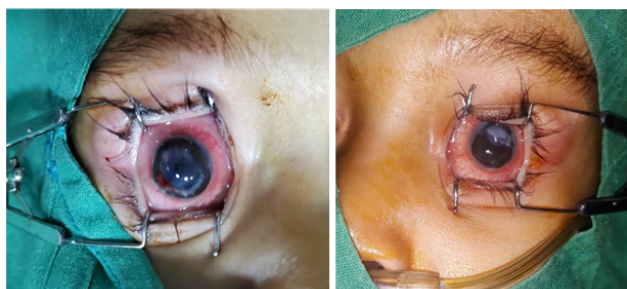
**Received:** 24-January-2022, Manuscript No. VTE-22-53621; **Editor assigned:** 26-January-2022, Pre QC No. VTE-22-53621; **Reviewed:** 09-February-2022, QC No. VTE-22-53621; **Revised:** 24-March-2022, Manuscript No. VTE-22-53621; **Published:** 31-March-2022, DOI: 10.4172/2376-1318.2022.11.188.



**Figure 1.** Clinical photographs of the patient shows severe malnutrition, with thin, long and hypopigmented hairs. Meanwhile hypertrichosis is visible in both eyelashes.

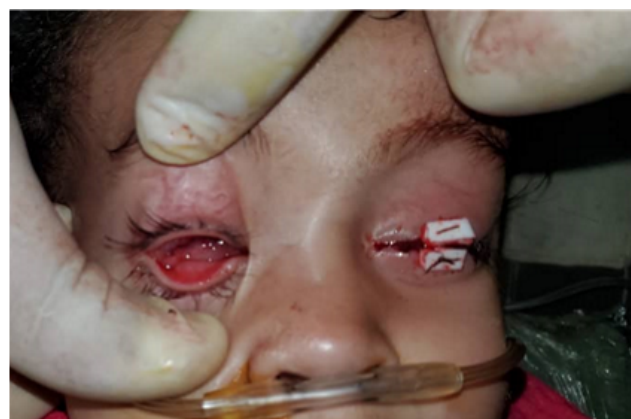## Results and Discussion

As slit lamp examination was impossible, she was admitted for exam under anesthesia in the next day. EUA revealed diffusely chemotic and keratinized conjunctiva in both eyes (OU) with xerosis but no bitot spots. Both corneas demonstrated total melt from limbus to limbus, with a collapsed anterior chamber. The right eye had a purulent iris that was affixed to lens by extensive posterior synechia (Figure) [6].



**Figure 2.** Clinical photographs of the patient demonstrated total corneal melt in both eyes. The right eye has purulent iris attached to lens by posterior synechia.

A diagnosis of X3-B keratomalacia with severe protein-energy malnutrition was made. Treatment was initiated in the form of 200,000 units of vitamin-A acetate administered by mouth in the divided doses for 2 days and repeated 2 weeks later [7]. Because of poor visual potential and chance of sympathetic ophthalmia, the patient right eye was eviscerated and the patient left eye was treated with temporary tarsorrhaphy. The patient was then referred to welfare eye institution for possible corneal graft (Figure) [8,9].



**Figure 3.** Post-operative photo of the patient shows that evisceration is done in right eye and the left eye is treated with temporary tarsorrhaphy.

Keratomalacia resulting from vitamin-A deficiency is an important cause of preventable corneal blindness and opacification and major cause of pediatric ocular morbidity and severe visual impairment in developing countries. Vitamin-A deficiency cause a spectrum of ocular disease known as xerophthalmia, which includes changes in both anterior and posterior segments. Conjunctival xerosis with keratinizing squamous metaplasia, loss of goblet cells, and heaped accumulation of keratin (Bitot Spots) are characteristic, and corneal pathology can range from mild epitheliopathy to severe keratomalacia resulting in blindness.

## Conclusion

In the developing countries, family's education about healthy diet and importance of participation in vaccinations campaigns in which supplemental vitamin-A is also administered to children under 5 years of age, will reduce the risk of vitamin A deficiency and consequent ocular morbidities. Our case illustrates the importance of obtaining a thorough nutritional history and review of systems in patient with corneal melt. A high index of suspicion for vitamin-A deficiency with prompt initiation of vitamin A supplementation will prevent from severe visual impairment.

## References

1. Sommer, Alfred. "Vitamin A Deficiency and its Consequences: A Field Guide to Detection and Control." World Health Organization 1995.
2. Cheshire, James, and Kolli Sai. "Vitamin A Deficiency due to Chronic Malabsorption: An Ophthalmic Manifestation of a Systemic Condition." *Case Rep* 2017.
3. Collins, Cian E, and Koay Peter. "Xerophthalmia because of Dietary-Induced Vitamin A Deficiency in a Young Scottish Man." *Cornea* 29 (2010): 828-829.
4. Cooney, Theresa M, Johnson C Starck, and Elnor Victor M. "Keratomalacia Caused by Psychiatric-Induced Dietary Restrictions." *Cornea* 26 (2007): 995-997.
5. Reed, D, Brundridge W, Gallagher C, and Santamaria J, et al. "Case Report of Recurrent Xerophthalmia Associated with Vitamin A Deficiency Secondary to Lipid Malabsorption Following Extensive Colon Resection." *Vitamins Minerals* 7 (2018): 2376-1318.

6. Gospe III, Sidney M, Todorich Bozho, and Foster Yevgeniya G, et al. "Keratomalacia in a Patient with Psychogenic Vitamin A Deficiency." *Cornea* 35 (2016): 405-407.
7. Suan, Eric P, Bedrossian Edward H, and Eagle Ralph C, et al. "Corneal Perforation in Patients with Vitamin A Deficiency in the United States." *Arch Ophthalmol* 108 (1990): 350-353.
8. World Health Organization. "Global Prevalence of Vitamin A Deficiency in Populations at Risk 1995-2005: WHO Global Database on Vitamin A Deficiency." (2009).
9. Deepthi, Pullepu, Janga Deepthi, and Krishna V Murali. "Keratomalacia: A Case Report." *J Clin Med Res* (2020): 208-210.

**How to cite this article:** Rahman, Roheen Zabih Ur, Mirwais Saleh, and Naim Hamid. "Keratomalacia in a Patient with Vitamin A Deficiency." *Vitam Miner* 11 (2022): 188