

Making the Connection: Incidental Finding Of Coronary Artery Fistula

Yesha Patel Rana^{1*}, Larab Giniyani¹, Vineet Meghrajani², Yili Huang² and Tak Kwan²

¹Department of Internal Medicine, Mount Sinai Beth Israel Medical Center, New York, NY-10003, USA

²Department of Cardiology, Mount Sinai Beth Israel Medical Center, New York, NY-10003, USA

Abstract

Coronary artery fistulas (CAF) are rare congenital or acquired coronary artery anatomic anomalies. They can develop from any of the three coronary arteries and drain into any of the cardiac chambers and great vessels thus creating an anatomic bypass of the myocardial capillary network. In our case, we present an 81-year-old who was referred for left heart catheterization after having found myocardial ischemia on perfusion imaging. Incidentally, he was found to have a fistula connection between the left circumflex coronary artery with the pulmonary artery. We present an atypical case of a circumflex coronary artery as a rare point of origin for a fistula with an incidence of about 18%.

Keywords: Coronary artery • Valve replacement • Fistula • Diabetes mellitus • Heart catheterization

Introduction

Coronary artery fistulas (CAF) are rare congenital or acquired coronary artery anatomic anomalies that can develop from any of the three coronary arteries and drain in any of the cardiac chambers and great vessels thus creating an anatomic bypass of the myocardial capillary network [1,2]. Though the majority of CAFs are congenital in origin, they may occasionally be detected after certain cardiac procedures such as valve replacement, coronary artery bypass grafting, and myocardial biopsies. Their incidence has been found to be about 0.002% in the overall population and constitute to be about 0.13% of congenital cardiac lesions [1]. CAFs have been found to be one of the most frequent congenital anomalies relating to the coronary arteries; however, they remain rare in presentation and usually are incidentally found on coronary angiography. We present a rare anatomic presentation of a coronary artery fistula connecting the left circumflex artery to the pulmonary artery in an adult.

Case Study

An 81-year-old male with a past medical history significant for controlled hypertension, non-insulin dependent diabetes mellitus, hyperlipidemia, obstructive sleep apnea presented to our hospital for an elective diagnostic left heart catheterization. He had prior anginal symptoms for which he was referred for a left heart catheterization (LHC) after myocardial perfusion imaging with single photon emission computed tomography was significant for intermediate risk for ischemia. Previous transthoracic echocardiogram showed a left ventricular ejection fraction of 50%. Two diseased vessels were discovered involving the right coronary artery and the left anterior descending artery (LAD). There was 80-90% stenosis with calcification of the proximal LAD with pre TIMI flow of 2. Incidentally, an aneurysmal branch that exhibits

a fistula connection from the left circumflex coronary artery with the pulmonary artery was discovered as well (Figure 1).

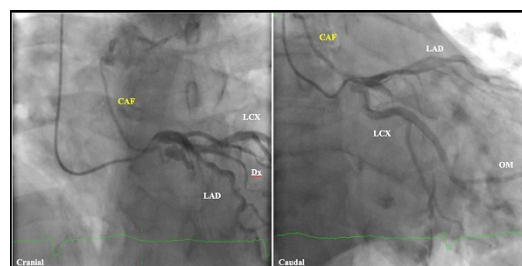


Figure 1. Angiography image of coronary artery fistula between the LCx and Pulmonary Artery.

Successful intervention of the proximal LAD with arthroscopy and placement of a drug eluting stent was performed without complication. Post intervention TIMI flow was 3. The fistula showed no hemodynamic compromise, so no attempt for closure was made. The patient tolerated the procedure well and was able to be discharged on the same day.

Discussion

We present a rare presentation of a coronary artery fistula incidentally found on coronary angiogram [2]. They are found in about 0.05%-0.25% of patients who undergo a coronary angiogram. A literature review shows that there is not a consensus regarding the origin or prediction of the anatomy. Majority of these CAFs originate from either coronary artery and commonly drain in low pressure structures including the right sided chambers, pulmonary artery, superior vena cava vein, and coronary sinus [3,4]. The CAFs most commonly originate from the right coronary artery in about 52% of cases and left anterior descending coronary artery in approximately 30%

*Address for Correspondence: Yesha Patel Rana, Department of Internal Medicine, Mount Sinai Beth Israel Medical Center, New York, NY 10003, USA, Tel: +2122020000; E-mail: yesha.patel@mountsinai.org

Received: 16 June, 2020; Accepted: 25 June, 2020; Published: 03 July, 2020

Copyright: © 2020 Rana YP, et al. This is an open-access article distributed under the terms of the creative commons attribution license, which permits unrestricted use, distribution, and reproduction in any medium, provided the original author and source are credited.

of cases. The circumflex coronary is a much rarer point in origin with incidence of about 18% of cases [5]. Most common sites for drainage are the right ventricle (41%), followed by right atrium (26%), and the pulmonary artery (17%) [1,6]. A fistula between the left circumflex artery and the pulmonary artery, as in this case, is a very rare finding.

Most patients are asymptomatic, such as this patient, and a continuous cardiac murmur is the most reported finding upon physical exam. The age at presentation is highly varied, ranging across all ages and genders. Some presenting factors can include angina, dyspnea on exertion, syncope, and palpitations. In more severe cases, symptoms of volume overload and ischemia could be present. CAFs have been reported to be implicated in the manifestation of certain complications such as arrhythmia, coronary artery aneurysm and rupture, and potentially sudden death as well [7,8]. Cardiac catheterization and coronary angiography are necessary to delineate the exact anatomy, assess hemodynamics of the fistula, and evaluate for the presence of concomitant atherosclerosis.

Intervention for fistula correction is recommended for symptomatic patients and those at risk for future complications that may include but are not limited to embolization, dissection, pulmonary hypertension, myocardial ischemia, or infarction [1-3]. Our patient exhibited limited risk in future complications given that he had no prior anginal or dyspnea on exertion symptoms prior to presentation for the elective angiography. However, should the fistula have exhibited hemodynamic instability or impaired flow, several approaches for correction could have been considered including surgical or percutaneous intervention [1,6]. Although, CAFs are rarely implicated in asymptomatic patients, it can be an important consideration in patients that are symptomatic [7,8].

Conclusion

We present a rare anatomic presentation of coronary artery fistula seen incidentally on coronary angiogram. CAFs can remain asymptomatic over many years and should be considered in patients that develop sudden angina or exertional dyspnea. In cases where CAF shows no hemodynamic instability, patients should be monitored for developing changes in clinical presentation.

Conflicts of Interest

Author have no conflict of interest to declare.

References

1. Dadkhah-Tirani, Heidar, Arsalan Salari, Shora Shafighnia, and Seyed Fazel Hosseini, et al. "Coronary artery to pulmonary artery fistula." *Am J Case Rep* 14 (2013): 486.
2. Qureshi, Shakeel A. "Coronary arterial fistulas." *Orphanet J Rare Dis* 1 (2006): 1-6.
3. Gowda, Ramesh M., Balendu C. Vasavada, and Ijaz A. Khan. "Coronary artery fistulas: Clinical and therapeutic considerations." *Int J Cardiol* 107 (2006): 7-10.
4. Levin, David C., Kenneth E. Fellows, and H. L. Abrams. "Hemodynamically significant primary anomalies of the coronary arteries. Angiographic aspects." *Circulation* 58 (1978): 25-34.
5. McNamara, J. Judson, and Robert E. Gross. "Congenital coronary artery fistula." *Surgery* 65 (1969): 59-69.
6. Papadopoulos, Dimitris P., Alexandros Perakis, V. Votreas, and Sophia Anagnostopoulou. "Bilateral fistulas: A rare cause of chest pain. Case report with literature review." *Hellenic J Cardiol* 49 (2008): 111-113.
7. Hobbs, Robert E., H. David Millit, Prakash V. Raghavan, and Douglas S. Moodie, et al. "Coronary artery fistulae: A 10-year review." *Cleve Clin Q* 49 (1982): 191-197.
8. Sunkara, Anusha, Lakshmi H. Chebrolu, Su Min Chang, and Colin Barker. "Coronary artery fistula." *Methodist Debakey Cardiovasc J* 13 (2017): 78.

How to cite this article: Yesha Patel Rana, Larab Giniyani, Vineet Meghrajani, and Yili Huang, et al. "Making the Connection: Incidental Finding Of Coronary Artery Fistula". *J Cardiovasc Dis Diagn* 8 (2020) doi: 10.37421/jcdd.2020.8.410