

Endoscopic Loop-and-Leave-Technique For Management of Large Colonic Lipoma

Roqueia Cumbana* , Carlos Noronha Ferreira, LuísCarrilho Ribeiro and Rui Tato Marinho Serviço

Department of Gastroenterologia e Hepatologia, Hospital de Santa Maria, Centro Hospitalar Universitário Lisboa Norte, Lisbon, Portugal

Description

A 52-year-old female, with no relevant past history, underwent colorectal cancer screening colonoscopy which revealed presence of a large pseudopolypoid yellowish submucosal lesion measuring around 4 cm in transverse colon.

The lesion had a modulated surface with a wide base and was soft to touch with a closed biopsy forceps "pillow sign" (Figure 1).

After biopsies of the lesion, extrusion of tissue with fat "naked fat sign" was observed. As the endoscopic signs were compatible with a lipoma, an endoloop was placed at the base of the lesion to allow the lesion to fall off after ischemic necrosis of the base "Loop and leave technique" (Figure 2).

Colonic lipomas are uncommon benign adipose tumours of the colon,

usually asymptomatic and found incidentally during colonoscopy, surgery or autopsy. Transformation to liposarcoma is extremely uncommon. Management depends on size and symptoms related to colonic lipoma. Endoscopic resection of large colonic lipoma is controversial because of reports of high rates of perforation. The novel technique consisting of looping and ligating the lipoma with the detachable snare, avoiding the need for electrocautery and eliminating the risk of perforation or bleeding. In this case this technique was safe and alternative for surgery.

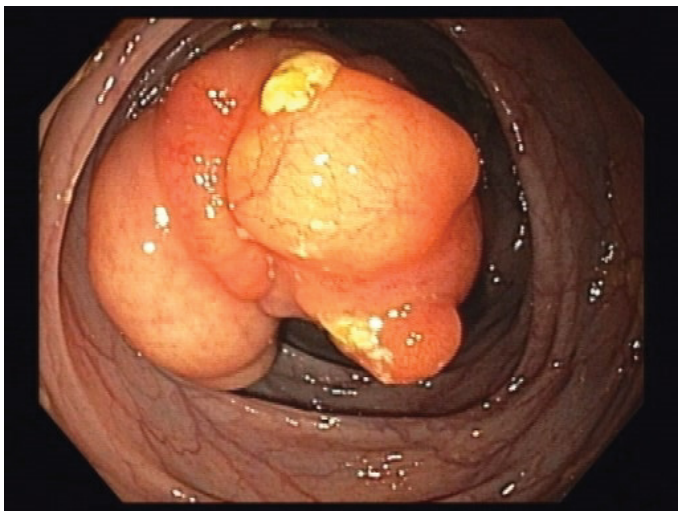


Figure 1: Closed biopsy forceps "pillow sign"

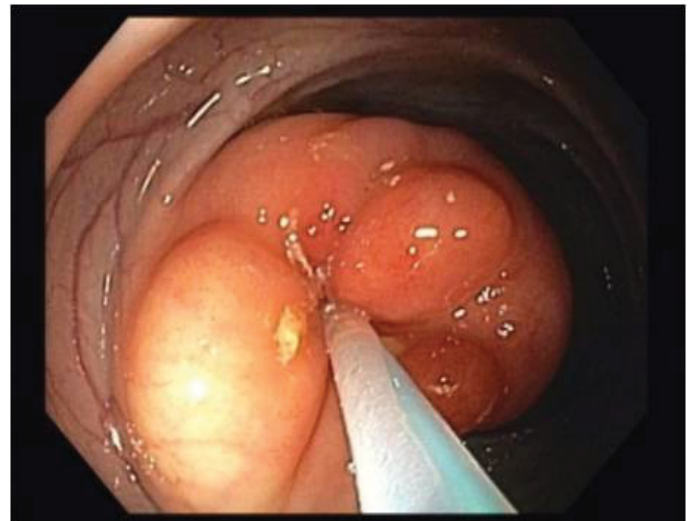


Figure 2: Loop and leave technique

How to cite this article: Roqueia Cumbana, Carlos Noronha Ferreira, LuísCarrilho Ribeiro and Rui Tato Marinho Serviço. "Endoscopic Loop-and-Leave-Technique For Management of Large Colonic Lipoma". *Clin Gastroenterology* 5 (2020): 128

***Address for Correspondence:** Roqueia Cumbana, Department of Gastroenterologia e Hepatologia, Hospital de Santa Maria, Centro Hospitalar Universitário Lisboa Norte, Lisbon, Portugal, Tel:938726722; E-mail: roqueiafernanda@gmail.com

Copyright: © 2020 Cumbana R, et al. This is an open-access article distributed under the terms of the Creative Commons Attribution License, which permits unrestricted use, distribution, and reproduction in any medium, provided the original author and source are credited.

Received 07 July 2020; Accepted 22 July 2020; Published 30 July 2020