

# Coronary Sinus Ostium Atresia Associated with Direct Connection to the Superior Vena Cava by a Bridging Vein: A Case Report

Laxman Gyawali\*

Department of Cardiology, The Second Affiliated Hospital of Chongqing Medical University 74-Lin Jiang Road, Yu Zhong District, Chongqing Province, P. R. China

## Abstract

Coronary sinus ostial atresia is a rare encounter in the intervention laboratory and is often linked with several congenital cardiac anomalies such as persistent left superior vena cava among others. Over the course of Cardiac Resynchronization Therapy (CRT), our case had the coronary sinus directly communicating with the superior vena cava through an anomalous bridging vein in the absence of a persistent left superior vena cava, along with an atretic right atrial ostium. Also, of interest was the minimal amount of technical challenge offered by such an anomaly for CRT lead implantation provided an otherwise favorable coronary anatomy.

**Keywords:** Coronary sinus ostium atresia; Persistent superior vena cava; Bridging vein

## Introduction

A 62-years-old gentleman was diagnosed as Dilated Cardiomyopathy. Pertaining to the inadequate response of his heart failure symptoms to optimized heart failure therapy, NYHA Grade-III functional status, LVEF: 26%, Complete LBBB (QRS>130 ms) and significant bi-ventricular dyssynchrony (78 ms), Cardiac Resynchronization Therapy (CRT) was recommended based on the 2012 ACCF/AHA/HRS IIA guidelines.

## Case Report

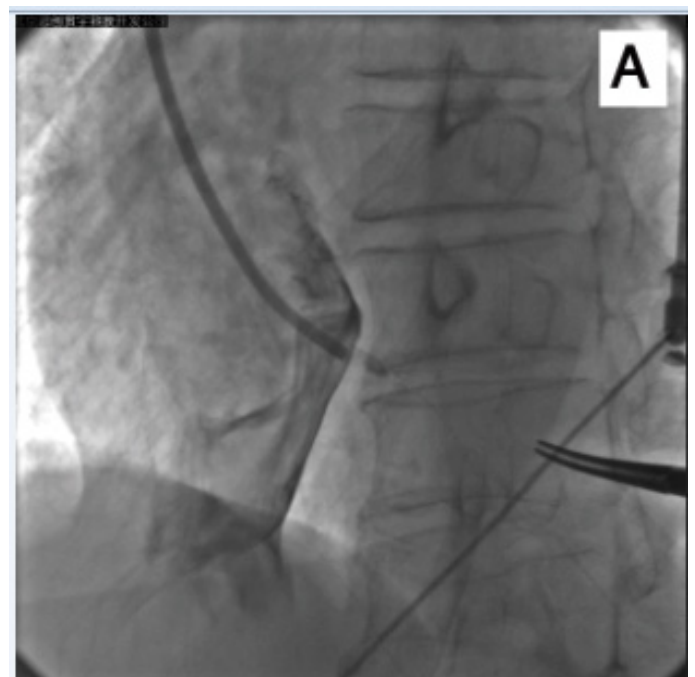
Following proper protocol, the left pectoral pocket was created. Using a 9 French introducer, the St. Jude CPS Direct PL Peelable Outer Guide Catheter System was deployed over the wire and advanced to the postero-inferior atrial septum. The steerable catheter was positioned around the vicinity of the Coronary Sinus (CS) ostium. Several alignments were made to engage the opening with no success. Common anatomic variations of the coronary sinus ostium such as malposition, vertical orientation, angulation was considered, and cannulation attempts were accordingly tailored but unsuccessful. Right atrial angiography was performed with 10-20 ml push of Iodixanol but no opening into the venous system was visualized on at least 2 attempts (Figure 1A). Coronary venous anatomy was visualized following coronary angiography using routine procedure. The coronary sinus was observed to drain into the SVC with an anomalous bridging vein almost thrice the length of the coronary sinus trunk and an atretic right atrial ostium. A blind pouch was visible at the postero-inferior septal location with no contrast seen flowing out into the right atrium. The coronary sinus trunk was well visualized, non-dilated and non-tortuous. The Middle Cardiac Vein (MCV), the Anterior Interventricular Vein (AIV) and the Great Cardiac Vein (GCV) vein were identified at their popular anatomical landmarks (Figure 1B).

\*Address for Correspondence: Gyawali L, Department of Cardiology, The Second Affiliated Hospital of Chongqing Medical University 74-Lin Jiang Road, Yu Zhong District, Chongqing Province, P. R. China, E-mail: laxu49@hotmail.com

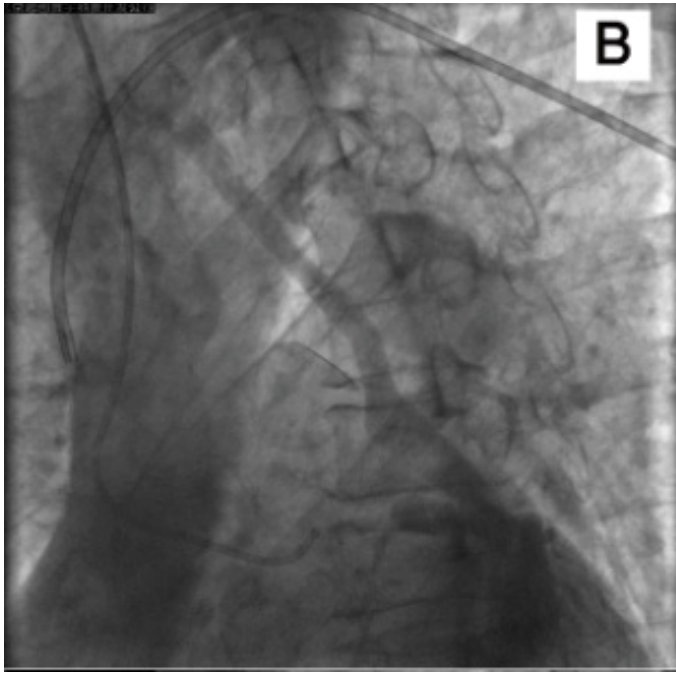
**Copyright:** © 2021 Gyawali L, et al. This is an open-access article distributed under the terms of the Creative Commons Attribution License, which permits unrestricted use, distribution, and reproduction in any medium, provided the original author and source are credited.

**Received** 10 March 2021; **Accepted** 24 March 2021; **Published** 31 March 2021

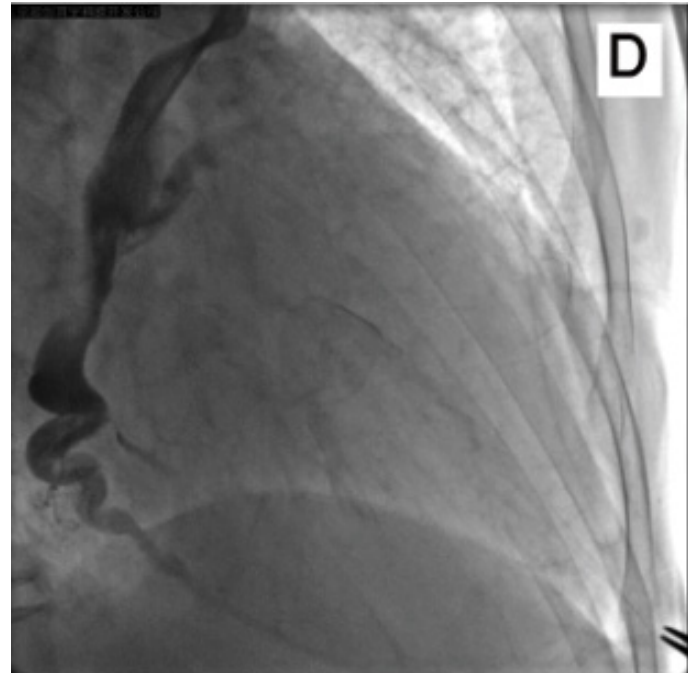
The St. Jude CPS Guiding Catheter was advanced through the right femoral vein to the SVC proximal to the bridging vein opening. 10-12 ml of contrast push revealed a well patent lumen and minimal amount of retrograde contrast flow indicating an active antegrade venous flow establishing its functional status (Figure 1C). Another JR 3.5 Fr angiocath was inserted retrogradely through the vein up to the mid-portion of coronary sinus trunk for a detailed anatomical view (Figure 1D). The GCV and the MCV were visualized with precision and another venous branch was seen draining from the postero-inferior aspect of the Left Ventricle (LV) into the MCV just before it submitted to the CS with a steep angulation. The catheter was advanced distally to achieve a detailed anatomical view of the postero-inferior branches for LV lead positioning (Figure 1E). We decided to attempt LV lead placement and the postero-inferior branch ending in to MCV was selected. A 0.014" coronary guidewire (BMW Universal II) was advanced to the proximal MCV but despite



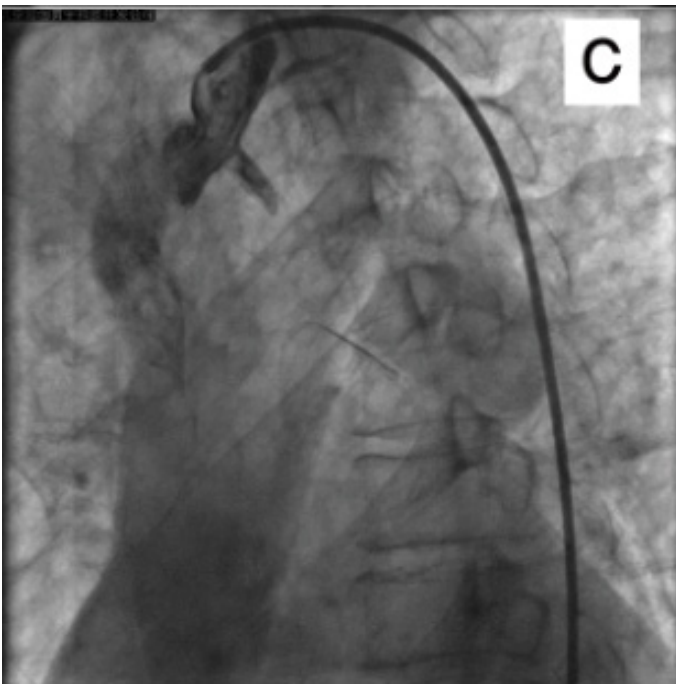
**Figure 1A.** LAO 35°-Right Atrial angiogram at the infero-medial septal wall revealing an atretic coronary ostium and absence of other anomalous openings into the CS.



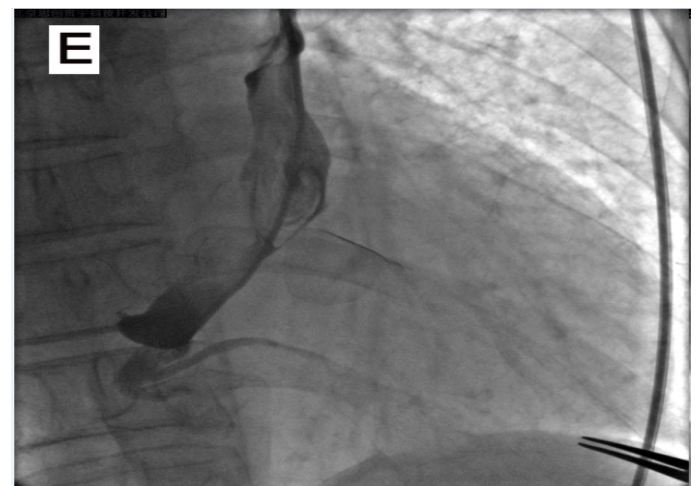
**Figure 1B.** LAO 26°-Coronary Venography revealing drainage of the coronary circulation towards the RSVC via an anomalous vein and not into the RA.



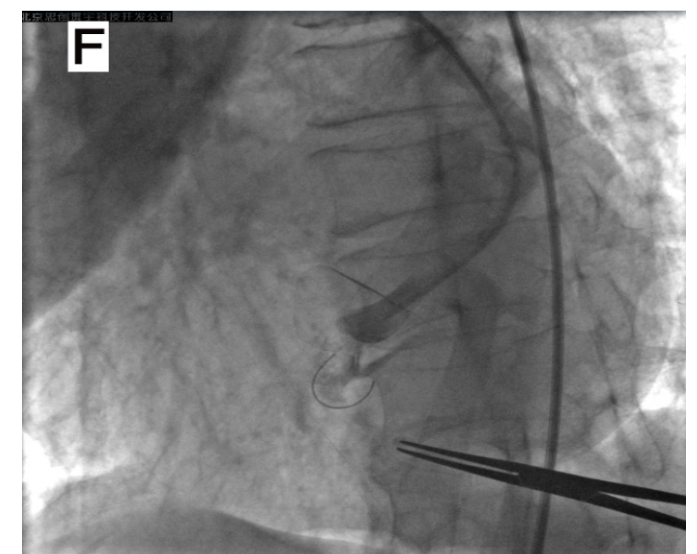
**Figure 1D.** LAO 35°-Mid-CS venograph showing the MCV, GCV and target vein.



**Figure 1C.** RAO 28°-RSVC angiography delineating the anatomy of the bridging vein.



**Figure 1E.** RAO 30°-Mid-Distal CS venograph better showing the target vein anatomy and other tributaries.



**Figure 1F.** LAO 32°-This CS venography shows the wire attempting to advance to the target vein through the sharp angle, which was unsuccessful.

several fine-tuned rotations of the distal tip, due to the steep angulations of proximal MCV, entry into the tributary was not possible (Figure 1F). Keeping in mind the possible consequences of injury to the venous luminal surface as well as possible compromised caliber to venous drainage through the vessel, the effort was called off after a generous amount of time. Our case had an anomalous cardiac venous anatomy i.e., Total atresia of the coronary sinus ostium with non-persistent left SVC with a well functional anomalous bridging vein connecting directly to the SVC. A detailed search in literature for similar cases was performed and we believe no similar cases have been yet reported, so we report our case here.

## Discussion

Technical difficulties in CRT lead implantations are reported frequently

in literature and the most frequent being challenging CS ostium cannulation. Congenital CS ostium anomalies such as ostial atresia with persistent LSVC [1,2], high RA ostium [3], ostium draining into the LA [4], absent CS [5] among others are rare encounters in interventional procedures and have been scantily reported. Mantini et al. [6] attempted to classify congenital coronary sinus anomalies as a. Enlarged coronary sinus b. Absence of coronary sinus c. Atresia of the right atrial coronary sinus ostium and d. Hypoplasia of the coronary sinus. Ostial atresia has been further classified into those draining into persistent left SVC, others communicating to the left atrium due to congenital atrial septal defect or associated with the rare Heterotaxy Syndrome [7] and a few coronary sinuses draining via multiple fenestrations into either atrium. But till date no case has been reported of a coronary sinus atresia with CS draining into the RSVC so hence the need to report this rare anomaly. Coronary sinus atresia is mostly diagnosed at autopsy [6]. Presence of a left-right shunt from the systemic circulation into the coronaries or a right-left shunt through the CS into LA might cause physiological manifestations, but absence of the shunts leads to subclinical and undiagnosed subjects [6].

Failure to identify the coronary ostium during right heart catheterization should alert an interventionalist to proceed with coronary angiography to delineate the venous drainage and hence discovery of anomalous connections if present. Apart from the reported anomalies, the possibility of CS draining into SVC should also be kept in mind. Successful placement of the pacing lead into the coronary sinus branches in patients with anomalies like persistent left SVC [8-10] requires modified interventional protocols and use of specialized tools. Whereas in a case like ours, the anomaly was hardly a matter of difficulty in achieving access to the CS trunk as favored by the bridging vessel caliber, however the angulation of the target vessel posed challenge to implantation where the venous flow after lead placement could have been compromised. We are certain that a case like ours with an otherwise well-formed coronary venous distribution presents minimal if any difficulty in lead placement.

## Conclusion

Coronary sinus atresia with non-persistent left superior vena cava associated with an anomalous bridging vein to the superior vena cava as we described here, is a rare anomaly and yet to be reported in literature. Despite the minimal impact on patient's functional status, diagnosis should be suspected in patients with failed cs cannulations. The caliber of the anomalous vessel and native coronary anatomy decides for further interventional flexibility.

## Key Clinical Message

Coronary sinus atresia is a rare event in difficult coronary sinus

catheterizations and co-existence of persistent LSVC is common. Our case had a bridging vein communicating SVC with the coronary trunk facilitating retrograde venous flow. Anomalies like these pose technical challenges in procedures requiring CS cannulation and should be kept in mind.

## References

1. Anna Polewczyk, Andrzej Kutarski, Elżbieta Czekajka-Chehab and Piotr Adamczyk, et al. "Complications of Permanent Cardiac Pacing in Patients with Persistent Left Superior Vena Cava." *Cardiol J* 21 (2014): 128-137.
2. Carlos Gonzalez-Juanatey, Ana Testa, Juan Vidan and Ricardo Izquierdo, et al. "Persistent Left Superior Vena Cava Draining into the Coronary Sinus: Report of 10 Cases and Literature Review." *Clin Cardiol* 27 (2004): 515-518.
3. Gary S. Mak, Alexander J. Hill, Florin Moisiuc and Subramaniam C. Krishnan. "Extremely abnormal location of the coronary sinus ostium." *Europace* 15 (2013): 1635.
4. Almamoon I. Justaniah, Brady Mckee, Jonathan Silver and Christoph Wald, et al. "Coronary Sinus to Left Atrium Communication." *J Radiol Case Rep* 7 (2013): 16-20.
5. Aura Sanchez Mejia, Himanshu Singh, Sanjeev Bhalla and Gautam K. Singh, et al. "Chronic Cyanosis Due to Persistent Left Superior Vena Cava Draining into the Left Atrium in the Absence of a Coronary Sinus." *Pediatr Cardiol* 34 (2013): 1514-1516.
6. Emil Mantini, Claude M. Grondin, Walton C. Lillehei and Jesse E. Edwards. "Congenital Anomalies Involving the Coronary Sinus." *Circul* 33 (1966): 317-327.
7. Christopher D. Wolla, Anthony M. Hlavacek, Joseph U. Schoepf and Andreas M. Bucher, et al. "Cardiovascular Manifestations of Heterotaxy and Related Situs Abnormalities Assessed with CT Angiography." *J Cardiovasc Comput Tomogr* 7 (2014): 408-416.
8. Rui Placido, Joao Sousa and Pedro Marques. "CRT-D Implantation Through a Persistent Left Superior Vena Cava." *Ind Pac Electrophysiol J* 14 (2014): 165-166.
9. Miguel Nobre Menezes, Ana Bernardes, João de Sousa and Pedro Marques. "Implantation of a Cardiac Resynchronization Therapy Defibrillator Through a Persistent Left Superior Vena Cava." *Rev Port Cardiol* 34 (2015): 297-298.
10. Lohendran Baskaran, Kah Ho, Wee Teo and Chi Ching, et al. "Coronary Sinus Ostial Atresia and Persistent Left-Sided Superior Vena Cava: Clinical Significance and Strategies for Cardiac Resynchronization Therapy." *Int J Angiol* 22 (2013): 199-202.

**How to cite this article:** Laxman Gyawali. "Coronary Sinus Ostium Atresia Associated with Direct Connection to the Superior Vena Cava by a Bridging Vein: A Case Report." *Clin Case Rep* 11 (2021): 1433.