

Complicated Hepatic Hydatid Cysts with Rupture into the Biliary Ducts

Gligorievski Antonio*

Department of Medicine, University Clinic of Surgery "St. Naum Ohridski" Skopje, North Macedonia

Abstract

Introduction: Liver echinococcosis is an endemic disease in the Republic of North Macedonia. The liver is the most frequent site of involvement accounts for 65-75% of cases. Rupture of a hydatid cyst into the biliary tree is the most common complication, occurring in 5-25% of patients. Aim of this research work is to present the important role of radiological imaging examinations in diagnosis of this parasitic infection, and its complications including rupture of hepatic hydatid cysts into the biliary tree.

Case presentation: We are presenting a female 68-year-old patient, with obstructive jaundice, right subcostal pain, nausea, vomiting, fatigue, and weight loss. Ultra Sound (US) and Computed Tomography (CT) examinations are performed and we found two suppurated hydatid cysts in the liver, with a diameter between 65 and 105 mm. One of them penetrated the biliary system creating a fistula. The gallbladder was chronically inflamed, filled with gallstones, and with a thickened wall. The patient underwent surgery and the hydatid cysts and gallbladder had completely removed, and the continuity of the biliary stem was established.

Conclusion: The postoperative finding completely matched the preoperative US and CT diagnosis. Cysto-biliary communication is more common in large cyst size, located in the central segments of the liver close to the biliary confluence. The postoperative finding completely matched the preoperative US and CT diagnosis.

Keywords: Hydatid cyst • Liver • Biliary ducts • Biliary fistula • Ultrasound • Computed tomography

Introduction

The echinococcosis is an endemic disease in the Republic of North Macedonia, it occurs after contact of the humans with an infected dog who is a definitive host or after using of infected food by dog's stool rich with ova from the echinococcosis. After ingestion, the eggs released from their shell, the embryo penetrates the mucosa of the duodenum and through the portal vein comes into the liver where 65-75% of the embryos stopped, and slowly transformed into a larva of the vesicular type - hydatid cyst. In the lungs, 20% of the remaining embryos are stopped, while the rest in other organs such as the kidneys, brain, bones, genitals, muscles, etc. [1]. Approximately 80% of hydatid cysts located in the right hepatic lobe [1,2].

The growth of the hydatid cyst is usually asymptomatic and very slow, and the clinical manifestation comes from the compression of involved organs. The process could act as a benign or malignant tumor, solitary or multiple metastases, abscesses, cysts, empyema, and other lesions [1]. Liver echinococcosis may have a wide variety of imaging presentations at diagnosis, simple unilocular cysts, and cysts with daughter cysts, coarse wall, or intralesional calcifications [3]. Liver echinococcosis may be associated with a wide spectrum of complications in 35% of patients [4]. Some of these complications are potentially life-threatening and, therefore, require prompt diagnosis and urgent intervention [5]. Rupture of a hydatid cyst into the biliary tree is the most common complication, occurring in 5-25% of patients [6,7]. Hepatic hydatid cyst rupture is mainly caused by the degeneration of hydatid

membranes. The causative mechanism is an increased intracystic pressure, which leads to compression and necrosis of the wall of adjacent bile ducts, followed by rupture of the biliary ducts [8,9]. Hydatid sand or daughter cysts from the hydatid cyst can be emptying into the biliary tract. Their detection is not simple, so the clinical and radiological examinations have an important role in the diagnosis of this parasitic infection. Aim of this research work is to present the important role of radiological imaging examinations in the diagnosis of this parasitic infection, and its complications including rupture of hepatic hydatid cysts into the biliary tree.

Case Report

The patient admitted to the Clinic for Abdominal Surgery with pain in the abdomen and signs for obstructive jaundice as an emergency case. The physical examination, laboratory exams, US, and CT of the abdomen is performed. From laboratory findings the direct bilirubin level was increased, anemia, and elevated erythrocytes sedimentation rate. The US examination has done on apparatus Toshiba sonolayer alfa-SSA-250A with the convex transducer of 3.75 MHz, the CT scan was done on Siemens Somatom AR. HP. with slice thickness and gap of 10 mm. The obtained findings from US and CT studies are compared with the postoperative finding. We were looking for five ultrasonographic characteristics that feature hydatid cysts: hypoechoic whirl sign; peripheral hypoechoic rim, surrounded by echoic border zone; daughter cysts, and hypoechoic zones with shadowing or distal acoustic enhancement. On ultrasound, there are two hydatid cysts with signs for pus with well-defined surrounding pericystic fibrous tissue (Figure 1). The greater cyst is located in the right lobe of the liver and it has penetrated the biliary ducts with maintained fistula and communication with the biliary ducts as well as with gallbladder. The gallbladder is with thickening and septate walls, with present gallstones and small cysts that based on the echoic features look like hydatid cysts (Figure 2). The biliary ducts are widened especially the common hepatic duct in which the daughter cysts have seen as a cause for obstructive jaundice. The parenchymal abdominal organs, retroperitoneal space, and kidneys are with no remarkable findings. There is free fluid around the liver.

Communicating rupture of hepatic hydatid cysts within the biliary tree is

*Address for Correspondence: Antonio G, Department of Medicine, University Clinic of Surgery "St. Naum Ohridski" Skopje, North Macedonia, E-mail: atglmed@gmail.com

Copyright: © 2020 Antonio G. This is an open-access article distributed under the terms of the Creative Commons Attribution License, which permits unrestricted use, distribution, and reproduction in any medium, provided the original author and source are credited.

Received 30 August 2020; Accepted 07 September 2020; Published 14 September 2020

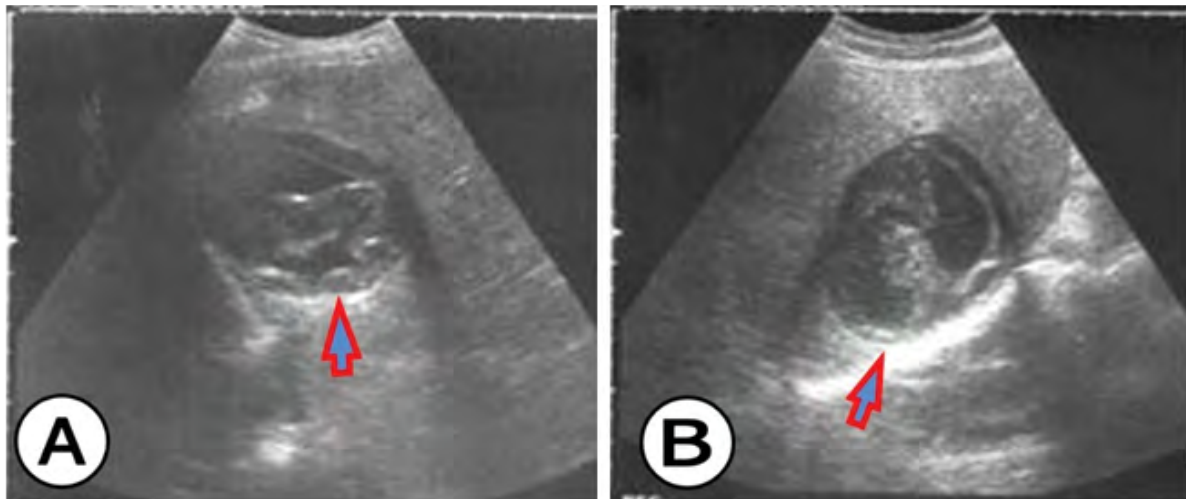


Figure 1. (A) The Ultrasound of the liver and (B) Ultrasound detection of inflamed hydatid cysts of the liver (arrow).

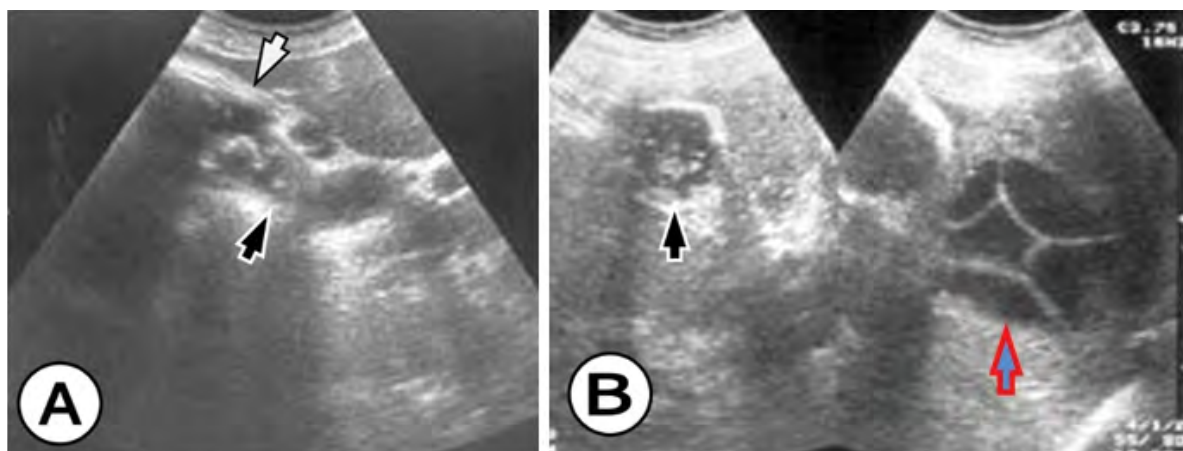


Figure 2. The US of the liver: (A) Gallbladder chronically inflamed with a thickened and stratified wall (white arrow), with calculus and with clear visualization of hydatid doter cysts (black arrow) because of the penetration of the hydatid cyst into the biliary stem with content emptying. (B) Clear visualization of hydatid doter cysts (black arrow) because of the penetration of the hydatid cyst into the biliary stem with content emptying. Multilocular hydatid cyst in the right liver lobe (red-blue arrow).

usually seen on the US as an echogenic hepatic hydatid cyst with hypoechoic or snowstorm pattern in case of perforation, rounded or linear hyperechoic structures without posterior shadowing could be detected within the common bile duct. Hydatid material into the biliary tract is evident as high attenuation content in the common bile duct on CT. The CT scan study of the abdomen performed with a conventional examination technique to confirm the US findings and to make a preoperative evaluation (Figure 3). There are two visible hydatid cysts in the liver, the first one in the right lobe and the second one in the left lobe of the liver. The cysts are inflamed with good delineation from the hepatic parenchyma with pericystic fibrous membrane or adventitia. The hydatid cyst in the right lobe of the liver has penetrated the biliary ducts and the gallbladder with present fistula (Figure 4). The biliary ducts are with an extended lumen and there are daughter cysts in the common hepatic and common bile duct that cause obstruction. The gallbladder is with a thick and septate wall, filled by gallstones and small hydatid daughter cysts. There are ascites around the liver as well as in the Douglas pouch.

An abdominal CT scan showed a cystic lesion in the right hepatic lobe, with a thickened wall, within multiple thickened septies, and also, dilation of the intrahepatic bile ducts. The patients have been operated and the hydatid cysts have been removed completely with marsupialization done. The intrabiliary lavage of the biliary content and debris of the hydatid cyst have done. Continuity of the biliary ducts, choledocho-duodenal anastomosis, and drainage of the biliary ducts through T-tube has performed. It was removed the chronically inflamed gallbladder and gallstones. Preoperative and postoperative confirmation of the radiologic finding had obtained. On the follow-up cholangiography, the radiologic finding was completely unremarkable. For postoperative follow up and for early detection of the possible complication,

the follow-up CT and US studies had performed for up to three years thereafter with unremarkable findings for any complication as well as newly developed hydatid cysts.

Discussion

In 13% there is intrabiliary penetration with a possibility for obstruction and jaundice as a physical finding [10]. Early diagnosis of the penetration of the hydatid cyst into the biliary ducts with timely and suitable surgery could save many lives. The sensitivity of the US is 92,3%, and specificity is 98,3% [11,12]. Hydatid disease remains a medical problem of great concern because of a wide spectrum of complications. The complicated hydatid cysts are often seen into the lung parenchyma while in the liver they are rare. A common complication of the hydatid cyst of the liver is its penetration into the biliary ducts [13]. The incidence of intra-biliary rupture in literature ranges from 1.0% to 25.0%, [14]. Obstructive jaundice and cholangitis are sensitive indicators of the presence of a frank cysto-biliary communication in more than 60% of the cases [10,13]. Cysto-biliary communication is a major challenge for preoperative diagnosis. Radiological findings suggesting the presence of cysto-biliary communication include deterioration of the integrity of the cyst wall and the presence of a connection between the biliary tract and the hydatid cyst with cystic material in the biliary tract [11,12]. Ruptured materials in the biliary tract appear as various anechoic or hypoechoic shapes without acoustic shadowing on the US. On Computed tomography, the materials in the intrahepatic bile ducts can appear as high-density linear structures. The loss of integrity of the cyst wall suggests cysto-biliary communication [11-13]. The US, and especially

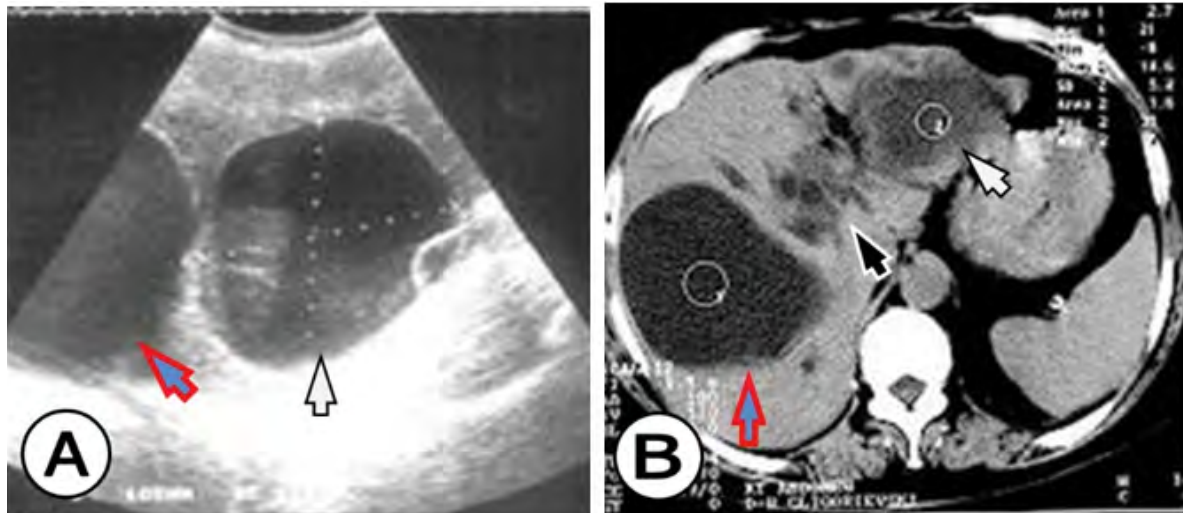


Figure 3. (A) The US of the liver visualized inflamed hydatid cysts (white arrow), (B) CT scan of the liver shows the inflamed hydatid cysts (white arrow), visualization of hydatid daughter cysts into the biliary stem (black arrow) and a hydatid cyst with a diameter of 65-105 mm (red-blue arrow). An abdominal CT scan showed a cystic lesion in the left hepatic lobe, with a thickened wall and multiple thickened septae within, and, also, dilation of the intrahepatic bile ducts.

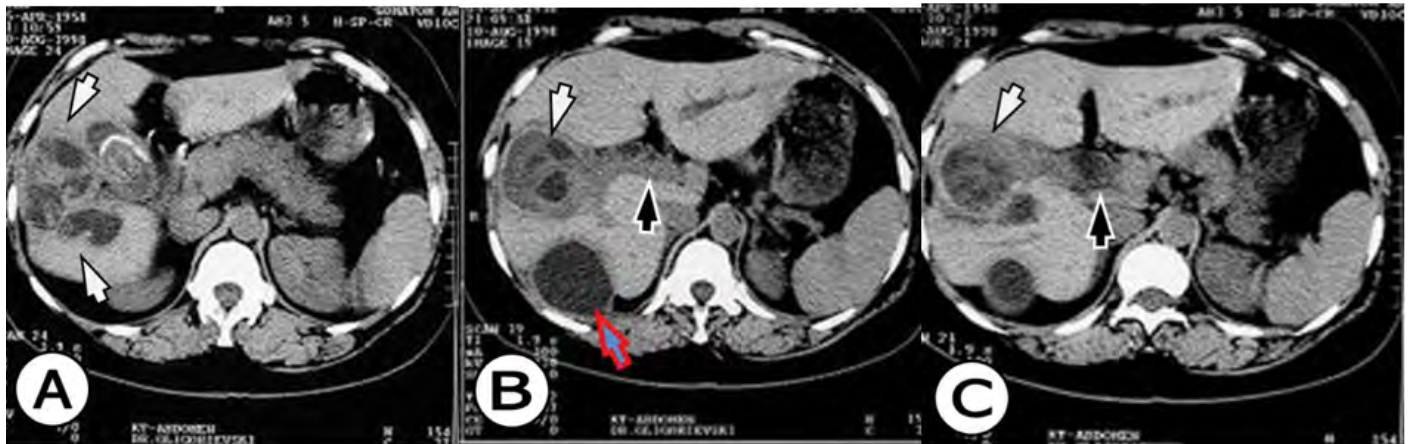


Figure 4. A couple of CT slices of the liver on different heights. (A) Clear detection of the inflamed hydatid cysts (white arrow) and chronic inflammation of the gallbladder, with big stones and hydatid daughter cysts and debris into the lumen; (B) and (C) Detection of the fistula between the hydatid cyst and the biliary ducts (black arrow). The common hepatic duct is widening with a hydatid daughter cyst into the lumen.

the CT study gives enough information for a successful diagnosis and further successful surgery. CT examination enables the excellent spatial presentation of the pathologic process, which is especially important for surgical intervention planning (approach, techniques, and procedures), which will be applying in surgical treatment.

In our practice with using the US, there is excellent detection of the hydatid cysts and their accompanied complications that allows timely diagnosis and successful surgery. The best is to perform lavage of the biliary ducts, radical treatment of the cyst, and free drainage [6-15]. Specifically, if US or CT imaging findings allow a confident diagnosis of hepatic hydatid cyst, no further test is usually needed, and patients can be treated depending on the stage of echinococcosis. The classic treatment for hydatid cysts ruptured into the bile ducts is surgery with an exploration of the common bile duct through a choledochotomy, placement of a T tube, clearance of cyst remnants and surgical excision of the hydatid cyst or cysts, either by enucleation or by pericystectomy and partial hepatectomy. However, such operations are associated with morbidity, mortality, and prolonged hospitalization.

Conclusion

We can conclude that the US and CT studies are established diagnostic methods into the preoperative diagnosis of the hydatid cysts of the liver as well as at the postoperative follow-up. It allows an excellent morphologic view of

the lesion with planning the timely and successful surgical treatment. At the same time and with high accuracy the accompanied complications have been diagnosed that allow their follow up and treatment planning. Radiological imaging methods such as CT and the US can provide a good overview of the size and location of the hydatid cyst, complications such as inflammation and rupture of the biliary stem.

References

- Johannes Eckert and Peter Deplazes. "Biological, Epidemiological, and Clinical Aspects of Echinococcosis, A Zoonosis of Increasing Concern." *Clin Microbiol Rev* 17 (2004): 107-135.
- Benedikt V. Czermak, Okan Akhan, Renate Hiemetzberger and Bettina Zelger, et al. "Echinococcosis of the Liver." *Abdom Imag* 33 (2008): 133-143.
- Sakhri, Jones. "Hydatid Cyst of the Liver." *J Chir* 6 (2004): 381-389.
- Marti-Bonmati Luci and Menor Serrano Francisco. "Complications of Hepatic Hydatid Cysts: Ultrasound, Computed Tomography, and Magnetic Resonance Diagnosis." *Gastrointest Radiol* 15 (1990): 119-125.
- Nezih Akkapulu, H Ozgur Aytac, Ilker M Arer and Murat Kus, et al. "Incidence and Risk Factors of Biliary Fistulation from a Hepatic Hydatid Cyst in Clinically Asymptomatic Patients." *Trop Doct* 48 (2008): 20-24.
- Yildirgan Min, Başoğlu Maun, Atamanalp Sas and Aydinli Bye, et al. "Intrabiliary

- Rupture in Liver Hydatid Cysts: Results of 20 Years' Experience." *Acta Chirurgica Belgica* 103 (2003): 621-625.
7. Serhat Avcu, Özkan Ünal and Rabin Arslan. "Intrabiliary Rupture of Liver Hydatid Cyst: A Case Report and Review of the Literature." *Cases J* 2 (2009): 6455.
 8. Ayman El Nakeeb, Ali Salem, Mohamed El-Sorogy and Youssef Mahdy, et al. "Cystobiliary Communication in Hepatic Hydatid Cyst: Predictors and Outcome." *Turk J Gastroenterol* 28 (2017): 125-130.
 9. José M. Ramia, Joan Figueras, Roberto de la Plaza and Jorge García-Parreño. "Cysto-biliary Communication in Liver Hydatidosis." *Langenbeck's Arch Surg* 397 (2012): 881-887.
 10. Reddy, Anuroop. "Cysto-Biliary Communication (CBC) in Hepatic Hydatidosis: Predictors, Management and Outcome." *Int Surg J* 6 (2019): 61-65.
 11. Yolanda del Valle-Sanz and Rosa M. Lorente-Ramos. "Sonographic and Computed Tomographic Demonstration of Hydatid Cysts Communicating with the Biliary Tree." *J Clin Ultrasound* 32 (2004): 144-148.
 12. Greco, Silvia. "Complications of Hepatic Echinococcosis: Multimodality Imaging Approach." *Insight Imag* 10 (2019): 13.
 13. Khalefa Ali Alghofaily, Mnahi Bin Saeedan, Ibtisam Musallam Aljohani and Mohannad Alrasheed, et al. "Hepatic Hydatid Disease Complications: Review of Imaging Findings and Clinical Implications." *Abdom Radiol* 42 (2017): 199-210.
 14. Nezih Akkapulu, Ozgur H. Aytac, Ilker M. Arer and Murat Kus, et al. "Incidence and Risk Factors of Biliary Fistulation from a Hepatic Hydatid Cyst in Clinically Asymptomatic Patients." *Trop Doc* 48 (2018): 20-24.
 15. Barış Saylam, Faruk Coşkun, Barış Demiriz and Veli Vural, et al. "A New and Simple Score for Predicting Cystobiliary Fistula in Patients with Hepatic Hydatid Cysts." *Surg* 153 (2013): 699-704.

How to cite this article: Gligorievski Antonio. "Complicated Hepatic Hydatid Cysts with Rupture into the Biliary Ducts." *Clin Case Rep* 10 (2020): 1381. DOI: 10.3742/jccr.2020.10.1381