

# Comparative Evaluation of Thyroid Imaging Reporting and Data System (TIRADS) and Cytopathological Correlation in Thyroid Nodules

Nalin Shankar Singh<sup>1\*</sup>, BA Muthanna<sup>2</sup> and Satyendra Raghuwanshi<sup>2</sup>

<sup>1</sup>Department of Pathology, Military Hospital, Hisar, Haryana, India

<sup>2</sup>Department of Radiology, Military Hospital, Jaipur, Rajasthan, India

## Abstract

**Introduction:** With the increasing availability of ultrasound and concern for malignancy, there has been significant increase in the detection of thyroid lesions. Almost all the cases of thyroid lesions are referred for ultrasound. However, there is no uniformity in the reporting pattern amongst radiologists and hence such ultrasound reports are mostly inconclusive to exclude thyroid malignancy. Therefore, most of the patients have to undergo avoidable Fine Needle Aspiration Cytology (FNAC) or Fine Needle Non-Aspiration Cytology (FNNAC). FNNAC or FNAC is invasive technique which is performed in most of the cases of thyroid nodules to ascertain the type of nodules. The sonographic assessment of thyroid nodule can provide an alternative method to this invasive modality of diagnosis. Therefore, the need was felt for establishing uniformity in ultrasound reporting of thyroid nodules and risk stratification for malignancy with aim of reducing unnecessary FNNAC. TIRADS classification brings uniformity in reporting and reduces ambiguity in management of the patients.

**Objective:** To perform comparative evaluation of Thyroid Imaging Reporting and Data System (TIRADS) and cytopathological evaluation of thyroid nodules FNNAC in Indian scenario.

**Methodology:** Multicentric prospective study was conducted in the department of radio diagnosis and department of surgery at defence service hospitals of Hisar and Jaipur during the study period of 01 July 2017 to 31 March 2018.

**Results:** Our study shows high degree of correlation between TIRADS classification and cytopathological evaluation of thyroid nodules. Hence TIRADS can be used as an effective tool for avoiding unnecessary FNNAC procedures.

**Keywords:** Tirads • Fine needle non-aspiration cytology • Thyroid nodules • Non-governmental organizations

## Introduction

The prevalence of thyroid nodules is very high amounting to nearly one third of adult population [1]. However, fortunately the incidence of neoplasia in these nodules is rare [2]. Fine Needle Aspiration Cytology (FNAC) is performed in all cases prior to surgery to assess the type of nodules. FNAC under Ultrasound Guidance (USG) is an accepted technique for obtaining better results. There are many USG features of thyroid nodules which hint towards likelihood of malignancy; however no definite criterion for malignancy has been documented.

There have been many publications attempting reliable evaluation of thyroid nodules on USG [3]. Thyroid Imaging Reporting and Data

System (TIRADS) have been proposed for categorisation of thyroid nodules on the lines of Breast Imaging Reporting and Data Systems (BIRADSR) [4]. Which popularly utilised for evaluation of breast lesions. TIRADS classifies thyroid nodules based on USG features. It aims at reduction in inter-observer variation [5]. To perform comparative evaluation of Thyroid Imaging Reporting and Data System (TIRADS) and cytopathology reporting of thyroid nodules in Indian scenario.

## Materials and Methods

This multicentric prospective study was conducted in the department of radio diagnosis, department of surgery and department of pathology and department of surgery at defence service hospitals of

\*Address for Correspondence: Nalin Shankar Singh, Department of Pathology, Military Hospital, Hisar, Haryana, India; E-mail: meetnalin@gmail.com

**Copyright:** © 2022 Singh NS, et al. This is an open-access article distributed under the terms of the creative commons attribution license which permits unrestricted use, distribution and reproduction in any medium, provided the original author and source are credited.

**Date of Submission:** 05 September 2022, Manuscript No. jch-19-2952; **Editor assigned:** 07 September 2022, PreQC No. P-2952; **Reviewed:** 19 September 2022, QC No. Q-2952; **Revised:** 23 September 2022, Manuscript No. R-2952; **Published:** 30 September 2022, DOI: 10.37421/2157-7099.22.13.652

Hisar and Jaipur during the study period of 01 July 2017 to 31 March 2018. Only patients with age of 18 years or more were included in the study. Clearance was obtained from hospital ethical committee. The patients who were suspected to have thyroid nodules were evaluated clinically by qualified surgeons and referred for necessary investigations. 230 patients reported to the department of radio diagnosis for ultrasound evaluation and USG guided FNNAC of thyroid nodules with suspicion of thyroid nodules. Subsequently ultrasound was done for all the patients using Wipro GE Logiq P3 colour doppler ultrasound machine (General Electronics, GE) and Wipro GE Logiq F8 expert ultrasound machine at Jaipur and Hisar

centres respectively. The nodules were categorised as per TIRADS category as given by American College of Radiology (ACR) in 2017.

Only 202 of these 230 patients were underwent FNNAC. Other patients refused to give consent for the procedure or were lost to follow up. USG guided FNNAC was done for 208 nodules in these 202 patients. Therefore the sample size was taken to be 208. Two slides for each sample were prepared and sent to pathology lab for pathologist evaluation and reporting. This prospective study included all consecutive patients reporting for ultrasound and FNNAC of nodules to the hospital (Tables 1-3) [6].

**Table 1.** TIRADS system for evaluation of thyroid nodules.

TIRADS	Definition	USG features	Risk of malignancy
1	Negative	Normal thyroid	Nil
2	Benign	Benign features	Nil
3	Probably benign	Without suspicious features	<5% malignancy
4	Low suspicion	One suspicion feature	5%-10%
5	Intermediate suspicion	Two suspicion features	11%-80%
6	Moderate suspicion	Three or four suspicion feature	44.4%-72.4%
7	High suspicion	Five suspicion features	>80%
8	Known proved malignancy	Confirmed malignancy	Biopsy proven malignancy

**Table 2.** Based on the ACR TIRADS system a simplified reporting format was devised to streamline reporting of thyroid nodules based on their characteristics.

Criteria	Categories	Points
Composition	Cystic or almost completely cystic	0
	Spongiform	0
	Mixed solid and cystic	1
	Solid or almost completely solid	2
Echogenicity	Anechoic	0
	Hyperechoic or isoechoic	1
	Hypoechoic	2
	Very hypoechoic	3
Shape	Wider-than-tall	0
	Taller-than-wide	3
Margin	Smooth: 0 points	0
	Ill-defined: 0 points	0
	Lobulated/irregular	2
	Extrathyroidal extension	3
Echogenic foci	None	0
	Large comet tail artefacts	0
	Macrocalcifications	1
	Peripheral/rim calcifications	2
	Punctate echogenic foci	3

**Table 3.** Summarises the various management recommendations based on the TIRADS score.

Category	Points	Suspicion	Recommendation
TIRADS 1	0	Benign	No FNAC
TIRADS 2	2	Not suspicious	No FNAC
TIRADS 3	3	Mildly suspicious	If >2.5 cm: FNA If >1.5 cm: Follow up at 1,3 ,5 years
TIRADS 4	4-7	Moderately suspicious	If >1.5 cm: FNA If >1 cm: Follow up at 1,3 ,5 years
TIRADS 5	7 or more	Highly suspicious	If >1 cm: FNA If >0.5 cm follow annually for 5 years

**USG technique**

Grey scale sonography using a linear 7.5 MHz-12 MHz probe was performed by the radiologists. Colour Doppler mode was also employed wherever felt necessary. The images were analysed on real time basis using both B mode and colour Doppler. Representative images were saved in Digital Imaging and Communications in Medicine (DICOM) format in the USG machine [7].

The scan area involved both the lobes and isthmus with the patient in supine position with neck in hyperextended position. The neck region was also evaluated to look for cervical lymphadenopathy [8].

Features of image zoom, colour doppler were utilised wherever felt necessary. Thyroid lesions were evaluated for size, shape, internal contents, echogenicity, margins, calcific foci, mural nodules and septations. In patients with more than one nodule, all the nodules were evaluated and USG findings were documented. Internal contents of the lesions were categorized as solid, cystic or mixed [9].

FNNAC Technique-Fine Needle Non-Aspiration Cytology was performed by trained radiologists under USG guidance using 24 Gauge (24 G) needle along with a 10 mL syringe. All these procedures were performed after written informed consent. A pathologist was present during all these procedures to evaluate the samples for quality and adequacy and to make the slides [10].

The patient was made to lie down supine in hyperextended position. Aseptic precautions were achieved by cleaning the region of interest with Betadine solution and allowing contact period of 5 minutes. Thereafter the region was cleaned with sterilium solution using a gauze piece. A prepacked sterile gel was utilised for acoustic gel. The linear transducer probe was kept vertical. The needle was introduced at an angle perpendicular to the skin and the probe in the plane of the ultrasound probe. The tip of the needle was always kept in the plane of scan on real-time basis [11].

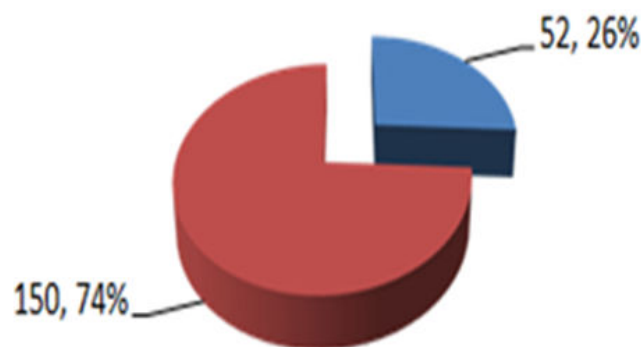
A 24 Gauge needle with non-cutting and bevelled edge was utilized. Non aspiration technique was utilised. The needle was manoeuvred to obtain samples from the predominantly solid areas.

Sample thus obtained was handed over to the pathologist was making slides and ascertaining adequacy of the samples. On average two specimen slides were made for each nodule [12].

USG findings were classified in TIRADS and FNNAC were reported by pathologist. Results were analysed and compared statistically using Statistical analysis was carried out using Statistical Package for Social Sciences (SPSS) for Microsoft Windows 7. ODDS ratio were calculated and P value <0.05 was considered significant.

**Results**

Out of the 202 patients included in the study. 52 of the total patients were male (25.74%) and 150 were female (74%-25%). Gender distribution is shown in Figure 1. 191 of the total patients were less than forty years of age. The youngest patient was 18 years of age and the oldest was 50 years of age. A total of 208 thyroid nodules were evaluated by both USG and FNAC. One patient had 4 nodules, two patients had three nodules and six patients were detected to have two nodules. Demographic distribution of the patients is given in Figure 1 and Table 4 [13].



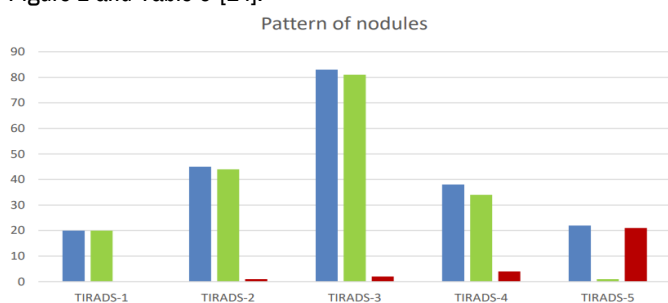
**Figure 1.** Gender distribution of study population.

**Note:** ■ -Male ■ -Female.

**Table 4.** Showing demographic distribution of the study population.

Age group	Number of patients	Percentage
Less than 10 years	Nil	0
18-20	9	0.0445
21-30	32	0.1584
31-40	150	0.7425
41-50	11	0.0545
51 and above	Nil	0

The thyroid nodules in our study were ranging from 3 mm to 47 mm. Figure 2 depicts the various types of nodules seen in the study Figure 2 and Table 5 [14].

**Figure 2.** Showing comparison between USG TIRADS category and FNNAC reports.

**Note:** ■ -Total ■ -Benign ■ -Malignant.

**Table 5.** Shows comparison and correlation between USG TIRADS category and FNNAC reports.

TIRADS classification	Number of nodules	Benign on FNAC	Malignant on FNAC	OR (95% CI)	P-value
TIRADS-1	20	20 (100%)	0 (0%)	7.28 (0.428-123.81)	0.169
TIRADS-2	45	44 (97.7%)	1 (2.3%)	8.23 (1.153-66.16)	0.035
TIRADS-3	83	81 (97.5%)	2 (2.5%)	10.636 (2.450-46.164)	0.0016
TIRADS-4 (4A+4B+4C)	38	34 (89.5%)	4 (11.5%)	0.2774 (0.1086-0.7089)	0.007
TIRADS-5	22	1 (4.5%)	21 (95.5%)	0.0259 (0.0086-0.781)	<0.001
TOTAL	208	180(86.5%)	28 (13.5%)	-	-

Out of the 208 nodules, 28 (13.5%) turned out to be malignant. The percentage of malignant thyroid nodules was higher in nodules with TIRADS score 4 and 5. The percentage of malignant thyroid nodules was 1% and 2% respectively for TIRADS 2 and 3 category. Most common finding of USG evaluation was diffuse thyroiditis. There was significant correlation between the USG findings and FNNAC findings in TIRADS scoring system.

## Discussion

With the increasing availability of ultrasound and concern for malignancy, there has been significant increase in the detection of thyroid lesions. Almost all the cases of thyroid lesions are referred for ultrasound.

However, there is no uniformity in the reporting pattern amongst radiologists and hence such ultrasound reports are mostly inconclusive to exclude thyroid malignancy.

Therefore, most of the patients have to undergo avoidable Fine Needle Aspiration Cytology (FNAC) or Fine Needle Non-Aspiration Cytology (FNNAC)[15].

The need was felt for establishing uniformity in ultrasound reporting of thyroid nodules and risk stratification for malignancy with aim of reducing unnecessary biopsies.

HPE through FNNAC or FNAC is invasive technique and there is felt need for alternative to invasive modalities [16].

Currently, there is a felt need to standardize the reporting pattern for various organs like breast, liver, prostate and thyroid which has led to the development of BIRADS, LIRADS, PIRADS and TIRADS.

In a study by an initial classification was proposed for reporting of thyroid nodules which included increasing risk of malignancy with increasing score [17]. American College of Radiology proposed TIRADS scoring system which provides objective method of assessing thyroid nodules based on their characteristics, stratifies risk and provides treatment guidelines.

Our study shows significant correlation of higher TIRADS score with histopathological findings. Similar results were seen studies of Antonio.

In our study the female patients constituted about 74% of the total patients which is consistent with high incidence of thyroid nodules in females. Most of the patients were 30-40 years old. Similar findings were also reported by a study.

The likelihood of malignancy in TIRADS scoring increases with the TIRADS category. Also, TIRADS provides the recommendation of whether to go ahead with FNNAC or not although FNNAC is being recommended in most of the cases of thyroid nodule, is an invasive procedure. With the use of TIRADS scoring system the number of avoidable FNACs can be reduced. Since thyroid malignancies are slow growing lesions, a long term follow up is often required. TIRADS also provides management guidelines for thyroid lesions which includes follow up or FNAC.

## Conclusion

Thyroid nodules are very common and is having increasingly high incidence. FNAC or FNNAC is most often carried out for thyroid nodules. Such investigation not only is invasive but also needs repetition in many patients. Ultrasound is a non-invasive, inexpensive and serve as available alternative to FNNAC. However, before introduction of TIRADS, there was lack of uniformity and reproducibility for thyroid nodules. Use of TIRADS is an effective tool in reducing avoidable invasive procedures. TIRADS classification brings uniformity in reporting and reduces ambiguity in management of the patients. Our study shows high degree of correlation between TIRADS classification and HPE diagnosis. TIRADS can be used an effective tool for avoiding unnecessary invasive procedures.

## References

1. Tan, Gerry H, and Hossein Gharib. "Thyroid incidentalomas: Management approaches to nonpalpable nodules discovered incidentally on thyroid imaging." *Ann Inter Med* 126 (1997): 226-231.
2. Ezzat, Shereen, Dennis A Sarti, Delver R Cain, and Glenn D Braunstein. "Thyroid incidentalomas: prevalence by palpation and ultrasonography." *Arch Int Med* 154 (1994): 1838-1840.
3. Papini, Enrico, Rinaldo Guglielmi, Antonio Bianchini, and Anna Crescenzi. "Risk of malignancy in nonpalpable thyroid nodules: Predictive value of ultrasound and color-doppler features." *J Clin Endocrinol Metabol* 87 (2002): 1941-1946.
4. Koike, Eisuke, Shiro Noguchi, Hiroyuki Yamashita, and Tsukasa Murakami. "Ultrasonographic characteristics of thyroid nodules: Prediction of malignancy." *Arch Surg* 136 (2001): 334-337.
5. Kim, Eun Kyung, Soo Park Cheong, Youn Chung Woung, and Keun Oh Ki. "New Sonographic Criteria for Recommending Fine-Needle Aspiration Biopsy of Nonpalpable Solid Nodules of the Thyroid." *Am J Roentgenol* 178 (2002): 687-691.
6. Nam-Goong Il, Seong, Ha Young Kim, Gyungyub Gong, and Ho Kyu Lee. "Ultrasonography-Guided Fine-Needle Aspiration of Thyroid Incidentaloma: Correlation with Pathological Findings." *Clin Endocrinol* 60 (2004): 21-28.
7. Stavros A, Thomas, David Thickman, Cynthia L Rapp, and Mark A. Dennis. "Solid Breast Nodules: Use of Sonography to Distinguish Between Benign and Malignant Lesions." *Radiology* 196 (1995): 123-134.
8. Fernandez Sánchez. "TI-RADS Classification of Thyroid Nodules Based on a Score Modified Regarding the Ultrasound Criteria for Malignancy." *Argentine J Radiol* 78 (2014): 138-148.
9. Paschke, Ralf, Laszlo Hegedüs, Erik Alexander, and Roberto Valcavi. "Thyroid Nodule Guidelines: Agreement, Disagreement and Need for Future Research." *Nat Rev Endocrinol* 7 (2011): 354-361.
10. Pacini, Furio, Martin Schlumberger, Henning Dralle, and Rossella Elisei. "European Consensus for the Management of Patients with Differentiated Thyroid Carcinoma of the Follicular Epithelium." *Eur J Endocrinol* 154 (2006): 787-803.
11. Weinreb, Jeffrey C, Jelle O Barentsz, Peter L Choyke, and Francois Cornud. "PI-RADS Prostate Imaging-Reporting and Data System." *Eur Urol* 69 (2016): 16-40.
12. Kwak, Jin Young, Kyung Hwa Han, Jung Hyun Yoon, and Hee Jung Moon. "Thyroid Imaging Reporting and Data System for US Features of Nodules: A Step in Establishing Better Stratification of Cancer Risk." *Radiology* (2011): 892-899.
13. Moifo, Boniface, Emmanuel Oben Takoeta, Joshua Tambe, and Joseph Gonsu Fotsin. "Reliability of Thyroid Imaging Reporting and Data System (TIRADS) Classification in Differentiating Benign from Malignant Thyroid Nodules." *Open J Radiol* 3 (2013): 103.
14. Horvath, Eleonora, Sergio Majlis, Ricardo Rossi and Carmen Franco. "An Ultrasonogram Reporting System for Thyroid Nodules Stratifying Cancer Risk for Clinical Management." *J Clin Endocrinol Metabol* 94 (2009): 1748-1751.
15. Rahal Junior, Antonio, Priscila Mina Falsarella, Rafael Dahmer Rocha, and João Paulo Bacellar Costa Lima. "Correlation of Thyroid Imaging Reporting and Data System and fine needle aspiration: Experience in 1,000 nodules." *Einstein* 14 (2016): 119-123.
16. Naren Satya, Srinivas M, VN Amogh, Munnangi Satya Gautam, and Ivvala Sai Prathyusha. "A prospective study to evaluate the reliability of thyroid imaging reporting and data system in differentiation between benign and malignant thyroid lesions." *J Clin Imag Sci* 6 (2016).
17. Gharib, Hossein, and Enrico Papini. "Thyroid Nodules: Clinical Importance, Assessment and Treatment." *Endocrinol Metabol Clin North Am* 36 (2007): 707-735.

**How to cite this article:** Singh, Nalin Shankar, BA Muthanna and Satyendra Raghuvanshi. "Comparative Evaluation of Thyroid Imaging Reporting and Data System (TIRADS) and Cytopathological Correlation in Thyroid Nodules." *J Cytol Histol* 13 (2022) : 652.