

Case Based Discussion: Hantavirus Infection Presenting as Pulmonary Syndrome in an Immunocompetent Adult Male

Pradeep Kumar Vyas*, Vidyadhara Lakkappan, Rajesh Uchil, Suhas Thorat and Vijay Khatri

Department of Critical Care Medicine, Holy Family Hospital, St. Andrews Road, Bandra (West), Mumbai, India

Abstract

Hantaviruses are rodent-borne virus infection manifested as haemorrhagic fever with renal syndrome and hantavirus cardiopulmonary syndrome. HCPS is a severe, fatal, respiratory disease caused by infection with hanta viruses. Anyone who comes in contact with rodents that carry hanta-viruses is at risk of HCPS. Rodent infestation in and around the home remains the primary risk for hanta-virus exposure. Clinical presentation of hanta-virus infections is not very much clear, sero-conversion and rising anti-hantavirus IgG titers were taken as evidence. Here we present a case of a 46-year-old male diagnosed to have hanta virus pulmonary syndrome treated successfully.

Keywords: Hanta virus; HFRS; HPS; HCPS; ARDS; Haemorrhagic fever

Introduction

Hantavirus are members of bunyavirus family. This group was first identified as causing hemorrhagic fevers with renal failure. Hantavirus pulmonary syndrome became more prominent when it was first described in USA [1].

Epidemiology

Hantavirus spread from mammals to mammals by exposure to aerolized faeces, infected urine or other body secretions. It has been found in rodents and other species in the world. Hemorrhagic fever with renal failure is the most common presentation of hanta-virus. In USA the most notifiable hantavirus is Sin-Nombre virus which is associated with severe pulmonary syndrome, found in 10-80% of deer mice mostly in rural regions. Spread is from rodents to humans through contact with rodent habitat.

Microbiology

Hantavirus is spherical particles 80-120 nm in diameter has an envelope contains two glycoproteins which encloses three nucleocapsids. These nucleocapsids consists three separate strands of RNA, RNA dependent RNA polymerase and two non-structural proteins.

Pathogenesis

In HFRS and HCPS the primary lesion is leakage of plasma and erythrocytes through the vascular endothelium. In HFRS the kidneys are affected with hemorrhagic necrosis, while in HCPS the lungs are affected.

Clinical findings

HPS starts with a prodrome of fever, headache, myalgia, and gastrointestinal symptoms lasted for 4-5 days, followed by cough and dyspnea associated with tachycardia, tachypnea and hypotension. The respiratory symptoms may progress to ARDS and respiratory failure. HPS should be suspected in young healthy subjects who presents with fever, ARDS and history of exposure to rodents.

Laboratory investigations

There are no specific laboratory finding in HPS, but hemoconcentration, leukocytosis with left shift, abnormal or raised

lymphocytes, thrombocytopenia, prolonged PTT in more severe cases and progressive worsening of lung function.

Radiology

Diffuse bilateral interstitial pulmonary infiltrates present in HPS.

Differential diagnosis

Acute severe pneumonia of various etiology must be differentiated specially Influenza-A virus, Legionella spp, *Chlamydia pneumoniae* or *Pneumocystis jerevecci* have similar presentation but the epidemiology, age and other factors can provide clue to the diagnosis. Cardiopulmonary oedema ARDS caused by other etiology, are other differential diagnosis.

Complications

Acute respiratory failure and severe lung impairment of lung function and pulmonary disability.

Diagnosis

Serology-IgM specific assays are the main method to diagnose active infection. Sero-conversion or a fourfold increase in IgG antibody is useful for recent infection.

Treatment

There is no specific treatment but Ribavirin has been used to treat HPS but its efficacy is not established. Supportive therapy for ARDS is essential for survival. Immunotherapy has shown that administration of human neutralizing antibodies during acute phases of Hantavirus might prove effective. A strong neutralizing antibody could effectively reduce the presence of the virus as well as promote recovery. However,

***Corresponding authors:** Pradeep Kumar Vyas, Holy Family Hospital St. Andrews Road, Bandra (West) Mumbai 91400050, India, Tel: 09920696710; E-mail: drvvaspradeep@gmail.com

Received November 15, 2019; **Accepted** December 24, 2019; **Published** December 30, 2019

Citation: Vyas PK, Lakkappan V, Uchil R, Thorat S, Khatri V (2020) Case Based Discussion: Hantavirus Infection Presenting as Pulmonary Syndrome in an Immunocompetent Adult Male. J Infect Dis Med 5: 139.

Copyright: © 2020 Vyas PK, et al. This is an open-access article distributed under the terms of the Creative Commons Attribution License, which permits unrestricted use, distribution, and reproduction in any medium, provided the original author and source are credited.

no published reports of controlled clinical trials except for studies done on mice, hamsters, and rats have been shown.

Prognosis

Poor prognosis i.e., 30-50% mortality.

Prevention and control

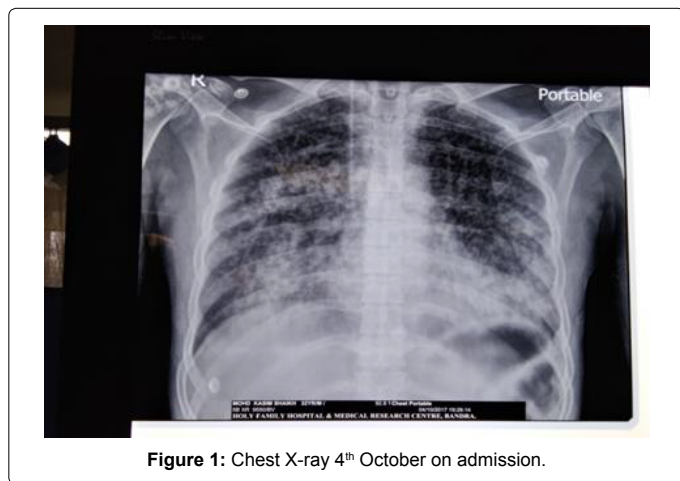
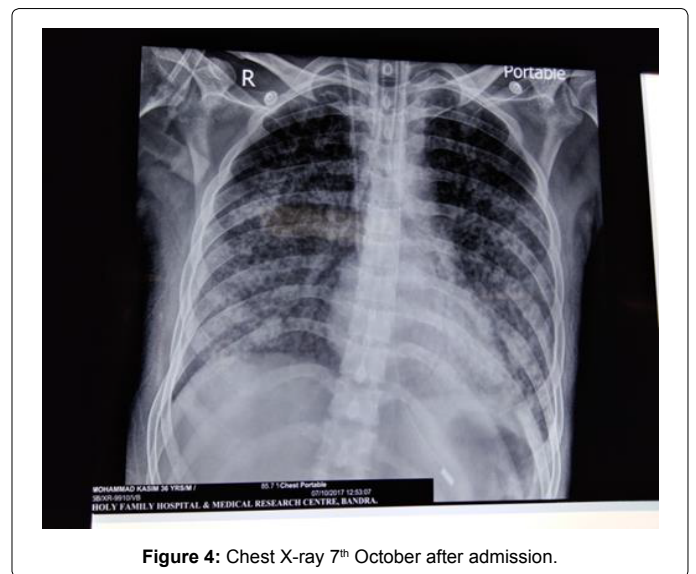
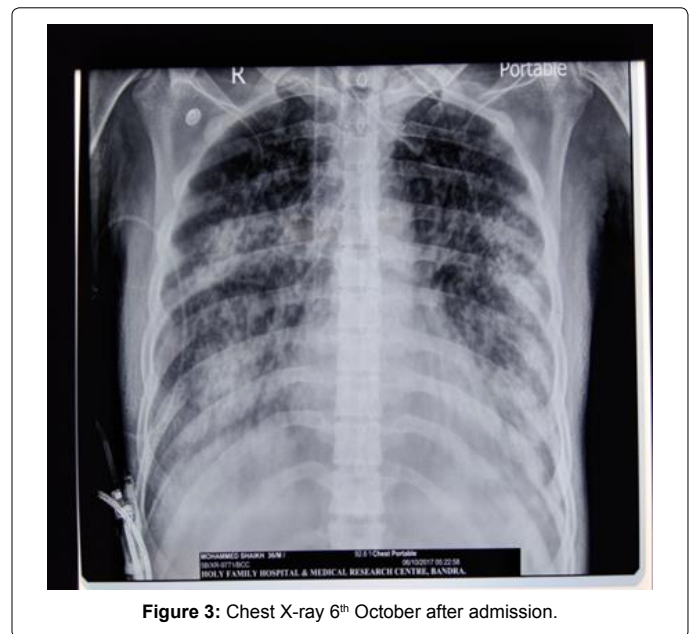
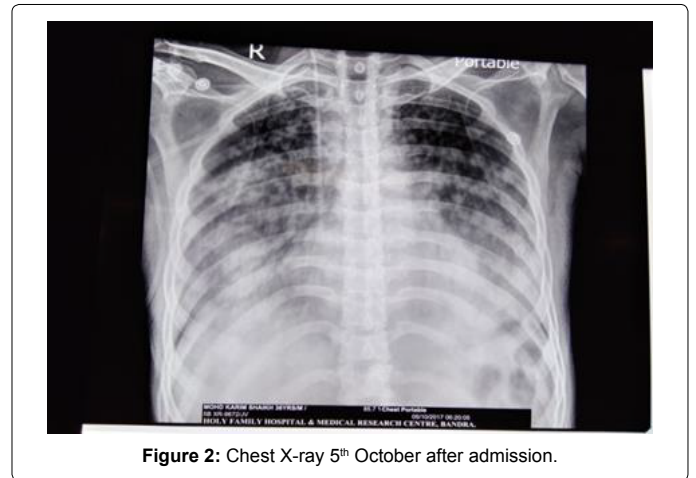
The disease is prevented by interrupting contact between humans and rodents. Rodent control also decreases transmission.

Vaccine

There is no commercially available vaccine that is effective for hantavirus. A vaccine known as Hantavax has been under study since 1990. As of 2016, the development is in clinical phase 3 trial stage.

Case History

A 34-year-old male non-smoker presented with history of fever cough, breathlessness for 2 days. He was conscious, dehydrated, febrile, tachycardic, tachypnea, icteric, and pale. Respiratory examination revealed bilateral crackles and scattered wheez, with hepatosplenomegaly and oligurea, no bleeding escher. No exposure history or contact with rodents. Investigations revealed normal haemogram with mildly raised liver enzymes, serum bilirubin and serum creatinine. X-chest shows bilateral infiltration (Figure 1). ABG suggestive of mild hypoxaemia. Meropenem and Clarithromycin, with other symptomatic treatment started. Next day he had worsening breathlessness requiring NIV support. His routine investigations show gradually increasing trend of WBC, low hemoglobin and platelets. Widal dengue NS1, IgM, malaria, H1N1 and Leptospira IgM were negative. HBsAg, HCV, HIV1 and 2 were non-reactive. Hantavirus IgM and IgG both were positive. X-ray chest shows worsening infiltration (Figures 2-4). Next day early morning patient had episode of haemoptysis, in view of respiratory distress and hypoxemia. He was intubated and put on mechanical ventilatory and inotropic support. X-ray chest (Figure 5 and Figure 6) showing worsening infiltrates. ET secretion culture were positive for *Klebsiella pneumoniae* resistant to Clarithromycin and Meropenem therefore antibiotics escalated to Colistin and Levofloxacin. Patient gradually improved so on 7th day inotropic support was stopped. Subsequently WBC and creatinine level came to normal, X-ray chest improved, so patient extubated on 10th day in view of hemodynamic stability and satisfactory ABG (Figures 7-10).



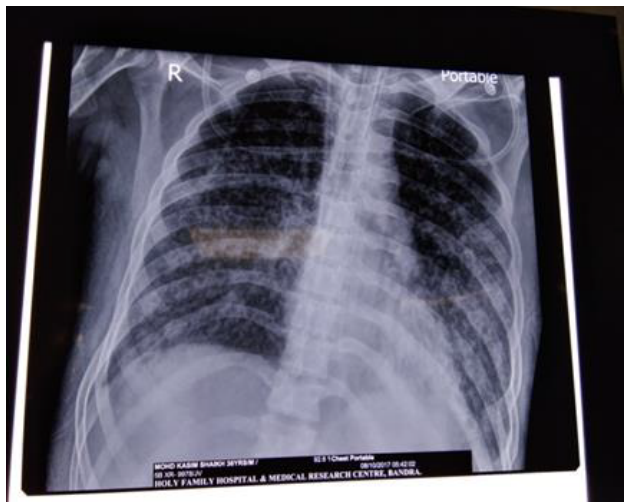


Figure 5: Chest X-ray 8th October after admission.

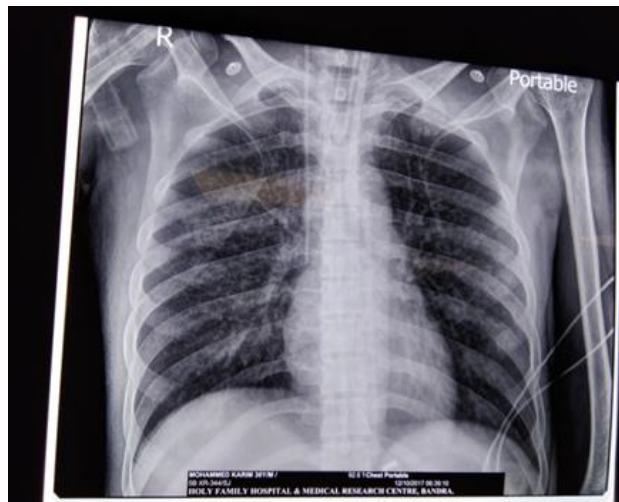


Figure 8: Chest X-ray 12th October after admission.

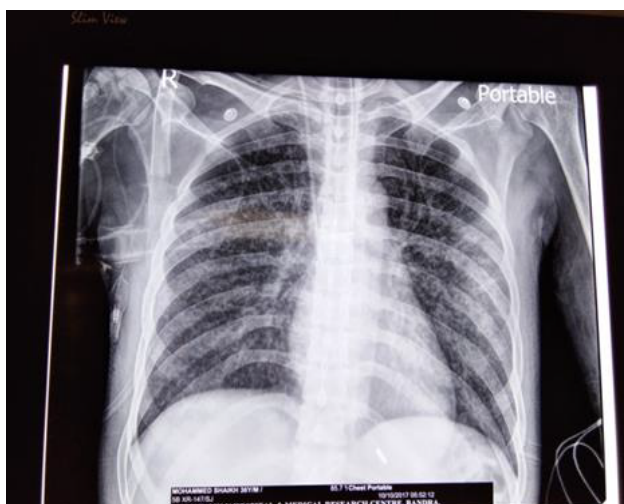


Figure 6: Chest X-ray 10th October after admission.

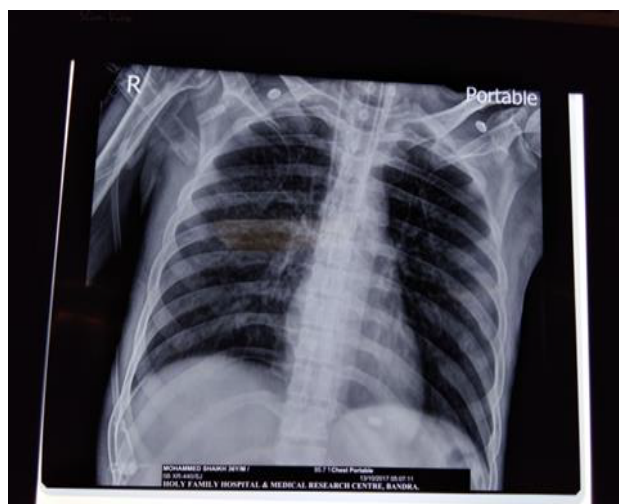


Figure 9: Chest X-ray 13th October after admission.

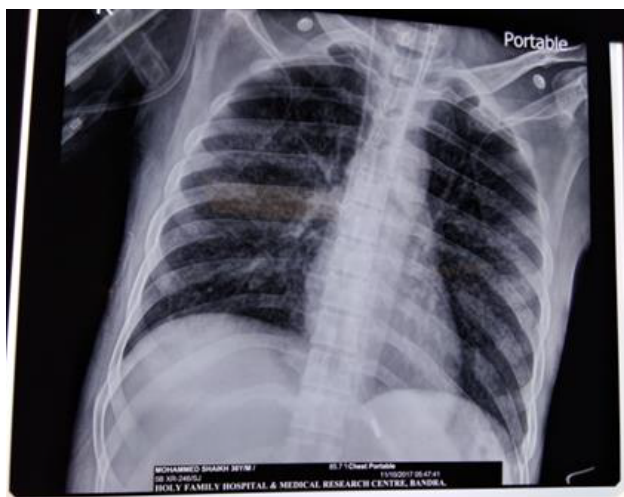


Figure 7: Chest X-ray 11th October after admission.

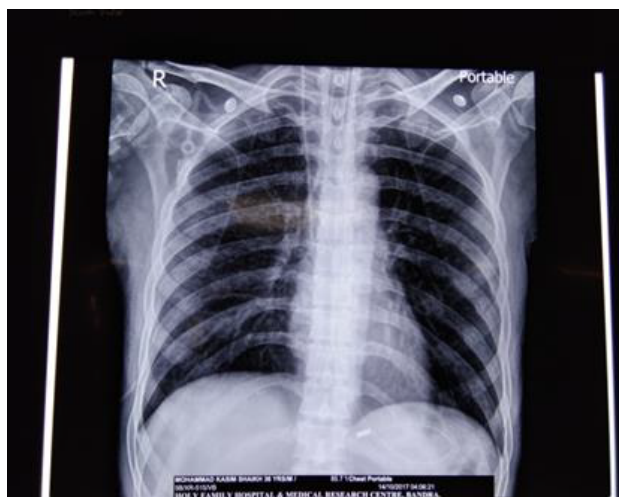


Figure 10: Chest X-ray 14th October after admission.

	04-Oct	05-Oct	06-Oct	07-Oct	08-Oct	09-Oct	10-Oct	11-Oct	12-Oct	13-Oct
HB	8.6	9.1	7.1	9.9	9	8.4	9	8.6	9	8.6
WBC	6690	13560	11530	30240	39060	26450	24630	18030	19180	24690
PLT	50K	46K	120K	178K	185K	250K	333K	386K	496K	506K
BUN	-	-	-	-	-	-	-	-	-	-
CREAT	1.5	1.3	1	0.8	0.8	0.4	0.5		0.4	0.4
SGOT	-	-	-	-	-	-	-	-	-	-
SGPT	-	-	-	-	-	-	-	-	-	-
DENGUE	-VE	-	-	-	-	-	-	-	-	-
NS1/IgG/	-	-	-	-	-	-	-	-	-	-
IgM	-	-	-	-	-	-	-	-	-	-
LEPTOSPIRA IgG/IgM	-VE	-	-	-	-	-	-	-	-	-
H1N1	-VE	-	-	-	-	-	-	-	-	-
HANTA IgG/ Ig M	+VE	-	-	-	-	-	-	-	-	-

Table 1: Blood picture on admission till the recovery.

Discussion

HPS is a rare pulmonary syndrome with a 30-50% fatality [2]. It results from inhalation of aerosolized viral particles causing infection of endothelial cells, resulting in capillary leakage, which in turn leads to the clinical features and laboratory abnormalities [2-8]. Incubation period is 4-33 days. There is an early phase of fever with symptoms like headache, nausea, anorexia, diarrhoea, abdominal pain, and malaise [1] and a late or cardio-pulmonary phase with breathlessness leading to respiratory distress and failure, diffuse bilateral pulmonary infiltrates, hypoxia, hemodynamic instability, and shock, which can worsen over 24 to 48 hours. The diagnosis of HPS suspected on the symptoms, history of contact with rodents or exposure to areas where rodents live, lack of an alternative diagnosis, and/or laboratory tests that show characteristic changes. Immediate aggressive management required due to rapid progression [8].

Blood examinations

Blood examinations reveal hemoconcentration, raised and abnormally enlarged WBC (atypical lymphocytes), absence of myeloid toxic changes, increased immunoblasts on smear and thrombocytopenia. Hepatic transaminase values mildly elevated, but serum LDH is markedly increased. A mild elevation of the activated partial thromboplastin time with a normal level of fibrinogen. Disseminated intravascular coagulation develops when the concentration of fibrinogen begins to fall. The development of lactic acidosis, combined with rapid respiratory deterioration, usually indicates death within 1-2 days. The diagnosis of HPS is confirmed when laboratory tests reveal the presence and/or increased level of Hantavirus IgM and/or a rising IgG titer (Table 1) [9-12].

Imaging studies

The chest radiograph typically shows a pattern of non-cardiac pulmonary edema, cardiac silhouette is not enlarged, perihilar haziness (shaggy heart sign) is characteristic. Virtually all patients have interstitial edema, which manifests radiologically as peribronchial cuffing or Kerley B lines. Pleural effusions are common. The case under discussion presented following an incubation period of 4-5 days, with fever and typical laboratory and radiological abnormalities which progressed to hypoxic respiratory failure requiring cardio-respiratory and inotropic support. Patient improved symptomatically and radiologically after active management in ICU with appropriate antibiotics fluids,

ventilator and other supportive treatment. Conclusion: The emerging viral disease HFRS and HCPS are a cause of global concern. Humans are accidental hosts and get infected by aerosols generated from contaminated urine, faeces and saliva of infected rodents. Flu-like signs and symptoms in its early stages, which is difficult to distinguish from influenza, pneumonia or other viral infections. After 4 to 10 days more serious signs and symptoms appear with cardio-respiratory collapse, which is life-threatening. Serological investigation of patients with pyrexia revealed presence of anti-hantavirus IgM Antibodies The case under discussion presents typical signs and symptoms of hantavirus infection confirmed serologically and treated successfully.

Conflict of Interest

None to declare.

Acknowledgement

Our sincere thanks to Executive Director Sister Lucin. Ex Medical Director Dr. Armeeda Fernades, Medical Director Dr. Ntraj Uttamani, Asst. executive Director Dr.(Sister) Beena, Medical Suptd. Dr. M. Methias. ICU "B" wing staff and Radiology department for the kind help provided in preparing this manuscript.

References

- Carey DE, Reuben R, Panicker KN, Shope RE, Myers RM (1971) Thottapalayam virus: A presumptive arbovirus isolated from a shrew in India. Indian J Med Res 59: 1758-1760.
- Chandy S, Yoshimatsu K, Boorugu HK, Chrispal A, Thomas K, et al. (2009) Acute febrile illness caused by hantavirus: Serological and molecular evidence from India. Trans R Soc Trop Med Hyg 103: 407-412.
- Peters CJ, Simpson GL, Levy H (1999) Spectrum of hantavirus infection: Hemorrhagic fever with renal syndrome and hantavirus pulmonary syndrome. Annu Rev Med 50:531-545.
- Chandy S, Yoshimatsu K, Ulrich RG, Mertens M, Okumura M, Rajendran P, et al (2008) Sero-epidemiological study on hantavirus infections in India. Trans R Soc Trop Med Hyg 102:70-74.
- Duchin JS, Koster FT, Peters CJ, Simpson GL, Tempest B, Zaki S et al. (1994) Hantavirus pulmonary syndrome: a clinical description of 17 patients with a newly recognized disease. N England J Med 330:949-955.
- Hepojoki J, Vaheri A, Strandin T (2014) The fundamental role of endothelial cells in hantavirus pathogenesis. Front Microbiol 5: 727.
- Steinberg BE, Goldenberg NM, Lee WL (2012) Do viral infections mimic bacterial sepsis? The role of microvascular permeability: a review of mechanisms and methods. Antiviral Res 93: 2-15.
- Dvorscak L, Czuchlewski DR (2014) Successful triage of suspected hantavirus cardiopulmonary syndrome by peripheral blood smear review-a decade of experience in an endemic region. Am J Clin Pathol 142: 196-201.

9. Jonsson CB, Figueiredo TM, Vapalahti O (2010) A global perspective on hantavirus ecology, epidemiology, and disease. *Clin Microbiol Rev* 23: 412-441.
10. Watson DC, Sargianou M, Papa A, Chra P, Starakis I et al. (2014) Epidemiology of Hantavirus infections in humans: a comprehensive, global overview. *Crit Rev Microbiol* 40: 261-272.
11. Borja M, Barie JR, Ramomd GS (2002) Radiographic findings in 20 patients with Hantavirus Pulmonary Syndrome correlated with clinical outcome. *AJR Am J Roentgenol* 178: 159-163.
12. Ketai LH, Kelsav CA, Jordan K, Levin DL, Sulvian LM et al. (1998) Distinguishing Hypetopulmonary Syndrome from Acute Respiratory Distress Syndrome by chest radiography. *J Thorac Imaging* 13: 172-177.