

Bacillary Angiomatosis in an HIV Positive Patient Following a Goat Bite

Roshni Kakitha^{1*} and Ambujam Sreedevi²

¹DermaclinX-The Complete Skin and Hair Solution Centre, Delhi, India

²DVL Department, Believer's Church Medical College Hospital, Thiruvalla, Kerala, India

*Corresponding author: Roshni Kakitha, Fellow at DermaclinX-The Complete Skin and Hair Solution Centre, Delhi, India, Tel: +917708541823; E-mail: k.roshni55@gmail.com

Received date: September 11, 2019; Accepted date: November 30, 2019; Published date: December 07, 2019

Copyright: © 2019 Kakitha R, et al. This is an open-access article distributed under the terms of the Creative Commons Attribution License; which permits unrestricted use; distribution; and reproduction in any medium; provided the original author and source are credited.

Abstract

Bacillary Angiomatosis (BA) is caused by *Bartonella henselae* or *Bartonella quintana* reported to be acquired from cats or by trauma. A 40-year-old widow presented with a single large painful tumour over the left index finger at the site of a goat bite. With the history of goat bite, rapid increase in size, a uniformly soft purplish lobulated tumor, which bled on touch, histopathology demonstrating proliferation of capillary sized vessels, in the background of HIV infection, the differential diagnosis was narrowed down to BA and giant pyogenic granuloma. All clinical diagnoses cannot be evidence based all the time, especially in resource poor settings. Therapeutic trials are well known in dermatology and the positive result needs to be considered as evidence for diagnosis in those situations. The remarkable clinical response to oral doxycycline, we feel, could be considered diagnostic of Bartonella infection and hence we report this case.

Keywords Bacillary angiomatosis; Goat bite; HIV

Introduction

Bacillary Angiomatosis (BA) also called epitheloid angiomatosis is a bacterial infection peculiar to HIV and is rare in the immunocompetent. It is caused by *Bartonella henselae* or *Bartonella quintana* species with cutaneous and parenchymal manifestations [1]. It is characterised by vascular skin lesions resembling pyogenic granuloma (PG) [2]. It has been reported to be acquired from cats or by trauma [3].

Case Description

A 40-year-old widow presented with a single large painful tumour over the left index finger at the site of a goat bite sustained seven months ago. Two weeks later patient noticed a red papule which slowly enlarged to the current size.

Patient was emaciated, anaemic and local examination revealed a single, well defined, purplish, lobulated, uniformly soft swelling circumferentially involving almost 70% of the left index finger. Some of the lobules had yellow adherent crusts on their surface and few bled on palpation. There was loss of nail plate with blood clots on the nail bed. Retained suture material was seen sticking out of the lesion. Certain interlobular spaces showed remnants of the leafy paste that the patient had applied earlier (Figures 1 and 2).

Differential diagnoses of foreign body granuloma (FBG) (to the retained suture material), pyogenic granuloma (PG), bacillary angiomatosis and squamous cell carcinoma were considered. Patient was admitted and investigated. She was found to be positive for HIV.

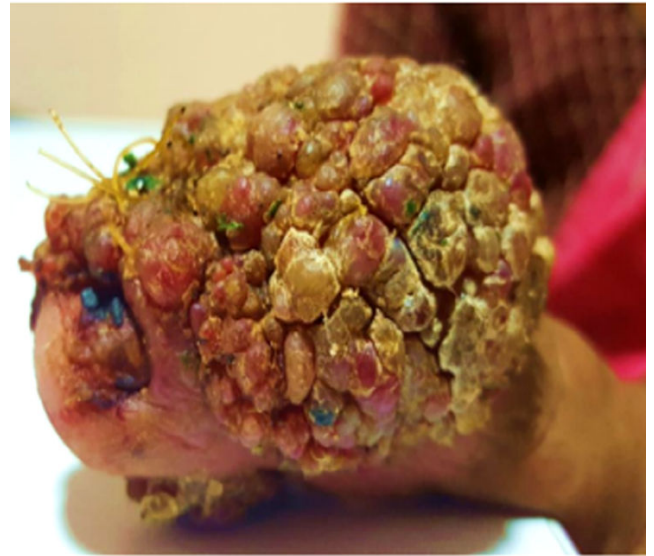

Figure 1: The leafy paste that the patient had applied earlier.

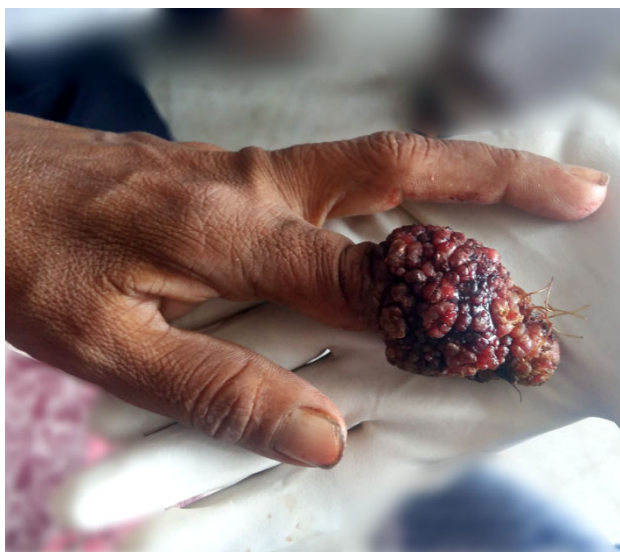

Figure 2: Interlobular spaces showed remnants of the leafy paste that the patient had applied.

X ray of the left index finger revealed a dense soft tissue lesion not continuous with the underlying bone (Figure 3).

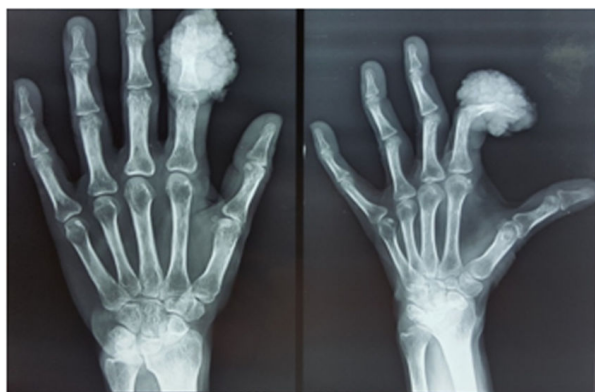

Figure 3: X ray of the left index finger.

Overgrowth of *Staphylococcus aureus* was seen on chocolate agar inoculated with blood aspirated from the lesion.

Histopathological examination (HPE) showed proliferation of capillary-sized blood vessels along with chronic inflammatory cells viz lymphocytes, histiocytes and neutrophils and fibrosis in the deep dermis (Figures 4 and 5). Warthin Starry stain, a silver nitrate based stain used for the definitive diagnosis of BA was not done due to logistic difficulties and unaffordability by the patient.

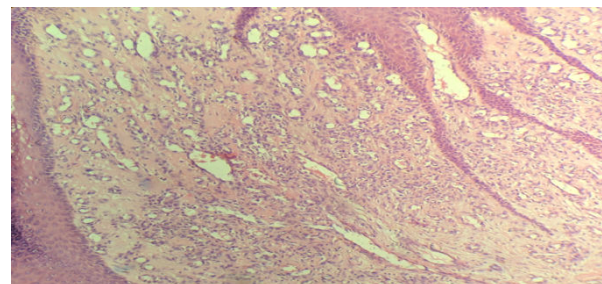


Figure 4: H and E stain, 10 x.

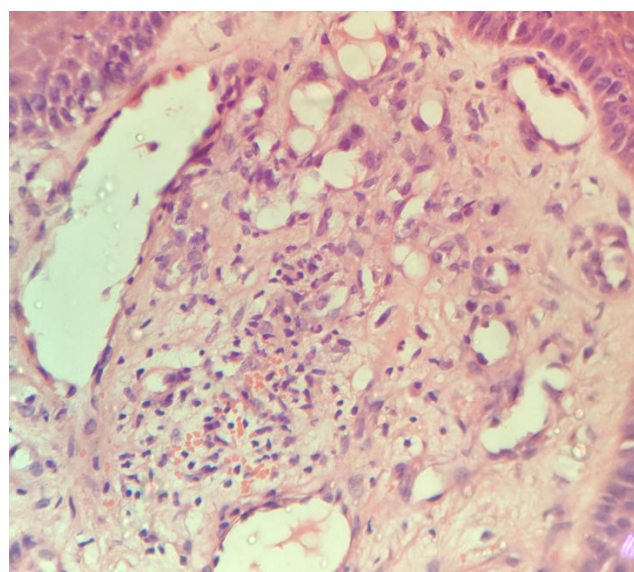


Figure 5: H stain and E stain, 40 x.

With the history of goat bite, rapid increase in size, a uniformly soft purplish lobulated tumor, which bled on touch, HPE demonstrating proliferation of capillary sized vessels, in the background of HIV infection, the differential diagnosis was narrowed down to BA and giant PG.

Both BA and PG can be incited by trauma and are clinically indistinguishable. If left untreated BA will prove fatal while PG will remain localized.

Hence patient was started on Doxycycline 100 mg twice daily, the standard treatment for BA [3]. She was advised to continue the treatment for 3 months. Two weeks later, upon reviewing the patient it was seen that the tumour had shrunken, vascularity had decreased. The contour of the finger was visible (Figure 6). However, the patient was lost for further follow up.

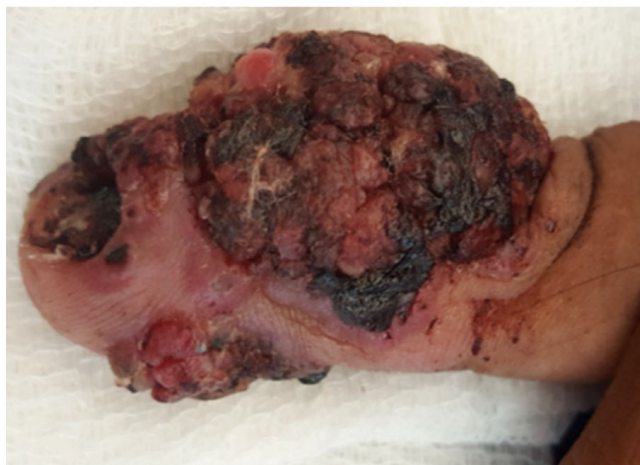


Figure 6: Remarkable clinical response to oral doxycycline.

Discussion

BA is a bacterial infection caused by *Bartonella henselae* and *Bartonella quintana* and almost exclusively seen in HIV infected patients with generally a CD4 count of less than 50 [4]. The infection is acquired from cat's majority of times. A literature search did not reveal acquisition of this infection from goats or other animals apart from a single study where the organism was isolated from the ticks on a goat [1,5]. Clinically BA may resemble PG [3]. The former responds to long term (at least 8 weeks) oral doxycycline and erythromycin while the latter needs to be excised or cauterized [3]. Untreated BA can be fatal, with patients dying of visceral disease or respiratory compromise from obstructing lesions [2]. Our patient had a PG like lesion that appeared 2 weeks after a trauma induced by goat bite.

Bartonella is a very fastidious bacteria and its culture is difficult. It takes at least a month to notice growth, if at all any [2]. In our patient the aspirate culture on chocolate agar grew only *Staphylococcus aureus*.

Obtaining adequate tissue from the skin lesions of BA for HPE is also difficult due to the highly friable nature of the tissue [3]. Both BA and PG have similar HPE findings as that of PG in low power [2].

HPE of BA shows lobular proliferation of capillaries with ectatic vessels lined by prominent endothelial cells on a background of neutrophils, lymphocytes and histiocytes [6]. The HPE of tissue from the swelling in the patient revealed blood vessel proliferation. Absence of granulomas ruled out FBG to retained suture materials and absence of cellular atypia excluded malignancy.

BA is confirmed by demonstration of bacilli from tissue by special stains like Warthin Starry stain [1].

We were unable to do a diagnostic HPE with Warthin Starry stain or PCR for *Bartonella* due to logistic difficulties and other factors beyond our control. We could not make a diagnosis of BA confidently in this context due to lack of specific investigations described in literature. A dramatic response to doxycycline in two weeks, we feel, ruled out PG, leaving BA as the only probable diagnosis.

All clinical diagnoses cannot be evidence based all the time, especially in resource poor settings. The practice of evidence based medicine means 'integrating individual clinical expertise with the best available external clinical evidence from systematic research. Today's practice of strict adherence to evidence based medicine could devalue the rich knowledge that accumulates with clinical experience. It promotes formulaic "cookbook medicine", discouraging deliberation and clinical reasoning and leading to automatic decision which is excessively algorithmic [7].

Conclusion

Therapeutic trials are well known in treating cutaneous tuberculosis, fungal infections, scabies and the positive result needs to be considered as evidence for diagnosis in those situations.

Bacillary angiomatosis can be effectively treated with antibiotics like erythromycin, doxycycline, trimethoprim and sulphamethoxazole, tetracycline and rifampicin.

The remarkable clinical response to oral doxycycline of this goat bite incited skin lesion in our HIV positive patient, we feel, could be considered diagnostic of *Bartonella* infection and hence we report this case.

References

1. Bologna JL (2012) Dermatology: ExpertConsult. 3rd edn. Edinburgh. Elsevier.
2. James WD, Elston DM, Berger TG (2016) Andrews' Diseases of the skin: clinical dermatology. 12th edn. Philadelphia, PA: Elsevier. pp: 965.
3. Griffiths C, Barker J, Bleiker T, Chalmers R, Creamer D, et al. (2016) Rook's textbook of dermatology. 9th edn. Chichester, West Sussex; Hoboken, NJ: John Wiley & Sons Inc.
4. Goldsmith LA, Katz SI, Gilchrist BA, Paller AS, Leffell DJ, et al. (2012) Fitzpatrick's dermatology in general medicine.
5. Sykes JE, Lindsay LL, Maggi RG, Breitschwerdt EB (2010) Human Coinfection with *Bartonella henselae* and Two Hemotropic Mycoplasma Variants Resembling *Mycoplasma ovis*. J Clin Microbiol 48: 3782-3785.
6. <http://www.pathologyoutlines.com/topic/skintumornonmelanocyticbacillaryangiomatosis.html>
7. Greenhalgh T, Howick J, Maskrey N (2014) Evidence based medicine: a movement in crisis? BMJ 348: g3725.