

# An Unusual Case of Double Mandibular Parapremolars: A Cone Beam Computed Tomography Assessed Case Report

Soha M.Basha<sup>1\*</sup>, Bashayer S. Helaby<sup>2</sup> and Manar H. Alhefthi<sup>2</sup>

<sup>1</sup>Department of Basic Dental Sciences, College of Dentistry, Princess Nourah Bint Abdulrahman University, Riyadh, Saudi Arabia

<sup>2</sup>Internship, College of Dentistry, Princess Nourah Bint Abdulrahman, University, Riyadh, Saudi Arabia

## Abstract

**Background:** Extra teeth number in the patient's mouth is scientifically known as supernumerary teeth. Multiple supernumerary teeth are frequently seen in patients with developmental disorders. Cone-Beam Computed Tomography (CBCT) is a three-dimensional imaging tool that can provide a precise case planning. The purpose of this paper is to present a rare case of double parapremolars in on single quadrant and investigate these teeth by using Cone-Beam Computed Tomography (CBCT).

**Case Description:** A 28-year-old, Filipino female patient came to PNU dental clinics. She was medically fit, not on medications and no allergies were detected. Intraoral examination revealed presence of two supernumerary teeth at the area between #35 and #36. The Parapremolars located in quadrant three, both are with normal shape and color. Regarding the position, the first supernumerary has erupted lingually, the second is in the arch line but slightly tilted to the lingually. As a result of the extra teeth number, moderate crowding found in the area. The patient denied any family history of similar findings.

**Discussion:** Extraction of the first supernumerary tooth was carried out after radiographic analysis using CBCT, to facilitate proper oral hygiene, to prevent food impaction, and to eliminate its possible effects on the adjacent teeth. Extraction was performed cautiously without causing any damage to the anatomical structures. Regarding the anatomical position of the tooth, we prepared splint for teeth stabilization in case of adjacent teeth mobility. Extraction was done under local anesthesia. The patient was followed up after the extraction, no complications were reported.

**Conclusion:** Double parapremolar teeth were found in a non-syndromic patient. CBCT precisely locate malposed supernumerary teeth and help in getting proper treatment plan without complications.

**Keywords:** Parapremolar • Supernumerary teeth • CBCT

## Introduction

Extra number of teeth is an odontostomatological phenomenon known as supernumerary teeth. They Can be found either in primary or permanent dentition [1]. Maxillary supernumerary teeth have shown tendency over mandibular supernumeraries. The incisor region is the most prevalent region followed by the molar region. Often, multiple supernumerary teeth are observed in patients with developmental disorders like cleft lip and palate, cleidocranial dysostosis, and Gardner's syndrome. Moreover, Supernumerary teeth are influenced by hereditary and environmental factors, and presented with clinical variations such as location, number, and morphology [2-5]. Several studies revealed that supernumerary observed more frequent in males than females [6,7]. Regarding the occurrence site, Scheiner MA et al. reported that supernumerary teeth are commonly found in upper lateral incisor area (50%), mesiodens (36%), upper central incisors (11%), and bicuspid (3%) [8]. While different results presented by Yusof WZ, et al. showed that there was a tendency to non-syndrome multiple supernumerary teeth to occur in the mandible [7]. Morphologically, the parapremolar resembles one of the premolars. Parapremolar can be seen as a single supernumerary tooth or multiple teeth, occasionally in combination with other types of supernumerary

teeth. Cone-Beam Computed Tomography (CBCT) imaging allows a three-dimensional visualization of teeth and their adjacent anatomical structures. Nowadays, CBCT has been extensively used to accurately detect impacted and supernumerary teeth. CBCT evaluation of supernumerary teeth for accurate case planning is recommended. The purpose of this paper is to present a rare case of double parapremolars in on single quadrant that were initially detected clinically followed by radiographic analysis using CBCT.

## Methodology

This study has been done in Princess Nourah Bint Abdulrahman University (PNU). The appropriate patient consent form was taken. In the form, the patient has given her consent for her images and other clinical information to be reported in this article. The patient understands that her name and initials will not be published. Data collected clinically, radiographically and photographically about the patient's teeth and oral conditions. CBCT was used to assess the treatment plan and minimize the complications that may happen during performing any procedure.

## Case Presentation

A 28-years-old, Filipino female patient came to PNU dental clinics seeking affordable ways to replace her missing upper frontal teeth. She has no significant past medical history and not on medications and no allergies were detected. Intraoral examination revealed multiple carious teeth, missed teeth: #17, #16, #12, #11, #21, #22, remaining roots: #26 and two supernumerary teeth at area between #35 and #36. Two Parapremolars located in quadrant three (Figure 1), both are with normal shape and color. Regarding the position,

\*Address for Correspondence: Basha SM, Department of Basic Dental Sciences, College of Dentistry, Princess Nourah Bint Abdulrahman University, Riyadh, Saudi Arabia, E-mail: SMBasha@pnu.edu.sa

**Copyright:** © 2020 Basha SM, et al. This is an open-access article distributed under the terms of the Creative Commons Attribution License, which permits unrestricted use, distribution, and reproduction in any medium, provided the original author and source are credited.

**Received** 15 April 2020; **Accepted** 15 May 2020; **Published** 22 May 2020

the first supernumerary erupted lingually (Figure 2), the second supernumerary is in the arch line but slightly tilted to the lingual (Figure 3). As a result of the extra teeth number, moderate crowding found in the area. The patient was informed about the presence of supernumerary teeth and she denied any family history of similar findings. The patient was advised to extract the lingually erupted supernumerary tooth regarding the wrong position and its effects on adjacent teeth as well as its effect on oral hygiene. CBCT was taken to evaluate the supernumeraries.

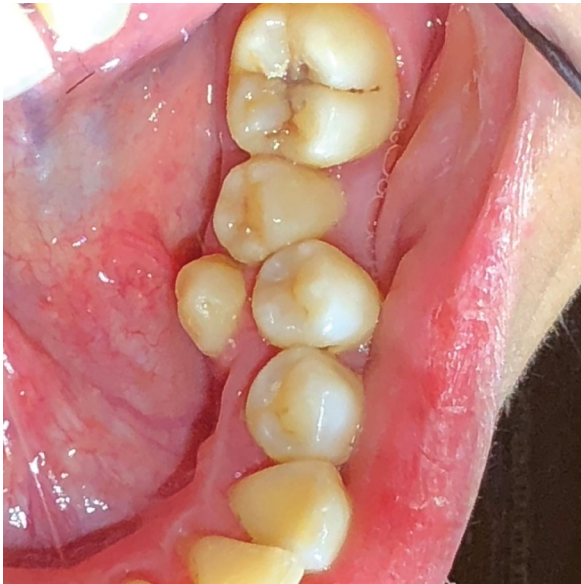

Figure 1. Two parapremolars located in quadrant three.

## Discussion

Supernumerary teeth are a rare finding in patients with no syndrome and medically free [9]. Furthermore, several studies concluded that it is uncommon to find multiple supernumerary teeth without an accompanying syndrome [10]. In many populations, parapremolars have been reported. Around 8-10% of supernumeraries presented by parapremolars. Moreover, it was noted that the prevalence of parapremolars in an Australian population is around 8% [11]. While supernumerary premolars in the American population has reported as 8-9% [12,13]. Supernumerary teeth management is not straightforward, dental practitioners usually are facing obstacles. Orner et al. have recommended that if the supernumerary teeth are not causing any effects on adjacent teeth and there is no future orthodontic treatment expected, then it is reasonable not to go for surgical intervention [14]. In agreement, Koch et al. stated that immediate removal of supernumeraries is not necessary if no pathology is detected [15]. Clinical management of parapremolars depends on its position and the potential effect on the adjacent structures. Extraction or observations are the proper affordable treatment modalities. Extraction is generally considered when there is a failure of eruption of permanent teeth or potential complications such as crowding, root resorption, impaction and cyst formation [16].

In this case, CBCT examination of the mandible extended from occlusal surfaces of the mandibular teeth to the inferior border of the mandible was performed (Figures 2 and 3). The image was acquired with 8.5 cm FOV, 0.2 voxel size, and using i-CAT CBCT unit. Software (iCAT Vision) was used to view the images. Multiplanar CBCT scans showing two supernumerary teeth in the region of the lower left premolar area. Cross-sectional, sagittal and coronal CBCT slices along the long axis of two supernumerary teeth and teeth #34, #35 were taken. Imaging Findings showed that the first supernumerary tooth is

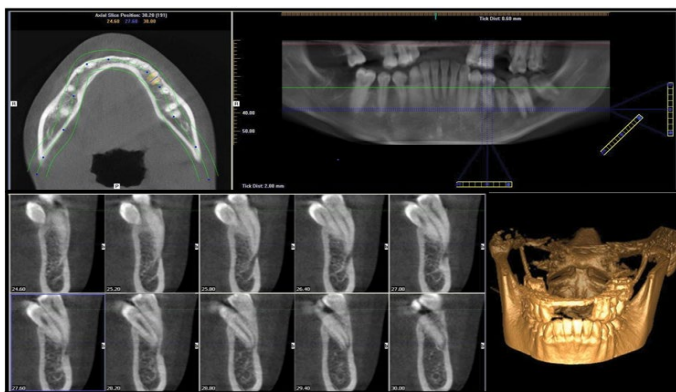


Figure 2. CBCT of first parapremolar.

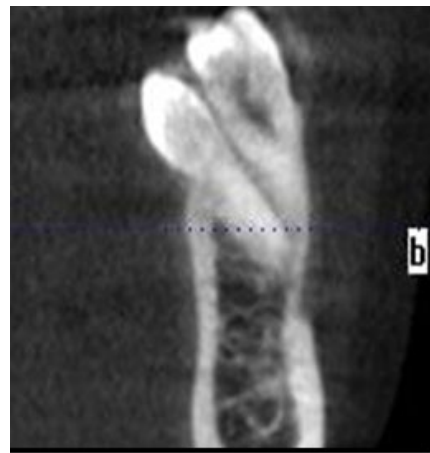

Figure 4. Cross-sectional image of 35 and 1<sup>st</sup> supernumerary.

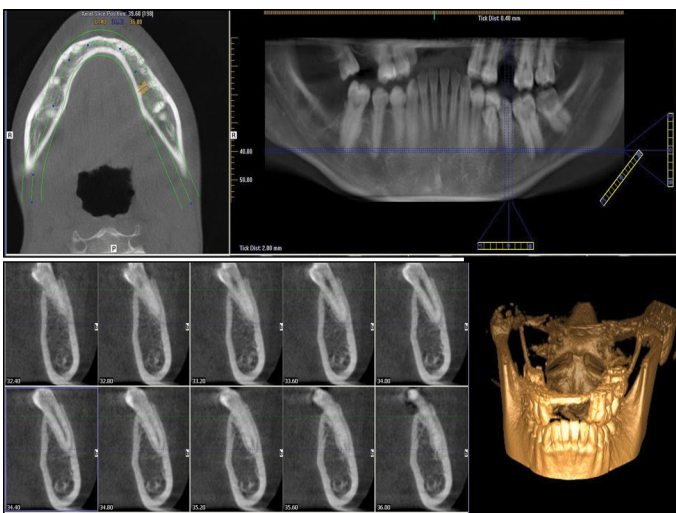


Figure 3. CBCT of second parapremolar.

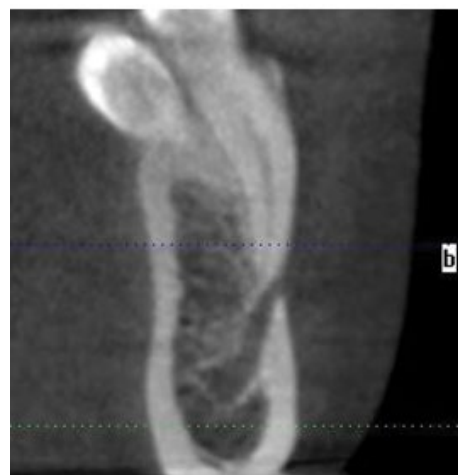

Figure 5. Cross-sectional image of 35 encroaching on mental foramen.

located lingual to tooth #35 and displacing it buccally (Figure 4), and the apex of tooth root #35 is encroaching on the mental foramen (Figure 5). The first supernumerary tooth has incompletely formed root with radiographic evidence

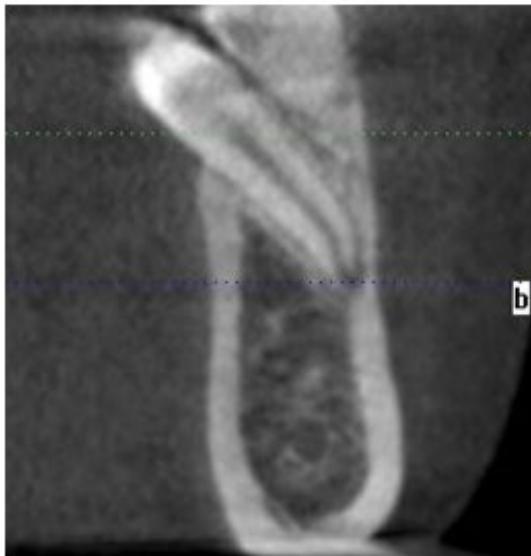

Figure 6. Open apex of first supernumerary.

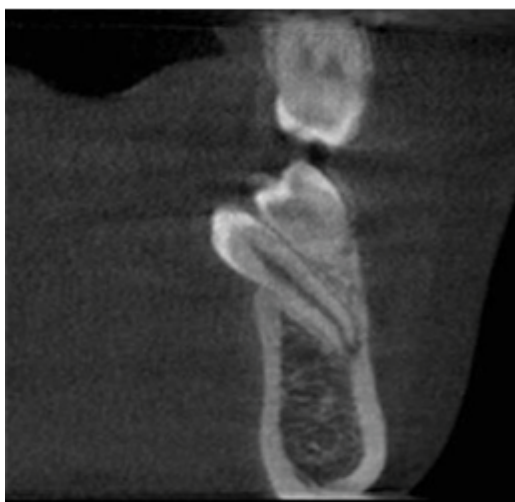


Figure 7. Thinning of buccal cortical plate from 1<sup>st</sup> supernumerary.

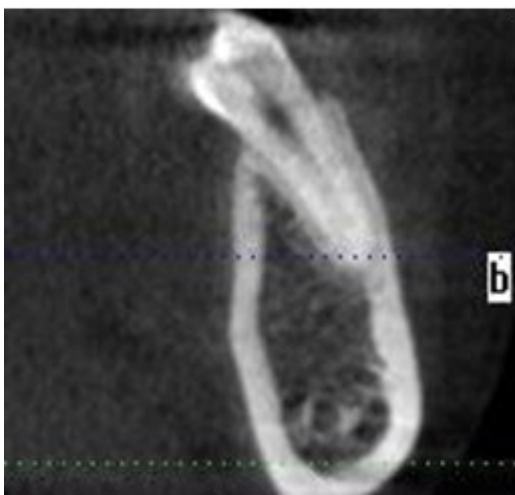


Figure 8. Cross-sectional image of 2<sup>nd</sup> supernumerary.

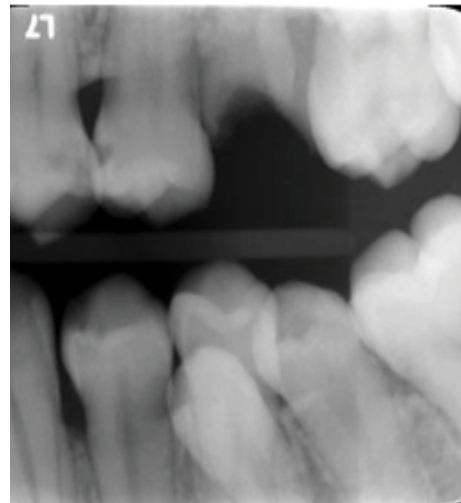


Figure 9. Left side BW.

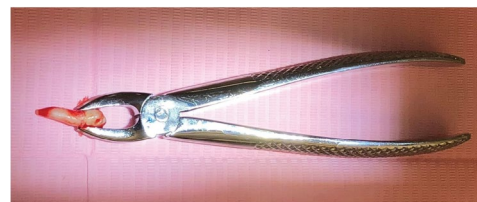

Figure 10. Extraction of 1<sup>st</sup> supernumerary using upper anterior forceps.

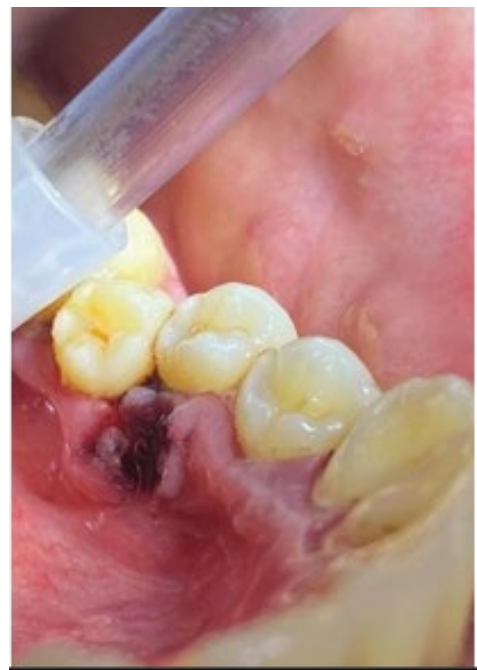

Figure 11. Socket after extraction of 1<sup>st</sup> supernumerary.

of open apex (Figure 6). Accordingly, it causes thinning of the buccal cortical plate (Figure 7). Whilst the second supernumerary tooth is located distal to tooth #35 (Figure 1). The crown is in lingual direction while the root positioned buccally and very close to the buccal cortical plate, it has completely formed root with intact continuous lamina dura. Its apex is away from mental foramen (Figure 8). Extraction of first supernumerary tooth was carried out to facilitate proper oral hygiene, to prevent food impaction, and to eliminate its possible effects on the adjacent teeth (Figure 9). In this case, extraction was performed cautiously, without causing any damage to the anatomical structures or the roots of the adjacent teeth and cortical plate. Regarding the anatomical position



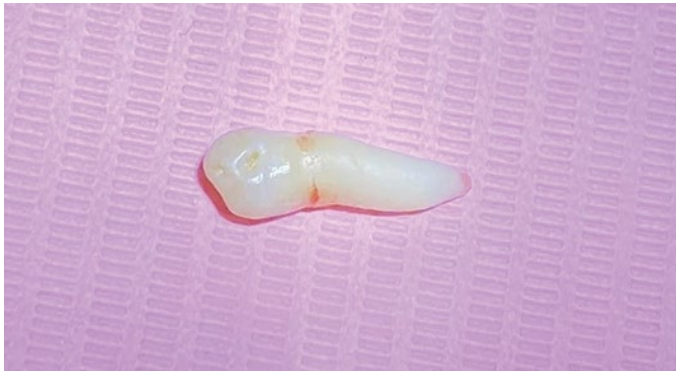

Figure 12. 1<sup>st</sup> supernumerary after extraction.

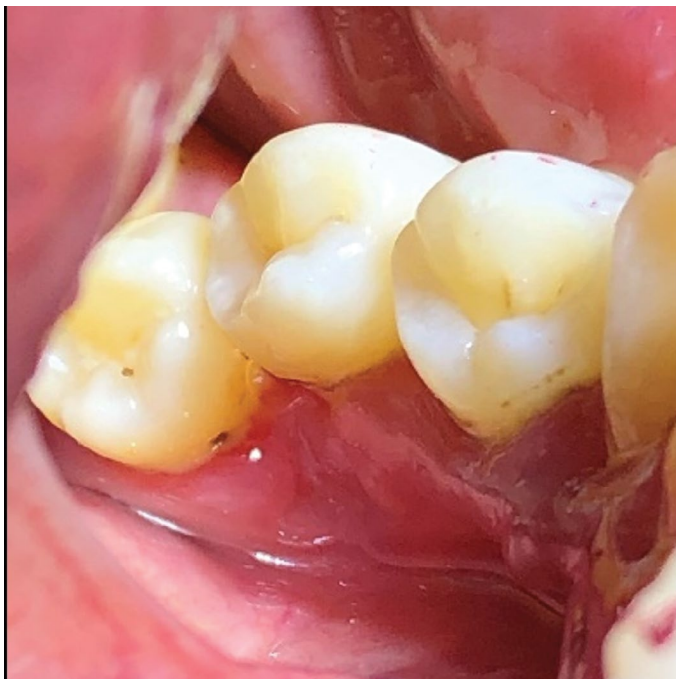

Figure 13. 2 weeks after extraction.

of the tooth, we prepared splint for teeth stabilization in case of adjacent teeth mobility. Extraction was done under local anesthesia using Lidocaine HCl 2% and Epinephrine 1:100,000. Soft tissue around the tooth was reflected by Mucoperiosteal elevator. Extraction was completed (Figure 10). The socket was washed using normal saline, and a blood clot was formed (Figures 11 and 12). The patient was followed up after the extraction. Moreover, no post-operative complications were reported (Figure 13).

## Conclusion

Double parapremolar teeth were found in a non-syndromic patient. CBCT precisely locate malposed supernumerary teeth and help in getting proper treatment plan without complications.

## Acknowledgement

- This research was funded by the Deanship of Scientific Research

at Princess Nourah Bint Abdulrahman University through the Fast-track Research Funding Program.

- We thank Basic Dental Science Department -Princess Nourah Bint Abdulrahman University; Oral Radiology and Oral Surgery Division who provided insight and expertise that greatly assisted this research.

## References

- Renu Tanwar, Vipul Jaitly, Aadya Sharma and Rashmi Heralgi, et al. "Non-syndromic Multiple Supernumerary Premolars: Clinicoradiographic Report of Five Cases." *J Dent Res Dent Clin Dent Prospects* 11 (2017): 48-52.
- Mallineni, Sreekanth Kumar. "Supernumerary Teeth: Review of the Literature with Recent Updates." *Int J Paediatr Dent* 12 (2002): 244-254.
- Gökhan Gürler, Çağrı Delilbaşı and Evren Delilbaşı. "Investigation of Impacted Supernumerary Teeth: A Cone Beam Computed Tomograph (CBCT) Study." *J Istanbul Univ Fac Dent* 26 (2017): 1.
- Andrei Oana Cella, Mărgărit Ruxandra, Tănăsescu Luminita Andrei and Dăguci Luminita, et al. "A Rare Case of Mandibular Parapremolars in Siblings: Case Report and Literature Review." *Rom J Morphol Embryol* 58 (2017): 1485-1490.
- Ashish Shah, Daljit S. Gill, Christopher Tredwin and Farhad B Naini. "Diagnosis and Management of Supernumerary Teeth." *Dent Update* 35 (2008): 510-512.
- Gianluca Porcaro, Marcello Maddaloni, Elisa Rota and Luca Mirabelli, et al. "Evaluation of Surgical Options for Supernumerary Teeth in the Anterior Maxilla." *J Dent Child* 11 (2018): 294-298.
- Açikgöz Aydan, Açikgöz Gokhan and Otan Feiza. "Characteristics and Prevalence of Non-syndromic Multiple Supernumerary Teeth: A Retrospective Study." *Dentomaxillofac Radiol* 35 (2006): 185-190.
- Mark A. Scheiner and Wayne J. Sampson. "Supernumerary Teeth: A Review of the Literature and Four Case Reports." *Aust Dent J* 42 (1997): 160-165.
- Vineeta, Singhal. "Nonsyndromic Supernumerary Bilateral Parapremolars." *J Oral Res Rev* 9 (2017): 82.
- Awang, Noor. "Non-syndromic Multiple Supernumerary Teeth: Literature Review." *J Can Dent Assoc* 56 (1990): 147-149.
- Khaled Khalaf, Saaid Al. Shehadat and Colin A. Murray. "A Review of Supernumerary Teeth in the Premolar Region." *Int J Dentist* 2018 (2018): 1-6.
- Richard C. Ruffalo and Thomas Zullo. "Impacted Supernumerary Teeth: A Survey of 50 Cases." *J Am Dent Assoc* 106 (1983): 201-204.
- Levent Demiriz, Mustafa Cenk Durmuşlar, and Ahmet Ferhat Misir. "Prevalence and Characteristics of Supernumerary Teeth: A Survey on 7348 People." *J Int Soc Prev Community Dent* 5 (2015): 39-43.
- Nandika Manchanda, Robert Anthonappa and Nigel King. "Supernumerary Teeth Formation Following Subluxation of Primary Incisors." *Dent Traumatol* 32 (2010): 14-20.
- Henrik Koch, Ole Schwartz and Bjarne Klausen. "Indications for Surgical Removal of Supernumerary Teeth in the Premaxilla." *Int J Oral Maxillofac Surg* 15 (1986): 273-281.
- Arslan Terlemez and Melek Akman. "Endodontic Treatment of an Unusual Maxillary Molar Tooth Fused with a Paramolar: Case Report." *J Dent Sci Cases* 1 (2015): 242-248.

**How to cite this article:** Soha M. Basha, Bashayer S. Helaby and Manar H. Alhefdhi. "An Unusual Case of Double Mandibular Parapremolars: A Cone Beam Computed Tomography Assessed Case Report." *Clin Case Rep* 10 (2020): 1344