

Abdominal Actinomycosis: Case Report

Mateusz Biczysko^{1*}, Hanna Tomczak², Adam Bobkiewicz¹, Tomasz Banasiewicz¹ and Lukasz Krokowicz¹

¹Department of General, Endocrine, and Gastrointestinal Oncological Surgery, Poznan University of Medical Sciences, Poznan, Poland

²Department of Genetics and Pharmaceutical Microbiology, Poznan University of Medical Sciences, Poznan, Poland

Abstract

Actinomycosis is a bacterial infection with chronic or subacute nature that is caused by anaerobic bacteria of *Actinomyces* species. Originally, it was considered a disease of fungal etiology. As of today, it is known that it is a bacterial disease caused by microorganisms that naturally live in the oral cavity, the final section of gastrointestinal tract, and in the female reproductive system. Actinomyces reveal their virulence only in the case of mucosal membrane disruption. Infection spreads through continuity in surrounding tissue forming extensive abscesses and fistulas producing yellow colored granules. The most common localizations for lesions caused by *Actinomyces* are the cervico-facial region, rib cage, abdominal cavity, and pelvis in women.

The subject of this case is actinomycosis in a 35 years old patient. Typical symptoms presented by patients with this disease are: fever, change in bowel habits, lack of appetite, abdominal pain, nausea and vomiting symptoms that are not very specific. What is more, in the preoperative diagnostic process, or even during surgery, actinomycosis is often confused with acute inflammatory or tumor lesions. In most cases, the diagnosis is made only after surgery after examination of histopathological sample.

Keywords: Actinomycosis • Abdominal actinomycosis • General surgery • Tumor • Inflammatory disease

Case Presentation

A 35 years old patient was admitted to the general surgery clinic in the emergency surgery mode due to suspected abdominal hernia entrapment. Two hours before admission to the ward, the patient came to the admission room because of severe lower abdominal pain lasting up to 2 days. The physical examination revealed a painful mass below the umbilicus with a diameter of about 5 cm, the examination described the appearance of a stuck abdominal hernia.

In the interview, the patient reported a gynecological procedure coagulation of changes in the cervix, moreover, as she reports, she used intrauterine devices currently removed, besides that a few months ago she complained of recurrent paronychia (associated with her work she is a manager in industrial plants), and parasite infections due to threadworms.

Additional tests performed

Standing abdominal X-ray image: Fluid levels and free air under diaphragm domes were not shown.

Ultrasound of the abdominal cavity: Below the umbilicus in the median line at the site of palpable thickening in the abdominal wall, a heterogeneous hypoechogenic area with dimensions of transverse 76

× 43 mm and height 55 mm, which may correspond to an inflammatory infiltration and an adjacent intestinal loop the ultrasound image may correspond to the abdominal hernia, the hernia gate is not visible, in the right kidney in the upper cup echo of the median diameter 4 mm, otherwise without aberration.

Blood sample test: WBC: $10.77 \times 10^3/\mu\text{l}$. CRP: 26.7 mg/l. Other laboratory tests within the standard values.

The patient was qualified for laparotomy, during which a tumor emerging from the larger omentum and infiltrating the parietal peritoneum on the abdominal wall. The tumor was resected together with the peritoneum, and the enlarged lymph node of the small intestine mesentery was taken for further examination. The tumor slightly infiltrated the transverse colon due to the unknown etiology of the tumor, the intestine not prepared for surgery, the infiltrate was removed locally (the material was sent for histopathological examination) without opening the lumen of the gastrointestinal tract. During the surgery, the abdominal cavity was examined and a small tubercule in the cervix was found, which aroused suspicion of cancer (Figures 1 and 2).

*Address for Correspondence: Mateusz Biczysko, Department of General, Endocrine, and Gastrointestinal Oncological Surgery, Poznan University of Medical Sciences, Poznan, Poland, Tel: 603782793; E-mail: biczysko.mateusz@gmail.com

Copyright: © 2022 Biczysko M, et al. This is an open-access article distributed under the terms of the creative commons attribution license which permits unrestricted use, distribution and reproduction in any medium, provided the original author and source are credited.

Received: 13 July, 2022, Manuscript No. CMCR-22-69189; **Editor assigned:** 18 July, 2022, Pre QC No. CMCR-22-69189 (PQ); **Reviewed:** 02 August, 2022, QC No. CMCR-22-69189; **Revised:** 13 August, 2022, Manuscript No. CMCR-22-69189 (R); **Published:** 22 August, 2022, DOI: 10.37421/2684-4915.2022.6.219

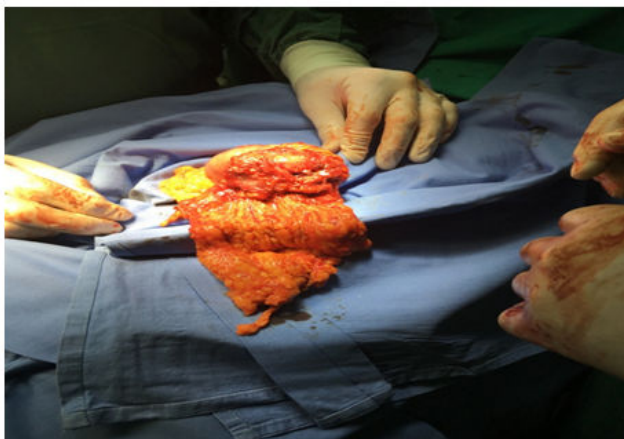


Figure 1. Surgical specimen different angle.

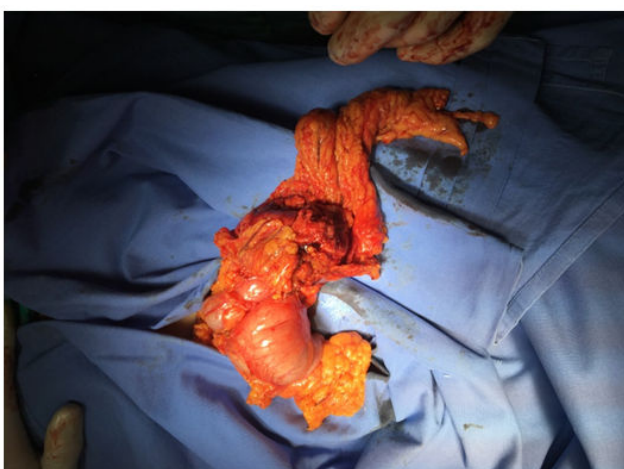


Figure 2. Surgical specimen.

For this reason, it was decided to supplement the diagnostics with a CT scan of the abdominal cavity and pelvis, which was performed on the sixth day after surgery after the patient was discharged home. It showed: at the site of the resected tumor obliteration of mesenteric adipose tissue adjacent to the colon postoperative changes or residual infiltration, in the middle renal cup of the right kidney 5 mm concretion, in the vicinity of the postoperative area numerous mesenteric lymph nodes up to 7 mm in the short axis, at the right edge of the uterus and towards the back of the Douglas pouch, poorly distinguishable fluid areas with a diameter of up to 25 mm and a contrast area of 18 mm ovarian cysts or postoperative changes (a history of gynecological procedures).

After the operation, the patient felt very well, did not report pain and was discharged home on the third day.

Histopathological examination showed abdominal actinomycosis, reactive lymph node as well as fragments of connective and adipose tissue with fibrosis and chronic, partly purulent inflammation. No tumor changes were found (Figure 3).

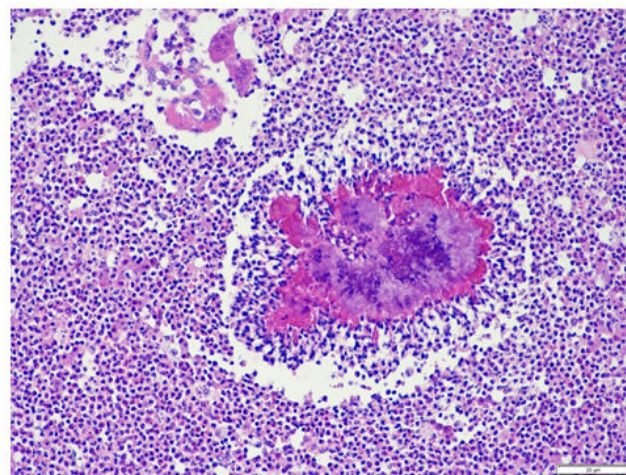


Figure 3. Actinomycosis histopathological sample.

Intra-operative specimen from a larger omentum. In the central part of the micrograph, an outbreak of actinomycosis colonies is visible. In the central part, a basophilic, amorphous material composed of cell nuclei of inflammatory infiltration cells and bacterial cells. Directly next to actinomycosal lesion numerous lymphoid cells and few plasma cells. Surrounding lesions extensively infiltrated with neutrophils, eosinophils, lymphoid cells and histiocytes. Few fibroblast cells in the lesion (Figure 4).

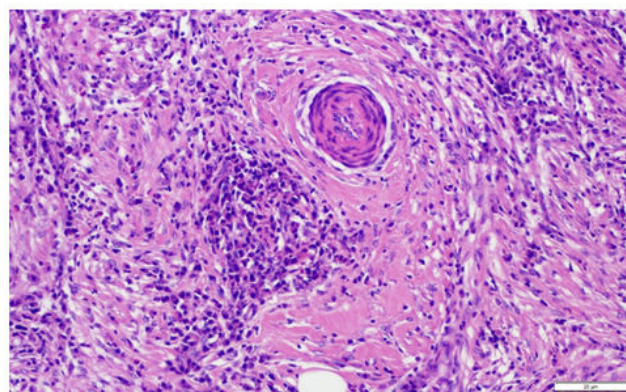


Figure 4. Actinomycosis histopathological sample.

In the middle of the photo, a small arterial vessel with a thick wall and narrow, aperture is visible. In the surroundings of the vessel, connective tissue fins with few cells of the fibrocyte fibroblast line. In the distal area surrounding the vessel, numerous lymphoid cells, among them few monocytes macrophages (Figure 5).

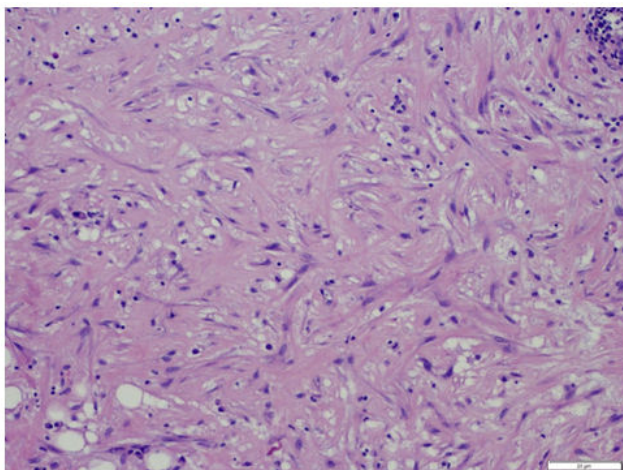


Figure 5. Actinomycosis histopathological sample.

The material taken from the hard part of the lesion contains solid areas of fibrosis. The widespread amorphous areas of dense connective fibrils and fibers predominate, among them numerous stromal cells, mainly fibroblasts, fibrocytes. There are also single cells of the lymphocytic line.

Histopathological specimen images: The patient was administered one dose of antibiotic in the perioperative time 2 grams of cefazoline.

After receiving final histopathological diagnosis the patient was prescribed sulfamethoxazole and trimethoprim two doses of 960 mg per day for 30 days. We did not observe any signs of infection until now.

Discussion

Actinomycosis is a rare infectious disease caused by anaerobic gram-positive bacteria [1-4]. The described patient developed abdominal actinomycosis. This disease can also occur in the cervico-facial form and within the chest organs. However, the rarest form is the abdominal form, it occurs only in 10%-20% of patients with actinomycosis. Usually, this form is associated with a foreign body, e.g. intrauterine device [5-7] or previous surgery associated with disruption of the intestine.

At the time of admission to the hospital, the patient already had the IUD removed, but it was probably the cause of the infection.

Actinomycosis is an infection caused by *Actinomyces* species. They are anaerobes very difficult to diagnose in culture based on the rules of classical microbiology [8]. Positive results can only be obtained if the material is properly collected. The procedure should be carried out quickly so that microbes do not die as a result of oxygen shock. The material usually contains structures similar to sulfur grains, which may suggest to the physician actinomycosis.

The infection is most often preceded by being a carrier of *Actinomyces* in the oral cavity and in the distal part of gastrointestinal tract. In order for the infection to occur, it is necessary to break the tissue continuity. Infection may also occur in patients with immunodeficiency or diabetes [9].

The infection can appear as an inflammatory tumor that forms very slowly, because anaerobes need more time to grow. They may be omitted in culture kept under standard conditions. If in the referral physician does not suggest suspected actinomycosis, then the breeding is too short and the result is false negative. In the case of the described patient, no positive culture was obtained. Information on suspected actinomycosis suggested histopathological findings from the material from the removed abdominal tumor.

Actinomyces are characteristic fungus like bacteria that take on the form of tangled branched threads under a microscope.

The basis of treatment is antibiotic therapy. Treatment of actinomycosis is usually long-term therapy up to 6 months or even one year. The most commonly used antibiotics are penicillin (+/- sulfonamide), and in allergic people erythromycin, clindamycin or doxycycline.

Only early diagnosis and quick start of antibiotic therapy will give a chance for recovery. Some patients need surgery to remove the lesions. The abdominal and pelvic form resembles cancer, both in clinical and radiological picture. The patient described in this paper also underwent surgery because of the need to remove an inflammatory tumor. It was only after the procedure that characteristic features of actinomycosis were detected in the material collected intraoperatively and sent for histopathological examination.

The procedure was necessary and continuation of the antibiotic treatment gave a chance for complete recovery.

Perhaps microbiological examination of the vaginal swab in patients with pelvic and abdominal infection would give the chance to be treated only with an antibiotic at an earlier stage of the disease, without having to undergo surgery, when an inflammatory tumor has already formed [10-12].

Conclusion

Summarizing, it should be noted that actinomycosis can develop in a form similar to a wide spectrum of diseases: Starting from acute inflammation in the abdominal cavity (e.g. acute appendicitis), ending with cancerous tumors of different localization. Combined with the relatively rare population occurrence, this causes great diagnostic difficulties in patients infected with *Actinomyces* species. Therefore, special care and attention should be exercised when diagnosing patients presenting non-specific symptoms of abdominal diseases, especially in cases of previous surgical procedures, a history of gastrointestinal perforation, or the use of intrauterine devices as was the case in the above mentioned patient. However, the diagnostic process is difficult and not obvious. Ultimately, the majority of patients require surgery to remove the lesion, which, combined with long-term targeted antibiotic therapy, gives a high cure rate over 90%.

In addition we would like to inform that we received patients permission to report this case in medical journal.

Conflict of Interest

The authors declare no conflict of interest.

References

1. Nakahira, Evelyn Sue, Linda Ferreira Maximiano, Fabiana Roberto Lima and Edson Yassushi Ussami, et al. "Abdominal and Pelvic Actinomycosis Due to Longstanding Intrauterine Device: A Slow and Devastating Infection." *Autops Case Rep* 7 (2017): 43-47.
2. Simon, Bonnefond, Catroux Melanie, Melenotte Clea and Karkowski Ludovic, et al. "Clinical Features of Actinomycosis: A Retrospective, Multicenter Study of 28 Cases of Miscellaneous Presentations. *Medicine (Baltimore)* 95 (2016): 3923.
3. Boyanova, Lyudmila, Rossen Kolarov, Lyudmila Mateva and Romyana Markovska, et al. "Actinomycosis: A Frequently Forgotten Disease." *Future Microbiol* 10 (2015): 613-628.
4. Marta, Lisa-Gracia, Berta Martin-Rivas, Marcos Pajaron-Guerrero and Ana Arnaiz-Garcia. "Abdominal Actinomycosis in the Last 10 Years and Risk Factors for Appendiceal Actinomycosis: Review of the literature." *Turk J Med Sci* 47 (2017): 98-102.
5. Hager W. "Infections Associated with the Use of an Intrauterine Device: Diagnosis and Treatment of Actinomycosis." *Gin Dipl* 3 (2001): 77-79.
6. Wieslawa, Chmielewska and Malgorzata Walentowicz. "Pelvic Actinomycosis as the Result of a Long Standing Use of an Intrauterine Device, Case Report Opis." *Ginekol Pol* 78 (2007): 995-997.
7. Bednarek M, Budzynski P, Trybus M and Szczepanski W, et al. "Feast Own Experience in the Treatment of the Abdominal Pelvic Form of Actinomycosis." *Med Rev* 74 (2017): 12 664-669.
8. Milczek T, Golka K and Klasa-Mazurkiewicz D. "Actinomycosis of the Genital Organ with a Clinical Course Similar to that of Ovarian Cancer Diagnostic Difficulties and Limitations." *Ginekol Pol* 77 (2006): 957-961.
9. Kaszuba, Marek, Romana Tomaszewska, Kazimierz Pitynski and Piotr Grzanka, et al. "Actinomycosis Mimicing Advanced Cancer." *Pol Arch Med Wewn* 118 (2008): 581-584.
10. Boler, Deniz Eren, Cihan Uras, Suha Goksel and Mehmet Karaarslan. "Actinomycosis of Cecum Associated with Entamoeba Infection Mimicking Perforated Colon Cancer." *Case Rep Gastrointest Med* 2013 (2013):143218.
11. Doberneck RC. "Pelvic Actinomycosis Associated with use of Intrauterine Device: A New Challenge For the Surgeon." *Am Surg* 48 (1982): 25-27.
12. Wagenlehner FM, Mohren B, Naber KG and Mannl HF, et al. "Abdominal actinomycosis." *Clin Microbiol Infect* 9 (2003): 881-885.

How to cite this article: Biczysko, Mateusz, Tomczak, Hanna, Bobkiewicz, Adamand and Banasiewicz, Tomasz, et al.. "Abdominal Actinomycosis: Case Report." *Clin Med Case Rep* 6 (2022): 219.