

# A Novel Variation in the BSCL-2 Gene in Congenital Lipodystrophy

R. Turner<sup>1,2,5</sup>, J. Polanco<sup>1,2</sup>, M. Pietruszka<sup>1,3</sup>, S. Tayefeh<sup>1,2</sup>, Y. Valles-Ayoub<sup>\*1,2,6</sup>, and M. Robinson<sup>1,4</sup>

<sup>1</sup>Firmalab, USA

<sup>2</sup>Ultimate DX, USA

<sup>3</sup>USC Keck School of Medicine, USA.

<sup>4</sup>Marina Diabetes Center, Redondo Beach, California, USA.

<sup>5</sup>CSUCI Channel Islands University, USA

<sup>6</sup>CSUN California State University Northridge, USA

## Abstract

Lipodystrophy is a disorder of fat distribution and storage in the body and results in a generalized or regional selective loss of subcutaneous fat [1]; it may be acquired or congenital. Various syndromes have been described based on age of onset, body fat loss distribution, and associated comorbidities [1]. Attempts have been made to further characterize differences based on genetic testing. We describe a 33-year-old female patient who was referred for endocrine evaluation and in whom results from genetic testing of the BSCL gene showed 2 intronic homozygous variations that may be associated with congenital generalized lipodystrophy type 2 or, Berardinelli-Seip syndrome. This syndrome is a rare autosomal recessive disorder characterized by a generalized lack of adipose tissue [1]. Results of genetic testing suggests a not previously described variation of type 2 lipodystrophy associated with atypical phenotypic features and clinical course. The homozygous intronic variations present on intron 5 is NM\_001122955.3 c.765+69A>G rs2850596 and the novel variant (c.766-49 T>C).

**Keywords:** Berardinelli-Seip congenital lipodystrophy type 2, BSCL2, homozygous intronic variation, subcutaneous fat loss, metabolic disorders, metabolic abnormalities, insulin resistance, body mass index

## Introduction

Acquired generalized lipodystrophies (AGL) typically manifest in childhood, are associated with a generalized loss of subcutaneous fat [1,2] and often lack any distinguishable family history. Congenital generalized lipodystrophy (CGL) or Berardinelli-Seip syndrome typically begins in infancy and is associated with near complete loss of body fat in addition to metabolic abnormalities disorders such as insulin resistance, hepatic steatosis, and cardiomyopathy [1,3,4]. A category of familial partial lipodystrophy is also described which is characterized by subcutaneous fat loss in limbs, hips and buttocks and a regional distribution of excess fat that may give a cushingoid like appearance [1,4].

Deficiency of leptin, a peptide hormone principally made in adipose cells and enterocytes in the small intestine, has been implicated as having a role in the pathogenesis of many of the associated metabolic abnormalities [5]. Metabolic complications seem to be related to a reduced concentration of adipocytokines resulting from the total body fat reduction. Leptin is an adipocytokine which seems to play an important role in BSCL and whose low levels are strongly correlated with changes in lipid and glucose metabolism. Lipid alterations are characterized by hypertriglyceridemia with deposition of triglycerides in the liver and lymphoreticular tissues. Due to the limited capacity for the storage of glucose in the form of fat, glucose is then stored as in the form of glycogen in hepatic, skeletal and cardiac muscle. The disturbance in glucose homeostasis leads to the appearance of insulin resistance and development of diabetes often beginning in childhood [6].

Photographic evidence from infancy may be useful to distinguish CGL from AGL because infants typically show absent fat in CGL and normal fat in

AGL. We describe a 33-year-old female patient who was initially referred for endocrine evaluation with a history of night sweats. The patient can be seen in Figure 4. A fasting glucose was normal but associated with elevated insulin and c-peptide levels. The hemoglobin A1c was 5.5%. A 5-hour glucose tolerance test was consistent with a diagnosis of insulin resistance and reactive hypoglycemia and she was placed on a diet regimen of smaller portioned and more frequent meals with resolution of her symptoms. An appropriate dietary regimen is important in the management of BSCL. A controlled calorie regimen with limitation of total fat intake and the use of fibric acid derivatives such as fenofibrate is indicated for the control of the dyslipidemia [6].

On physical examination she was noted to have regional loss of subcutaneous fat in the face and upper extremities. Her weight was 5 feet 6 inches with a weight of 124 pounds and a BMI of 20.1. Laboratory studies revealed noted elevated alkaline phosphatase and liver transaminases. Abdominal ultrasound and CT scans revealed an enlarged liver with fatty infiltration and splenomegaly. She was treated with a thiazolidinedione, pioglitazone, but discontinued it after several weeks due to GI side effects. Subsequently she developed lower extremity edema and shortness of breath. She was later hospitalized with cardiac arrhythmia and congestive heart failure with an ejection fraction of 21%. Troponin levels were in the normal range. An echocardiogram also showed severe mitral and tricuspid regurgitation. Results of genetic testing suggests a not previously described variation of type 2 lipodystrophy associated with atypical phenotypic features and clinical course. The genetic testing was done by sanger sequencing, which has proven to be useful in amplifying genes to search for novel variations [7,8].

## Materials and Methods

The molecular assays described were performed by FirmaLab, specialized in performing high complexity clinical molecular genetic testing, regulated under the Clinical Laboratory Improvement Amendments of 1988 (CLIA), California Laboratory Field Services (LFS), and accredited by the College of American Pathologists (CAP).

**\*Address for Correspondence:** Valles Ayoub, Firmalab, USA Ultimate DX, USA, 6CSUN California State University Northridge, USA, E-mail: yadira@firmalab.com

**Copyright:** © 2021 Valles Ayoub, et al. This is an open-access article distributed under the terms of the Creative Commons Attribution License, which permits unrestricted use, distribution, and reproduction in any medium, provided the original author and source are credited.

**Received** 10 May, 2021; **Accepted** 24 May, 2021; **Published** 31 May, 2021

## Nucleic Acid Isolation

Buccal epithelial cells were obtained with the Hydra Flock 6" Sterile Elongated Flock Swab w/Plastic Handle & Dry Transport Tube (Puritan Medical Products, Glendora, United States, Cat. #25-3606-H BT.) Cellular DNA was isolated using the Quick-DNA Miniprep Plus Kit (Zymo Research, Irvine, United States, Cat. # D4068S) following manufacturer's instructions. DNA optical density was measured using the ND-1000 Spectrophotometer (Thermo Fisher Scientific, Waltham, United States) for concentration determination. After DNA quantitation, DNA was diluted using RNase free H2O to a concentration of 20ng/μL. Isolated DNA was stored at -20oC as necessary.

## PCR

PCR amplification was done on BSCL-2 gene exons using Gene Amp PCR System 9700 thermocycler. PCR Primers were designed for the amplification of the (BSCL-2) coding region Table 1.

The amplification assay included a 3 min enzyme activation step at 95°C followed by 35 PCR cycles, each of which included three steps: denaturation of DNA template and primers for 30s at 95°C, annealing of primers to single-stranded DNA template for 30s at 60°C, and extension of amplicon strand (complementary to DNA template strand) for 1 min at 72°C.

## Gel Electrophoresis and Imaging

The amplicon was electrophoresed for 30 minutes at 90V and viewed in a 4% Nusieve® 3:1 plus agarose, to confirm that amplification had occurred. The gel was electrophoresed with a 3μL KAPA Express DNA Ladder kit (KAPA Biosystems, Boston, United States, Cat. # KL6303). The Electrophoresis gel was photographed on an Epi Chemi II Darkroom (UVP, United States) and viewed using Lab Works Figure 1.

## Purification

After amplification was confirmed, the amplicons were then purified and concentrated using a ZR DNA Clean & Concentrator™ (Zymo Research, Irvine, United States, Cat. # D4051) kit according to the manufacturer's

instructions and eluted with triple-distilled water to a final volume of 30μL. DNA concentrations and optical densities were quantified using the NanoDrop ND1000 Spectrophotometer.

## Sequencing and Analysis

The patient's BSCL-2 exons 2, 3, 4, 5-6, 7-8, 9-10, and 11 genotypes were analyzed for variations via target exon sequencing. A 15μL reaction mix was prepared for cycle sequencing, comprised of 5μL of 5X sequencing buffer, 2μL of forward and reverse primer (1.0μM), 1μL of Big Dye Terminator® (Thermo Fisher, West Hills, United States, Cat. # 4337458), and 7μL of 5ng/μL purified amplicon product. Cycle sequencing was performed with an enzyme activation step of 1 min at 96oC followed by 25 PCR cycles, each included denaturation for 1 min at 96°C, annealing for 5s at 50°C, and extension for 1.5 min at 60°C. Cycle sequenced products were separated from the reaction mix using the ZR DNA Sequencing Clean Up Kit™ (Zymo Research) and eluted with 10μL of HiDi™ Formamide. Eluted samples were diluted 1:10, making a 0.5ng/μL solution with a total volume of 10μL and loaded for sanger sequencing on the AB (Applied Biosystems) 3130xl Genetic Analyzer. Electropherograms were visually inspected for peak shape and height to confirm nucleotide identity using the Sequencher 4.9 software. Results were aligned and compared to reference assembly human DNA by the Human Genome Sequencing Consortium with consensus to reference: NC\_000011.

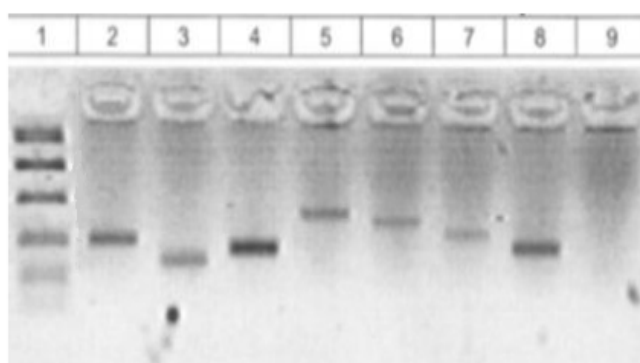
## Results

Results of the BSCL-2 gene in this patient found two variations on intron 5:

- 1.Homozygous variation on intron 5, NM\_001122955.3 c.765+69 A>G. Prevalence 25.28% [9] in general population (Figure 2).
- 2.Homozygous variation on intron 5, c.766-49 T>C. Novel variation (Figure 3).

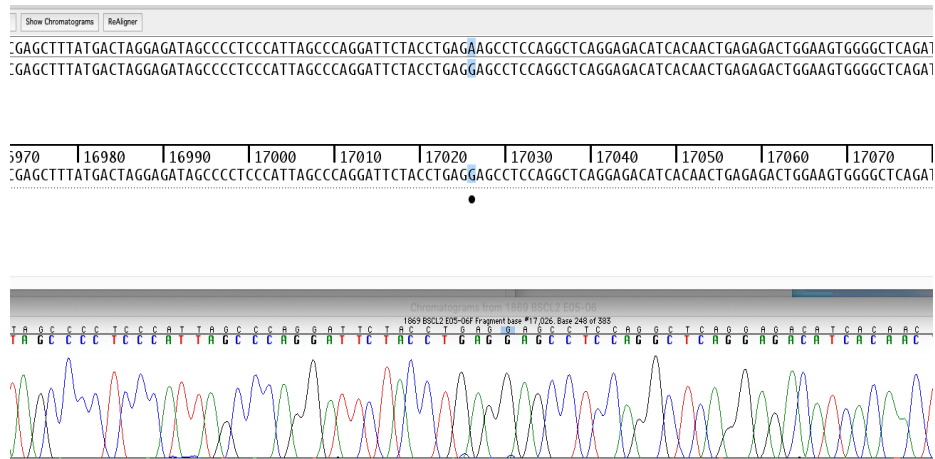
**Table 1:** These are the primers designed for amplification of the BSCL-2 gene.

Ex on	Forward Primer	Reverse Primer
1	GATCGCCACTTCACGTTTTAG	CCAGCCACCTATTTCCAG
2	TAAGCTGTTTTGTCCCCACC	ACTGAATGAACTCAAGGCC
3	GCAAAGAAGGTGTATGGATGG	GCCTTTCTCAAGTCTTCCTATTTG
4	TGGAATAGAGACAGTACATTTTCAAC	CCTACCCATTCTGATCCTGC
5-6	TGGTTGAGGGGTAGGTAGGG	CCTCTTGGTGAAGGTTAGC
7-8	GGCTGGTGCTCTGGTAAC	TGAAGCAGGGACTCCTTCTG
9-10	AGGAAGGTGAGGTTGGCAC	GGGATATTAGATTAACCGGGG
BSCL-2 Primers	CTGCAGCGTGACCTGGG	AAAACGAGGGGAGAGGAGTC



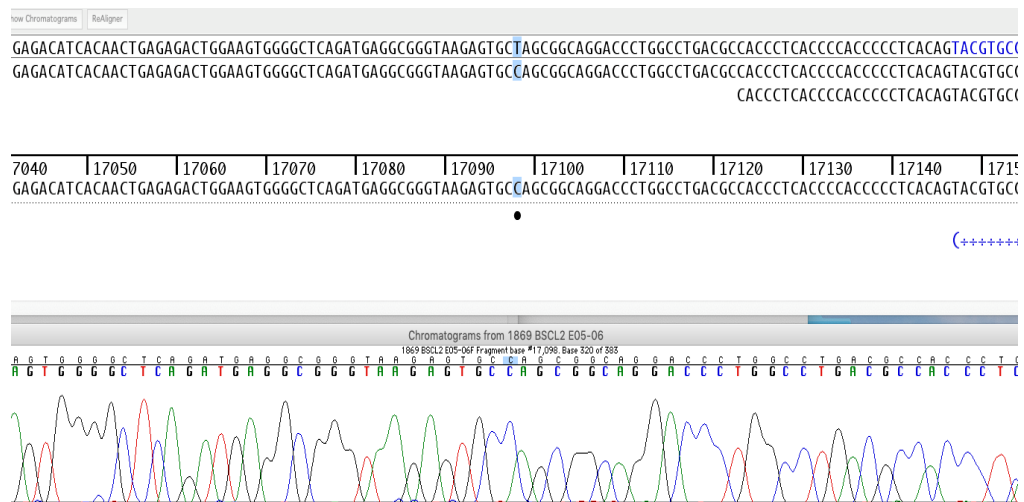
**Figure 1.** Amplification of Target Regions in BSCL-2 Gene

Amplicons from the BSCL-2 gene were amplified and electrophoresed to confirm amplification. From left to right the columns contain the KAPA Express Ladder (1) BSCL-2 E02 (2), BSCL-2 E03 (3), BSCL-2 E04 (4), BSCL-2 E05-06 (5), BSCL-2 E07-08 (6), BSCL-2 E09-10 (7), BSCL-2 E11 (8), and the Negative Control (9).



**Figure 2.** Homozygous Intronic Variation NM\_001122955.3 c.765+69A>G

Electropherogram of intron 5 depicting the homozygous intronic variation (c.765+69 with an A to G). The variation is marked by the arrow.



**Figure 3.** Homozygous Intronic Novel Variation c.766-49 T>C

Electropherogram of intron 5 depicting the homozygous intronic variation (c.766-49 with a T to C). The variation is marked by the arrow.



**Figure 4.** Photographs of patient until the third decade of life.

## Discussion

The gene for BSCL-2 is located on the long arm of chromosome 11 (11q13) [10] and encodes a protein, Seipin which is linked to fusion of lipid droplets and adipocyte differentiation [11,12]. Mutations in this gene have also been linked to congenital generalized lipodystrophy type 2 or Berardinelli-Seip syndrome, a rare autosomal recessive disease characterized by a near total absence of adipose tissue, insulin resistance, hepatic steatosis and early onset of diabetes [1,2,11]. Patients with this mutation described heretofore presented with generalized loss of subcutaneous fat at birth or in the first few years of life.

The patient described here contained two variations on the introns of the BSCL-2 gene which may be associated with congenital generalized lipodystrophy type 2 or, Berardinelli-Seip syndrome. Photographic images review of our patient since birth showed no expression of lipodystrophy until near the third decade of life and only with regional subcutaneous loss of fat in the face and limbs (Figure 4). Unique as well, is the clinical presentation with night sweats and reactive hypoglycemia. Hepatic steatosis and insulin resistance were common coexistent findings and associated with hepatosplenomegaly on imaging studies in our patient. Metformin is a useful drug in the management of some patients with diabetes and BSCL and can result in appetite reduction and improvement in hepatic steatosis and menstrual irregularities in a subset of patients who also have polycystic ovarian syndrome. In some cases, insulin may also be necessary to improve management of type 2 diabetes [13,14]. Though our patient had no initial cardiovascular symptoms, she later developed cardiac arrhythmia and congestive heart failure after exposure to pPioglitazone. There was no evidence of coronary artery disease or atherosclerosis. A family history was unremarkable for lipodystrophy.

## Conclusion

Lipodystrophy is a complex disorder of fat storage and metabolism which may have diverse physical and clinical expression. Genetic testing is essential to differentiate a specific variety that what may not always be evident based on physical examination or clinical course alone. Multiple clinical variants are probably yet unknown due to the rarity of diagnosis and testing as well as reporting of isolated cases. Cardiovascular testing is warranted at diagnosis despite absence of symptoms in some patients. Newer therapeutic options such as human recombinant leptin has been demonstrated to correct many of the associated metabolic disorders and should be considered in early management [15-18] but is unlikely to reflect in cosmetic changes in clinical appearance of fat loss or distribution. More clinical studies and genetic sequencing for patients with CGL are recommended to further understand and describe the impact of these genetic variations.

## References

1. Araujo-Vilar, David, and F. Santini. "Diagnosis and treatment of lipodystrophy: a step-by-step approach." *Journal of endocrinological investigation* 42, no. 1 (2019): 61-73.
2. Maldergem, Lionel Van. "Berardinelli-Seip Congenital Lipodystrophy." *GeneReviews*® [Internet]., U.S. National Library of Medicine, 8 Dec. 2016, [www.ncbi.nlm.nih.gov/books/NBK1212/](http://www.ncbi.nlm.nih.gov/books/NBK1212/).
3. Brown, Rebecca J., David Araujo-Vilar, Pik To Cheung, David Dunger, Abhimanyu Garg, Michelle Jack, Lucy Mungai et al. "The diagnosis and management of lipodystrophy syndromes: a multi-society practice guideline." *The Journal of Clinical Endocrinology & Metabolism* 101, no. 12 (2016): 4500-4511.
4. Garg, Abhimanyu. "Lipodystrophies: genetic and acquired body fat disorders." *The Journal of Clinical Endocrinology & Metabolism* 96, no. 11 (2011): 3313-3325.
5. Blüher, Susan, et al. "Leptin Deficiency." *Journal of Investigative Medicine*, vol. 57, no. 7, (2009), 784-788.
6. Gomes, Karina Braga, Victor Cavalcanti Pardini, and Ana Paula Fernandes. "Clinical and molecular aspects of Berardinelli-Seip congenital lipodystrophy (BSCL)." *Clinica Chimica Acta* 402, no. 1-2 (2009): 1-6.
7. Pineda A, Williams N, Chaudhry N, Pietruszka M, Daldalyan K, et al. Impact of CYP2D6 Ultra Rapid Metabolism on Therapeutic Drug Efficacy in Type 2 Diabetic Patients. *Journal of Genetic Cell Biology* (2020): 174-179.
8. Valles-Ayoub, Yadira, Saghi Esfandiari, Daniel No, Pedram Sinai, Zeshan Khokher, Melody Kohan, Tanaz Kahen, and Daniel Darvish. "Wolman disease (LIPA p. G87V) genotype frequency in people of Iranian-Jewish ancestry." *Genetic testing and molecular biomarkers* 15, no. 6 (2011): 395-398.
9. Variation Viewer." National Center for Biotechnology Information, U.S. National Library of Medicine, [www.ncbi.nlm.nih.gov/variation/view/?asm=GCF\\_000001405.25](http://www.ncbi.nlm.nih.gov/variation/view/?asm=GCF_000001405.25).
10. Magré, Jocelyne, Marc Delépine, Eliane Khalouf, Tobias Gedde-Dahl, Lionel Van Maldergem, Eric Sobel, Jeanette Papp et al. "Identification of the gene altered in Berardinelli-Seip congenital lipodystrophy on chromosome 11q13." *Nature genetics* 28, no. 4 (2001): 365-370.
11. Cartwright, Bethany R., and Joel M. Goodman. "Seipin: from human disease to molecular mechanism." *Journal of lipid research* 53, no. 6 (2012): 1042-1055.
12. Fei, Weihua, Ximing Du, and Hongyuan Yang. "Seipin, adipogenesis and lipid droplets." *Trends in Endocrinology & Metabolism* 22, no. 6 (2011): 204-210.
13. Pardini, V., I. Victória, and S. Rocha. "Metformin improves metabolic control in subjects with Congenital Generalized Lipodystrophy." 57th Annual Scientific Sessions, Boston-Massachusetts. *Diabetes* 46 (1997): 160.
14. Garg, Abhimanyu. "Acquired and inherited lipodystrophies." *New England Journal of Medicine* 350, no. 12 (2004): 1220-1234.
15. Petersen, Kitt Falk, Elif Arioglu Oral, Sylvie Dufour, Douglas Befroy, Charlotte Ariyan, Chunli Yu, Gary W. Cline et al. "Leptin reverses insulin resistance and hepatic steatosis in patients with severe lipodystrophy." *The Journal of clinical investigation* 109, no. 10 (2002): 1345-1350.
16. Moreau, F., S. Boullu-Sanchis, C. Vigouroux, C. Lucescu, O. Lascols, R. Sapin, D. Ruimy, B. Guerci, M. Pinget, and N. Jeandier. "Efficacy of pioglitazone in familial partial lipodystrophy of the Dunnigan type: a case report." *Diabetes & metabolism* 33, no. 5 (2007): 385-389.
17. Chan, Jean L., Karen Lutz, Elaine Cochran, Wenying Huang, Yvette Peters, Christian Weyer, and Phillip Gordon. "Clinical effects of long-term metreleptin treatment in patients with lipodystrophy." *Endocrine Practice* 17, no. 6 (2011): 922-932.
18. Mitchell, S. "Singular case of absence of adipose matter in the upper half of the body." *The American Journal of the Medical Sciences* 179 (1885).

**How to cite this article:** R. Turner, J. Polanco, M. Pietruszka, S. Tayefeh, Y, et al. A Novel Variation in the BSCL-2 Gene in Congenital Lipodystrophy. *Mol Biol* 10 (2021):283.