

A Case Report on Appendicular Endometriosis

Taghreed Albalawi^{1*}, Patrick Gergi² and Abdulrahman Alotaibi^{2,3}

¹Department of Surgery, King Fahad General Hospital, Medina, Saudi Arabia

²Department of Surgery, Dr. Soliman Fakeeh Hospital, Jeddah, Saudi Arabia

³Department of Surgery, Faculty of Medicine, University of Jeddah, Jeddah, Saudi Arabia

Abstract

Background: Appendicular Endometriosis represents less than 1% of all pelvic endometriosis cases. It manifests with pain in right iliac fossa and bear resemblance to acute appendicitis. Definitive diagnosis is possible only after histopathological examination of excised appendix.

Case presentation: We report a rare case of Appendicular Endometriosis (AE) in a 38 years old non-married female, otherwise healthy, came to emergency room with less than 24 hours lower abdominal pain associated with nausea but no vomiting. All other systemic review was unremarkable. Patient has no positive medical or surgical history. Blood investigations were normal and abdominal ultrasound US showed edematous wall thickening of the appendix with 12 mm distended lumen. Laparoscopic appendicectomy was performed with incidental finding of blood-tinged fluid in the pelvis and multiple prominent fibroids of the uterus, the appendix was inflamed, and appendectomy done. Postoperative recovery course was uneventful. The final histopathological examination confirmed endometriosis of appendix.

Conclusion: AE is a rare entity and almost always diagnosed after histopathological examination. it should be included in the differential diagnosis of acute abdominal pain, especially when women of childbearing age present with clinical symptoms of acute appendicitis..

Keywords: Appendicular endometriosis AE • Appendix • Endometriosis • Laparoscopic appendicectomy

Introduction

Endometriosis is the presence of endometrial glands and stroma outside the uterine cavity and musculature [1]. It varies in incidence between 4% up to 50% of women of reproductive age and results in pelvic pain in half of these patients [2]. Von Rokitsansky, in 1860, was the first who described the endometriosis [3]. Since then, Sampson proposed his theory of retrograde menstruation as the primary etiologic factor and reported endometriosis affecting the appendix [4]. In 1951, Collins et al. reported a cumulative 150 cases in the literature of endometriosis of the appendix [5]. He further described over 50,000 random pathologic assessments of the appendix and reported the prevalence of appendiceal endometriosis as 0.054% [6]. However, more recent studies have reported the prevalence of AE to be around 0.8% [7]. We describe a case of AE that presented as acute appendicitis.

Case Report

A 38-year-old non-married female, otherwise healthy, came to emergency room with less than 24 hours lower abdominal pain associated with nausea but no vomiting. No history of melena or anemia or unusual bleeding related to her menstruation. All other systemic review was unremarkable apart from allergy to sea food. Patient has no positive medical or surgical history. On physical examination, HR: 76, BP 130/70, T: 36.8, RR 20, Pain score 6 out of 10, BMI: 21.8. Tenderness in right iliac fossa with positive rebound tenderness. The laboratory workup revealed HB 13.2 gm/dl, WBC 9.97 u/L, 61% neutrophil, CRP 11.4 mg/l, PLT 308, US abdomen and pelvis showed edematous wall thickening of appendix with distended and wide lumen caliber 12 mm. There was notable free fluid in right iliac fossa and normal looking ovaries, urinary bladder, and uterus without detectable masses (Figure 1). Patient admitted

*Address for Correspondence: Albalawi T, Department of Surgery, King Fahad General Hospital, Medina, Saudi Arabia, E-mail: dr.albluwi@hotmail.com

Copyright: © 2021 Albalawi T, et al. This is an open-access article distributed under the terms of the Creative Commons Attribution License, which permits unrestricted use, distribution, and reproduction in any medium, provided the original author and source are credited.

Received 26 June 2021; Accepted 13 July 2021; Published 20 July 2021

and received narcotic pain killer, PPI prophylaxis, anti-DVT prophylaxis and broad-spectrum antibiotic.

At 15th April 2018, the patient underwent laparoscopic appendectomy. The intraoperative finding was blood-tinged fluid in the pelvis with prominent fibroids of the uterus. The appendix was inflamed. The mesoappendix divided using bipolar device and the stump closed using the end loop suture technique. The operation completed without complication, no bleeding or conversion to open. Operative time was 51 minutes (Figure 2). The postoperative recovery was uneventful with the hospital stay of 2 days. Patient tolerates orally and discharged home in good condition and followed in the clinic. There are no 30 days morbidities or re-admission. The last visit in the clinic was in May 2021 (36 months follow-up), with no further attacks of abdominal pain during last 3 years. Histopathology Result: Gross examination found appendix totally measured 4 × 0.6 × 0.6 cm. The serosa is grayish brown in color and rubbery in consistency, the mucosa is grayish tan tissue surface. Microscopic examination revealed appendicular tissue with foci of endometrial glands and stroma, surrounded by fibrosis. Hemosiderin laden macrophages noted. No evidence of granuloma, atypia, or malignancy (Figures 3 and 4).

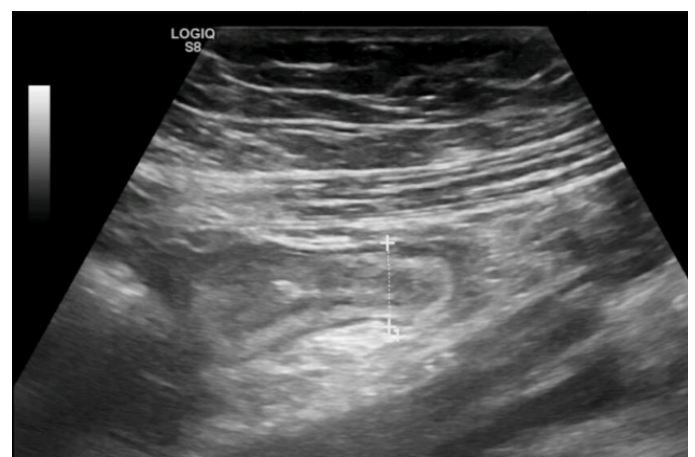


Figure 1. Abdominal ultrasound revealed edematous wall thickening of appendix with distended appendicular lumen showing wide caliber 12 mm.

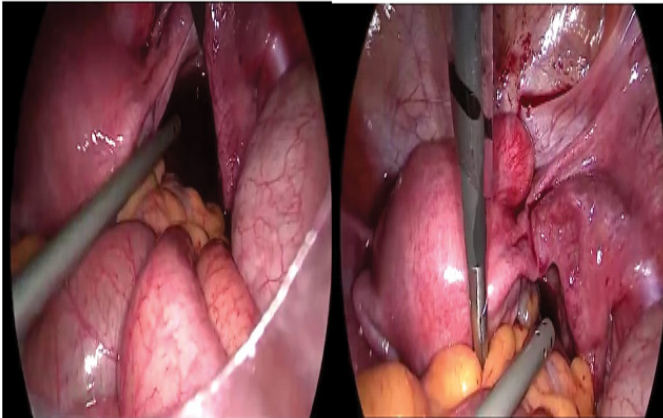


Figure 2. Intraoperative finding of blood-tinged fluid in the pelvis with prominent fibroids of the uterus.

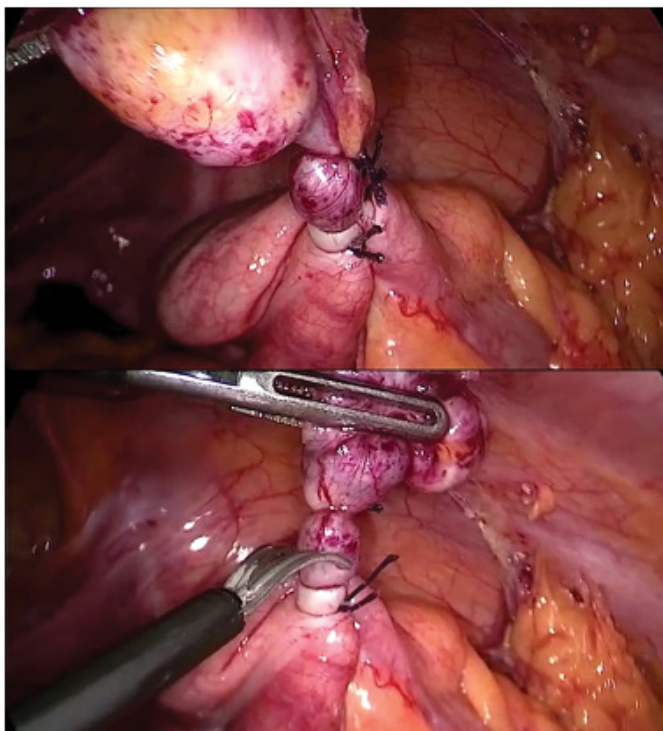


Figure 3. Ligation of the appendicular base with end loop and division of the stump.

Discussion

Endometriosis is an estrogen-dependent, chronic inflammatory disorder with characteristic presence of viable endometrial tissue outside the uterus. It is frequently involving the reproductive organs and peritoneum. The occurrence outside the genital tract is named extragenital endometriosis, and it may affect surgical scars, bladder, heart, pulmonary pleura, diaphragm and GIT [8,9]. In the GIT, the main affected site is the rectum and the sigmoid colon (95%) [10]. the involvement of the cecal appendix is rare [11-14]. In anatomopathological studies of appendectomies, the incidence of endometriosis is low (varying from 0.15% to 1%). Patients with AE can be categorized into four groups. First, patients who present with acute appendicitis, second, those with appendiceal invagination, third, with atypical symptoms such as abdominal colic, nausea, and melena, and last group are asymptomatic patients [15]. Pain in the right lower abdominal quadrant is one of the most common symptoms of AE, in the present case the patient representative of the first group. There is no specific radiologic test to diagnose AE. Laparoscopy provides detailed evaluation; still gross inspection of appendix alone is not enough to rule out AE. In fact, 38% of grossly normal appearing appendix has histological evidence of endometriosis [16].

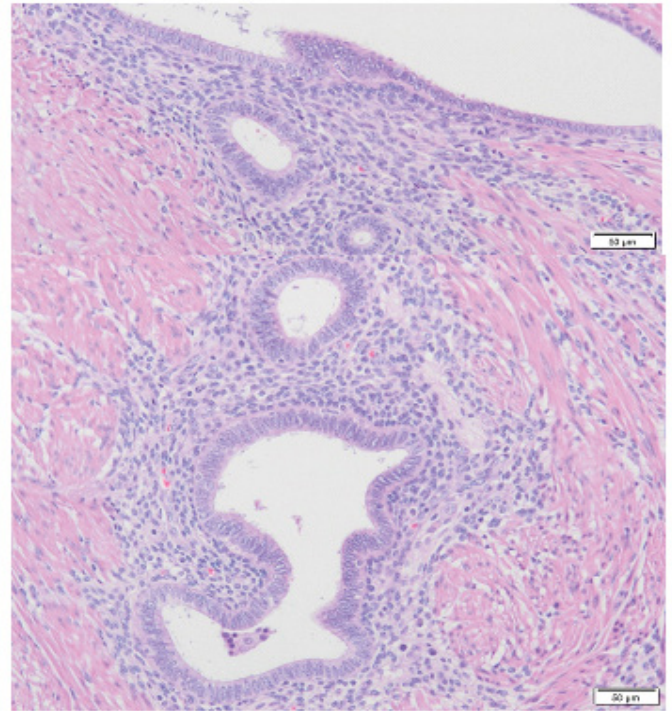


Figure 4. Endometrial glands and stroma with the muscularis layer of the appendix (H&E 100x).

Two cases of AE presented as acute appendicitis have been reported in Saudi Arabia. Khairi et al. in 2005 reported. A 33-year-old female with vague abdominal pain and unexceptional laboratory and radiological finding including CT scan. The patient underwent diagnostic laparoscopy, which revealed 6 cm appendicular mass, uncomplicated appendectomy followed. The histological result showed endometriosis of the appendicular apex [13]. Next in order, Al-Talib et al. in 2013, present a 31-year-old woman nulliparous with recurrent cyclic right-sided pelvic pain for two years. Abdominal and pelvic CT scan was within normal limits. During laparoscopic evaluation, endometriotic implants in the posterior cul de sac noted, the appendix was stretched and adhered to the anterior abdominal wall. Appendectomy with excision of the endometriosis and led to the resolution of her pain symptoms. Histopathological examination revealed endometriosis of the cul de sac and the appendix [17]. In our patient there was no evidence of endometrial tissue implant in the abdominal cavity, the appendix was inflamed, and its histopathological examination showed foci of endometrial glands and stroma. AE appears to be an incidental finding, and tend to be clinically not important [18]. Surgical excision of affected tissue is generally needed for the most efficient and exhaustive treatment of endometriosis. As per the recent guidelines, appendectomy should be performed laparoscopic ally, unless contraindicated [19].

Conclusion

Appendicular endometriosis is unthinkable and almost always diagnosed after surgical excision of the appendix followed by histopathological examination. It should be included in the differential diagnosis of acute abdominal pain, especially when women of childbearing age present with clinical symptoms of acute appendicitis. It tends to be clinically negligible and can be safely done laparoscopically.

References

1. David L. Olive and Lisa Barrie Schwartz. "Endometriosis." *N Engl J Med* 328 (1993): 1759-1769.
2. Daniel W. Cramer and Stacey A. Missmer. "The Epidemiology of Endometriosis." *Ann NY Acad Sci* 955 (2002): 396-406.

3. Ottokar, Rokitansky. "Carl Freiherr von Rokitansky for his 200th Birthday." *Wiener Klinische Wochenschrift* 16 (1860): 577.
4. Sampson, John. "Pforating Hemorrhagic (Chocolate) Cysts of the Ovary: Their Importance and Especially their Relation to Pelvic Adenomas of Endometrial Type (Adenomyoma of the Uterus, Rectovaginal Septum, Sigmoid, Etc.)." *Arch Surg* 3 (1921): 245-323.
5. Collins, Donald. "Endometriosis of the Vermiform Appendix: Review of Literature, with Addition of Nine New Instances, One of Which Caused Severe Melena." *AMA Arch Surg* 63 (1951): 617-622.
6. Collins, Donald. "A Study of 50,000 Specimens of the Human Vermiform Appendix." *Surg Gynecol Obstet* 101 (1955): 437-445.
7. Bulent Berker, Nanette LaShay, Romina Davarpanah and Massimiliano Marziali, et al. "Laparoscopic Appendectomy in Patients with Endometriosis." *J Minim Invasive Gynecol* 12 (2005): 206-209.
8. Samia Ijaz, Surjit Lidder, Waria Mohamid and Martyn Carter, et al. "Intussusception of the Appendix Secondary to Endometriosis: A Case Report." *J Med Case Rep* 2 (2008): 12.
9. Tumay Volkan, Ozturk Erkan, Ozturk Hakime and Yilmazlar Tunkay. "Appendiceal Endometriosis Mimicking Acute Appendicitis." *Acta Chir Belg* 106 (2006): 712-713.
10. Univaldo Etsuo Sagae, Fábio Lopasso, Maurício Simões Abrao and Namir Cavalli, et al. "Gastrointestinal Endometriosis: Clinical and Laparoscopic Correlations." *Rev bras Coloproct* 27 (2007): 423-431.
11. Khoo Joan, Ismail Mustapha and Tiu Chunt. "Endometriosis of the Appendix Presenting as Acute Appendicitis." *Singapore Med J* 45 (2004): 435-436.
12. Toru Hasegawa, Koichi Yoshida and Kazuhiro Matsui. "Endometriosis of the Appendix Resulting in Perforated Appendicitis." *Case Rep Gastroenterol* 1 (2007): 27-31.
13. Khairy, Gamal Ahmed. "Endometriosis of the Appendix: A Trap for the Unwary." *Saudi J Gastroenterol* 11 (2005): 45-47.
14. David K. Driman, Douglas E. Melega, George A. Vilos and Arthur E. Plewes. "Mucocoele of the Appendix Secondary to Endometriosis: Report of Two Cases, One with Localized Pseudomyxoma Peritonei." *Am J Clin Pathol* 113 (2000): 860-864.
15. Hakan Uncu and Dilara Taner. "Appendiceal Endometriosis: Two Case Reports." *Arch Gynecol Obstet* 278 (2008): 273-275.
16. Pittaway, De. "Appendectomy in the Surgical Treatment of Endometriosis." *Obstet Gynecol* 61 (1983): 421-424.
17. Al-Talib, AymanA. "Appendiceal Endometriosis." *Saudi J Med Med Sci* 1 (2013): 103-105.
18. Akihito Idetsu, Hitoshi Ojima, Kana Saito and Hayato Yamauchi, et al. "Laparoscopic Appendectomy for Appendiceal Endometriosis Presenting as Acute Appendicitis: Report of a Case." *Surg Today* 37 (2007): 510-513.
19. Ramon R. Gorter, Hasan H. Eker, Marguerite A. W. Gorter-Stam and Gabor S. A. Abis, et al. "Diagnosis and Management of Acute Appendicitis: EAES Consensus Development Conference 2015." *Surg Endosc* 30 (2016): 4668-4690.

How to cite this article: Taghreed Albalawi, Patrick Gergj and Abdulrahman Alotaibi. "A Case Report on Appendicular Endometriosis." *Clin Case Rep* 11 (2021): 1455.