

# Post-cardiac Injury Syndrome after Percutaneous Coronary Intervention: A Case Report

Nassime Zaoui\*, Sabrina Benamara, Amina Boukabous and Nabil Irid

Department of Cardiology, EHS Draa Ben Khedda, PXH9+373, Draâ Ben Khedda, Algeria

## Abstract

Coronary angioplasty can be complicated by pericarditis which can appear at distance or more rarely early after the procedure, especially in the event of a mechanical complication of this procedure such as coronary artery perforation.

**Summary of the case:** We report the case of a patient who presented with early pericarditis after angioplasty complicated by coronary perforation.

It is about a 58-year-old patient admitted for angioplasty of a chronic total occlusion of the right coronary artery; the angioplasty resulted in a coronary perforation through the guidewire 0.014. The patient remained asymptomatic and hemodynamically stable. Faced with the failure to exclude the perforation by balloon inflation, we decided to perform a distal fat embolization to seal the perforation.

Twelve hours after the procedure, the patient presented with intense chest pain with a concave elevation of the ST segment in the anterior and lateral leads with an increase in troponins level and a worsening of the pericardial effusion on echocardiography motivate an emergency coronary angiography which confirms the absence of an active perforation. An elevated C-reactive protein level confirmed the diagnosis of acute pericarditis leading to the start of anti-inflammatory treatment allowing sedation of the pain, normalization of the ECG and regression of the effusion thus authorizing the patient's discharge 5 days later.

Coronary perforation during angioplasty has, in addition to these immediate hemodynamic consequences, a risk of progression to so-called traumatic acute pericarditis and should prompt rigorous monitoring of inflammatory signs and the systematic initiation of anti-inflammatory treatment (Aspirin or non-steroidal anti-inflammatory drugs and Colchicine) after the acute management of the perforation in order to reduce the long-term morbidity and mortality of this complication and the progression towards constriction.

**Keywords:** Case report • Chronic Total Occlusions (CTO) • Coronary perforation • Fat embolization • Pericarditis • Complication

**List of abbreviations:** CAG: Coronary Angiogram; CTO: Chronic Total Occlusion; DES: Drug Eluting Stent; ECG: Electrocardiogram; LVEF: Left Ventricle Ejection Fraction; PCI: Percutaneous Coronary Intervention; PCIS: Post-Cardiac Injury Syndrome; RAD: Right Anterior Descending; RCA: Right Coronary Artery

## Introduction

Acute pericarditis is an inflammatory condition of the pericardium that may or may not be accompanied by fluid effusion [1]. Viral etiology is the most common cause of acute pericarditis [1,2].

Acute pericarditis can rarely occur after an iatrogenic lesion of the pericardium such as that imposed by pericardial perforation, in this case referred to as pericardial injury syndrome [3,4]. We report here the case of a patient who developed acute pericarditis 12 hours after iatrogenic perforation of a right coronary artery occurring during angioplasty for Chronic Total Occlusion (CTO) of the latter.

## Case Presentation

We present the case of a 58-year-old patient, hypertensive, active smoker

**\*Address for Correspondence:** Nassime Zaoui, Department of Cardiology, EHS Draa Ben Khedda, PXH9+373, Draâ Ben Khedda, Algeria, Tel: 00213771815911, E-mail: nassime.zaoui@outlook.com

**Copyright:** © 2024 Zaoui N, et al. This is an open-access article distributed under the terms of the Creative Commons Attribution License, which permits unrestricted use, distribution, and reproduction in any medium, provided the original author and source are credited.

**Received:** 02 January, 2024, Manuscript No. JOV-24-125060; **Editor Assigned:** 04 January, 2024, PreQC No. P-125060; **Reviewed:** 16 January, 2024, QC No. Q-125060; **Revised:** 22 January, 2024, Manuscript No. R-125060; **Published:** 31 January, 2024, DOI: 10.37421/2471-9544.2024.10.222

and dyslipidemic admitted in our department for the management of angina with positive ischemic test. Clinical, biological, and ECG examination on admission were normal. Echocardiography revealed a normal LVEF (67% EF) with no hypokinesia and no pericardial effusion.

## Clinical findings

The patient was admitted to the cath lab for coronary angiography, which showed biconvex involvement with proximal tight stenosis of the circumflex and chronic total occlusion of the right coronary artery with TIMI 0 flow and distal recovery through the contralateral arteries through the septal arteries (Figures 1 and 2).

We started with an angioplasty of the CTO of the right coronary artery with AL1 guiding catheter (Amplatz Left) which was complicated by a type

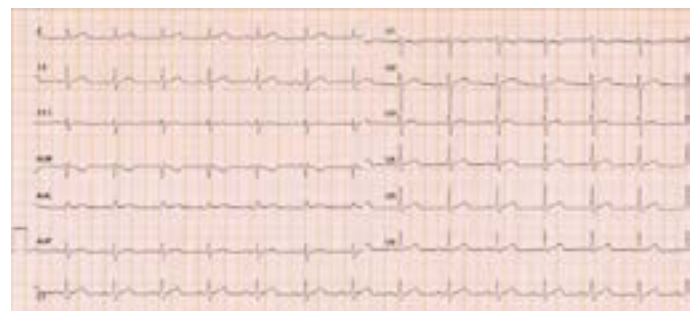

Figure 1. Normal ECG before PCI.

V perforation of the Ellis SG, et al. [3] classification with the 0.014 “PT2” guidewire in an asymptomatic and hemodynamically stable patient (Figure 3).

After observing the persistence of the perforation despite prolonged balloon inflations in the right coronary, we decided to perform a distal fat embolization. For this purpose, we took an EXPORT 6F thromboaspiration catheter which was placed on guidewire 0014 to the perforation site. Fat particles were removed by puncture from the groin crease and mixed with saline serum. This “fatty solution” was then injected through the thromboaspiration catheter followed by a flush of 10 ml of saline. The thromboaspiration catheter was then removed and contrast injections confirmed complete closure of the perforation with stabilization of the pericardial effusion on echocardiography, we therefore completed the angioplasty of the right coronary artery by placing a stent and planned to perform the procedure on the circumflex 1 month later.

### Diagnostic assessment


Twelve hours after the procedure, the patient presented with chest pain aggravated by deep inspiration, ECG revealed a concave elevation of the ST segment in the anterior and lateral leads with elevated troponin levels and worsening of pericardial effusion on echocardiography. An emergency coronary angiography was performed confirming the complete exclusion of the perforation and stent permeability (Figures 4 and 5).

An elevated C-Reactive Protein (CRP) level with hyper leukocytosis was found the next day, confirming the diagnosis of acute post-traumatic pericarditis.

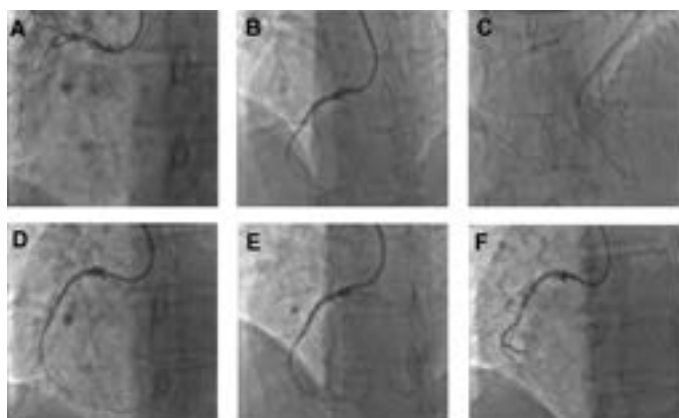
### Therapeutic intervention

The patient was put on Aspirin 500 mg × 3 daily and Colchicine 0.5 mg × 2 daily for one month.

### Follow-up and outcomes



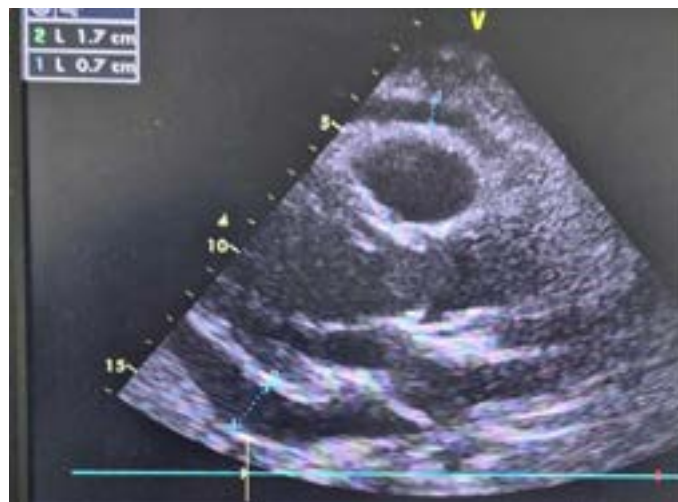
**Figure 2.** ELLIS classification and Type V perforation management **A)** Ping-pong technique: Inflate balloon over the first guidewire and introduce a second guiding-catheter with a second wire in the perforated artery, **B)** Coil deployment, **C)** Fatty embolization over a thrombectomy catheter and **D)** Half balloon pushed with a normal balloon till the perforation.



**Figure 3.** Coronary angiography of RCA, perforation and management **A)** RCA CTO, **B)** RCA wiring, **C)** Contralateral injection, **D)** Distal perforation and small pericardial effusion, **E)** Thrombectomy catheter for fatty embolization and **F)** **Result:** Perforation occluded after fatty embolization.



**Figure 4.** ECG 1-day post PCI showed Spodick's sign with depressed TP segment and ST-elevation (blue arrow).



**Figure 5.** Echocardiography 1 day post-PCI from sub-xiphoid view showed mild to moderate (7-17mm) pericardial effusion.

We observed a disappearance of symptoms and the ST segment elevation five days later and the clear regression of the pericardial effusion which regressed from 17 mm on Day 1 to 4 mm on Day 5, allowing the patient to be discharged.

The follow-up ultrasound performed 1 month later revealed a total disappearance of the pericardial effusion.

## Results and Discussion

Predictors of coronary perforation during PCI are the complexity of the lesions, the absence of downstream flow (TIMI 0); use more than 1 guidewire, especially when using stiff, tapered, or hydrophilic wires [3].

Coronary perforation causes mesothelial cell damage and blood rash in the pericardium causes an inflammatory and autoimmune response [2,3].

Post-Cardiac Injury Syndrome (PCIS) may be diagnosed if fulfilled 2 of 5 clinical criteria [4,5]:

- Fever without another etiology
- Pleuritic or pericarditis chest bread
- Pericardial Gold Pleural Rubs
- Pericardial effusion with elevated C-Reactive Protein (CRP).
- Pleural effusion with elevated C-Reactive Protein (CRP).

The key treatment is based on anti-inflammatories drugs (aspirin in anti-inflammatory doses and non-steroidal anti-inflammatory drugs) preferably combined with Colchicine from the outset, thus allowing pericardial healing, but above all the avoidance of recurrences and progression to constriction, which can be seen respectively in 10% and 2.8% of cases at 72 months without Colchicine [3,5].

The incidence of this complication after coronary perforation remains poorly known, but our case encourages rigorous monitoring of inflammatory signs after coronary perforation and systematic initiation of anti-inflammatory treatment in case of coronary perforation during PCI.

## Learning objectives

- To know how to identify and treat a PCIS.
- To discuss a systematic introduction of anti-inflammatory agents such as aspirin/Non-Steroid Anti-Inflammatory Drugs (NSAIDs) and colchicine after iatrogenic coronary perforation to avoid PCIS.

**Patient perspective:** The patient says he is asymptomatic and satisfied with the impact of the medical treatment on his pericarditis.

**Informed consent:** The patient consented to sharing and publishing his case and procedure images subject to anonymity.

## Conclusion

In addition to its immediate hemodynamic risk, coronary perforation during angioplasty can induce an inflammatory process leading in a more or less short period of time to acute pericarditis that can progress to pericarditis constriction.

This encourages monitoring for inflammatory signs and systematic initiation of anti-inflammatory therapy (Aspirin or non-steroidal anti-inflammatory drugs) combined with Colchicine after this complication in order to reduce medium- and long-term morbidity and mortality and prevent progression to pericardial constriction.

The primary take-away lesson of this case and impact on daily practice: This case demonstrates that after a well-managed coronary perforation and in the absence of an immediate adverse course, the installation of a PCIS lies in wait for the patient in the first hours after the procedure.

## Acknowledgement

None.

## Conflict of Interest

No conflict of interest.

## References

1. Adler, Yehuda, Philippe Charron, Massimo Imazio and Luigi Badano, et al. "2015 ESC Guidelines for the diagnosis and management of pericardial diseases." *Kardiologia Polska* 73 (2015): 1028-1091.
2. Christakopoulos, Georgios E, Georgios Christopoulos, Mauro Carlino and Omar M. Jeroudi, et al. "Meta-analysis of clinical outcomes of patients who underwent percutaneous coronary interventions for chronic total occlusions." *Am J Cardiol* 115 (2015): 1367-1375.
3. Ellis, Stephen G, Steven Ajluni, Anita Z. Arnold and Jeffrey J. Popma, et al. "Increased coronary perforation in the new device era. Incidence, classification, management and outcome." *Circ* 90 (1994): 2725-2730.
4. Sasse, Tom and Urs Eriksson. "Post-cardiac injury syndrome: Aetiology, diagnosis and treatment." *ESC E- J Cardiol* 15 (2017): 21-31.
5. Stathopoulos, Ioannis, Georgia Panagopoulos, Konstantinos Kossidas and Marcelo Jimenez, et al. "Guidewire-induced coronary artery perforation and tamponade during PCI: In-hospital outcomes and impact on long-term survival." *J Invasive Cardiol* 26 (2014).

**How to cite this article:** Zaoui, Nassime, Sabrina Benamara, Amina Boukabous and Nabil Irid. "Post-cardiac Injury Syndrome after Percutaneous Coronary Intervention: A Case Report." *J Vasc* 10 (2024): 222.