

White Matter Hyperintensities and their Location in Alzheimer's Disease

Reinhold Schmidt*, Anna Damulina and Lukas Pirpamer

Division of Neurogeriatrics, Department of Neurology, Medical University of Graz, Graz, Austria

*Corresponding author: Reinhold Schmidt, Division of Neurogeriatrics, Department of Neurology, Medical University of Graz, Auenbruggerplatz 22 8036 Graz, Austria, Tel: +43 316 385 83397; E-mail: reinhold.schmidt@medunigraz.at

Received date: March 11, 2019; Accepted date: March 25, 2019; Published date: March 31, 2019

Copyright: © 2019 Schmidt R, et al. This is an open-access article distributed under the terms of the Creative Commons Attribution License, which permits unrestricted use, distribution, and reproduction in any medium, provided the original author and source are credited.

Abstract

White matter hyperintensities (WMH) are areas of hyperintense signal within cerebral white matter which can be identified on T2-weighted fluid-attenuated inversion recovery (FLAIR) magnetic resonance imaging (MRI) scans. WMH are common in older individuals and in patients with small vessel disease-related ischemic brain injury. Increased WMH were also reported in patients with Alzheimer's disease (AD). Whether WMH can be a sign of early AD or the result of the pathophysiological mechanisms of AD is yet unclear. By its localization, all the white matter abnormalities can be divided into periventricular and deep WMH. Here we review the differences between periventricular and deep WMH in terms of pathophysiology, etiology and the neuroimaging characteristics in normal subjects and AD patients. Neuroimaging studies distinguish regional patterns in the WMH distribution between healthy aging controls and AD patients. Previous studies using different approaches have reported the prevalence of periventricular WMH in AD. Similar results were demonstrated in our recent study using lesion probability mapping in AD patients and age-matched controls. These results highlight the important etiological role of periventricular white matter damage in the pathogenesis of AD. It has been suggested that white matter lesions may disrupt cholinergic long projection fibers, thus confirming the possible contribution of WMH to the pathogenesis of cognitive decline in AD. It is possible that the effect of periventricular white matter abnormalities on cognitive function is typical for the early AD stages before cortical neurodegeneration begins to prevail over the relatively subtle effects of periventricular white matter damage in patients with dementia. The pathogenesis of the WMH spatial distribution in AD and their connection with cognitive impairment requires further research using new imaging techniques.

Keywords: White matter hyperintensities; Magnetic resonance imaging; Periventricular white matter; Alzheimer's disease

Introduction

White matter hyperintensities (WMH) are areas of hyperintense signal, which are typically detected on fluid-attenuated inversion recovery (FLAIR) brain magnetic resonance imaging (MRI). WMH are generally thought to result from small vessel disease-related ischemic brain injury [1], but there is also evidence for higher WMH frequency and extent in patients with Alzheimer's disease (AD) when compared to age-matched normal [2]. The pathophysiology of white matter damage in AD is not fully determined but probably heterogeneous. It has been shown that WMH in AD consist of myelin and axonal loss, gliosis, and spongiosis, and also damaged oligodendrocytes [3,4]. In addition, white matter abnormalities in AD brains demonstrated more activation of microglia when compared to pure small-vessel disease-related WMH [5]. Whether white matter damage can be a sign of early AD or the result of pathophysiological mechanisms of AD is yet unclear. Grimmer et al. [6] described an association between increased amyloid- β deposition and higher baseline white matter lesion load and previous findings suggest that WMH progression parallels clinical deterioration in AD [2,7-9]. In keeping with this finding, the Rotterdam Scan Study showed that individuals with higher severity of WMH had a higher risk for developing AD [10].

Pathophysiological Distinctions of Periventricular and Deep WMH in Normal Individuals and AD Patients

WMH can be divided by their location: deep WMH are situated in the subcortical white matter apart from the ventricle, whereas periventricular WMH appear directly adjacent to the lateral ventricle [11,12]. Periventricular changes usually include caps on the frontal and/or occipital horns and a pencil-thin lining around the lateral ventricles, while deep/subcortical white matter abnormalities present as punctate changes or beginning confluent or confluent changes [11]. The blood supply and structure of periventricular and deep white matter are different. Periventricular white matter consists of noncollateralizing ventriculofugal vessels arising from subependymal arteries and of a high density of long association fibers; whereas deep subcortical white matter is fed by medullary arteries arising from the cortical branches of middle cerebral arteries and contains a high density of short U-fibers [12].

Postmortem study of aging brain tissue revealed specific histopathological alterations in the areas of periventricular and deep WMH. Deep WMH are mainly characterized by arteriolosclerosis resulting in focal demyelination, gliosis and axonal loss, while periventricular WMH consist of a thin line of subependymal gliosis and an extensive band of white matter tissue with reduced staining of myelin [13]. Myelin rarefaction was determined with white matter damage and remyelination appears in response to the loss of myelin [14]. Indeed, the study of Simpson and co-authors showed an association of remyelination attempts with periventricular white matter lesions [15]. Major findings of periventricular white matter abnormalities are a loose network of myelinated bundles with a low

content of myelin and a high content of extracellular and periependymal fluid [13]. The distribution of extracellular fluid in the periventricular white matter lesions corresponded to the adjacent areas of ependymal breakdown and increased space between the loosely arranged myelinated fibers [16]. It was shown that destruction of the ependymal lining of the ventricles correlates with periventricular white matter lesions [15]. Ependymal lining breakdown can lead to the ingress of cerebrospinal fluid into the white matter, leading to the pallor of the white matter and a hyperintensive MRI signal, or may be due to ventricular enlargement caused by atrophy of the white matter [3]. Typical periventricular lesions contain higher levels of ramified activated microglia and loss of ventricular ependymal [14]. In addition, disruption of the ependymal layer, called ependymitis granularis, is a common phenomenon in periventricular WMH, characterized by focal destruction of the ependymal lining and astrocytic gliosis [13,16]. Although periventricular and deep WMH exhibit many pathophysiological similarities, disruption of the ependymal lining, low content of myelin and subependymal gliosis related to periventricular white matter damage, reveal some differences in their pathogenesis, potentially associated with cerebrospinal fluid leakage [15].

Breakdown of the ventricular lining and the blood-brain barrier is considered to also play an important role in the AD pathophysiology [3,17]. Post-mortem tissue analysis indicates blood-brain barrier damage in mild cognitive impairment and patients with early AD

before brain atrophy or dementia in the hippocampus, grey and white matter and shows the pathophysiological link between cerebrospinal fluid reduction and blood-brain barrier breakdown [17]. In this context, it is important to note that pathology studies of the brains from AD patients showed degraded myelin vesicles, gliosis, and myelin loss in periventricular white matter adjacent to a denuded ependymal layer [4]. Histopathologically, the loss of myelinated axons in the deep white matter was also more severe in AD patients than in controls [3]. A recent study by Schwardfager et al. [18] showed that periventricular WMH were associated with an increase in peripheral inflammatory markers in patients with AD but not in healthy elderly, but no relationship was found with deep white matter damage.

Spatial Pattern of the WMH Distribution in AD

In line with the observation that periventricular and deep/subcortical white matter may be differentially affected by AD numerous neuroimaging studies explored differences in the spatial distribution of WMH between AD patients and healthy aging controls. So far, they reported higher WMH load in AD patients in periventricular [11,19-20] but also in subcortical frontal and parietal white matter [20] by using visual rating scales. Visual rating provides only gross information on the location of WMH as it focuses predominantly on lesion severity.

Authors	Year published	Study participants	Method of WMH assessment	Results
Fazekas et al. [11]	1987	12 AD patients, 4 multi-infarct dementia and 9 age-matched controls	Visual rating scale	WMH in the deep white matter, noted in 60% of both AD patients and controls. A significant number of AD exhibited a more extensive smooth "halo" of periventricular hyperintensity when compared with controls.
Schelens et al. [20]	1992	29 AD patients and 24 age-matched healthy elderly	Visual rating scale	Periventricular and lobar WMH were higher in AD patients than in age-matched controls.
Barber et al. [19]	1999	27 patients with dementia with Lewy bodies, 28 AD, 25 vascular dementia patients, and 26 normal controls	Visual rating scale	Total deep and periventricular WMH were more severe in all dementia groups than in controls. Deep WMH were higher in patients with vascular dementia than those with dementia with Lewy bodies or AD.
Yoshita et al. [21]	2006	26 mild AD, 28 MCI patients, and 33 normal controls	Lesion mapping probability	Significant differences were seen between normal controls and AD in posterior periventricular regions and the splenium of the corpus callosum.
Holland et al. [22]	2008	32 cerebral amyloid angiopathy patients, 41 AD or MCI, and 29 healthy aging	Lesion mapping probability	After controlling for total WMH volume no consistent difference in the spatial distributions was found between groups.
van Straaten et al. [7]	2008	amnesic-MCI 152 study participants	Visual rating scale	55 of the 152 amnesic-MCI subjects progressed to AD. Only periventricular WMH were related to an increased risk of AD within three years.
Targosz-Gajniak et al. [2]	2009	10 patients with amnesic-MCI, 11 with mild AD, 17 with moderate AD and 15 with severe AD	Visual rating scale	WMH were seen in almost all patients with AD and MCI. The severity of lesions in the periventricular region increased with the progression of the disease.
Kim et al. [9]	2015	622 MCI participants	Visual rating scale	139 patients converted to all-cause dementia over 14.3 months. Severe periventricular WMH predicted incident all-cause dementia and AD.

Table 1: Summary of white matter hyperintensities regional distribution studies in Alzheimer's disease. (WMH: White Matter Hyperintensities; AD: Alzheimer's Disease; MCI: Mild Cognitive Impairment)

More sensitive for detecting differences in the spatial distribution of white matter abnormalities between groups is MRI-based lesion probability mapping, a powerful tool for the quantitative voxel-wise evaluation of focal brain abnormalities. Voxel-wise studies of WMH in AD patients demonstrated the posterior periventricular regions and corpus callosum [21] as being preferentially affected, but there have also been studies that did not show any consistent difference in lesion location when compared to controls [22]. A summary of WMH studies in AD is presented in the Table 1.

We recently conducted a lesion probability mapping study in AD [23]. This study extended previous investigations by comparing the extent and spatial distribution of WMH between 130 AD cases and age-matched elderly normal individuals with similar total WMH volume. Manually segmented FLAIR WMH masks were non-linearly registered to a template and voxel-based probability mapping using FSL randomize tool, presented by non-parametric permutation tests, and was performed. Significant clusters were defined by means of the threshold-free cluster-enhancement. There was no difference in cardiovascular risk factors between the two investigational groups. The result of the voxelwise paired t-test comparison of lesion masks in AD patients versus age-matched HC, overlaid on the T1-MNI brain is shown in the Figure 1. AD patients had a higher frequency of WMH in periventricular voxels even if we controlled for ventricular volume, hypertension, diabetes mellitus, hypercholesterolemia, coronary artery disease, smoking, sex and age. The periventricular WMH load did not predict future cognitive decline of AD patients, however. It is important to note that our voxel-wise approach demonstrated a high frequency of periventricular white matter lesions in AD patients in a hypothesis-free and, by in large, investigator-independent manner. These results highlight the important etiological role of periventricular white matter damage in the pathogenesis of AD. Concordance of our data with the results of previous studies using different approaches [2,7-9,19-21] underscores the validity of our findings.

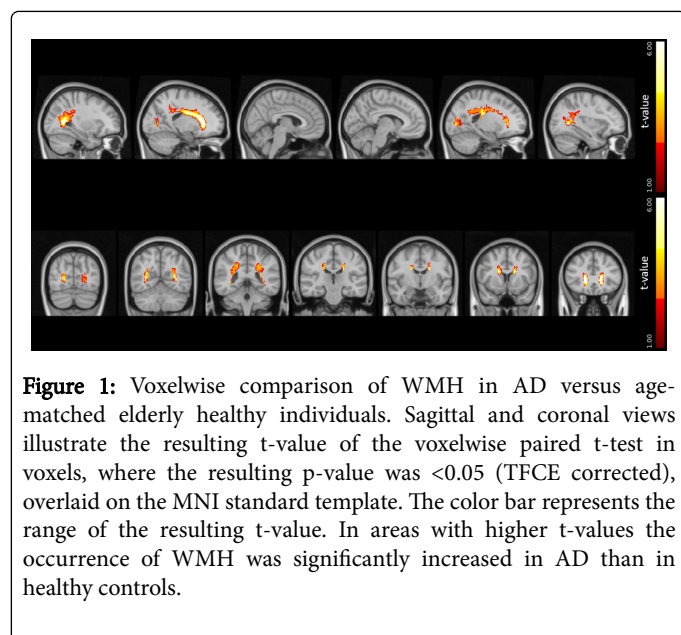


Figure 1: Voxelwise comparison of WMH in AD versus age-matched elderly healthy individuals. Sagittal and coronal views illustrate the resulting t-value of the voxelwise paired t-test in voxels, where the resulting p-value was <0.05 (TFCE corrected), overlaid on the MNI standard template. The color bar represents the range of the resulting t-value. In areas with higher t-values the occurrence of WMH was significantly increased in AD than in healthy controls.

Periventricular WMH and Deafferentiation of Cholinergic Fibres

Periventricular WMH can disrupt cholinergic long projection fibers that travel from subcortical regions to the cortex [24]. Consistent with these assumptions, Schwarz et al. [25], by using immunohistochemical tracings, demonstrated that differentiation of cholinergic fibers in AD patients at the intersection with strategically located WMH contributed to cognitive impairment. Affecting long fiber tracts of periventricular WMH that connect several distant cortical areas with each other could also explain the association of WMH with the progression of medial temporal lobe atrophies in AD [26]. Indeed, a link of periventricular WMH with more rapid progression of cognitive impairment was reported in both elderly individuals [27] and in patients with mild cognitive impairment [7,28]. Periventricular white matter lesion load significantly predicted incident AD and this association was independent of deep WMH severity in patients with mild cognitive impairment [9]. In the context of our seemingly contrasting finding that periventricular WMH were unrelated to faster cognitive decline in AD patients Makino's study is of interest [28]. These authors described that in the amnesic mild cognitive impairment group, periventricular WMH were correlated with cognitive decline; whereas in the AD patients, such associations were not observed. It is possible that the effect of periventricular white matter abnormalities on cognitive function plays an important role in normal aging and early stages of AD while in patients with dementia the cognitive consequences of cortical degeneration prevail over the relatively subtle effects of periventricular white matter damage. Richter et al. [29] using cortical acetylcholinesterase activity as a marker for the integrity of the cortical cholinergic system showed that cholinergic deficiency is already present at the mild cognitive impairment stage of AD. Hence, in early AD WMH may affect cholinergic neurons and exacerbate co-existing cortical cholinergic deficits. Further research is needed to expand our knowledge about the effects of WMH in general, and periventricular white matter damage in particular, in patients with AD, and to explore preventive possibilities that may result from this association.

References

1. Pantoni L, Garcia JH (1997) Pathogenesis of leukoaraiosis: A review. *Stroke* 28: 652-659.
2. Targosz-Gajniak M, Siuda J, Ochudlo S, Opala G (2009) Cerebral white matter lesions in patients with dementia - from MCI to severe Alzheimer's disease. *J Neurol Sci* 283: 79-82.
3. Scheltens P, Barkhof F, Leys D, Wolters EC, Ravid R, et al. (1995) Histopathologic correlates of white matter changes on MRI in Alzheimer's disease and normal aging. *Neurology* 45: 883-888.
4. Zhan X, Jickling GC, Ander BP, Liu D, Stamova B, et al. (2014) Myelin injury and degraded myelin vesicles in Alzheimer's disease. *Curr Alzheimer Res* 11: 232-238.
5. Gouw AA, Seewann A, Vrenken H, van der Flier WM, Rozemuller JM, et al. (2008) Heterogeneity of white matter hyperintensities in Alzheimer's disease: Post-mortem quantitative MRI and neuropathology. *Brain* 131: 3286-3298.
6. Grimmer T, Faust M, Auer F, Alexopoulos P, Förstl H, et al. (2012) White matter hyperintensities predict amyloid increase in Alzheimer's disease. *Neurobiol Aging* 33: 2766-2773.
7. Van Straaten EC, Harvey D, Scheltens P, Barkhof F, Petersen RC, et al. (2008) Periventricular white matter hyperintensities increase the likelihood of progression from amnesic mild cognitive impairment to dementia. *J Neurol* 255: 1302-138.

8. Brickman AM, Zahodne LB, Guzman VA, Narkhede A, Meier IB, et al. (2015) Reconsidering harbingers of dementia: Progression of parietal lobe white matter hyperintensities predicts Alzheimer's disease incidence. *Neurobiol Aging* 36: 27-32.
9. Kim S, Choi SH, Lee YM, Kim MJ, Kim YD, et al. (2015) Periventricular white matter hyperintensities and the risk of dementia: A CREDOS study. *Int Psychogeriatr* 27: 2069-2077.
10. Prins ND, van Dijk EJ, den Heijer T, Vermeer SE, Koudstaal PJ, et al. (2004) Cerebral white matter lesions and the risk of dementia. *Arch Neurol* 61: 1531-1534.
11. Fazekas F, Chawluk JB, Alavi A, Hurtig HI, Zimmerman RA (1987) MR signal abnormalities at 1.5 T in Alzheimer's dementia and normal aging. *AJR Am J Roentgenol* 149: 351-356.
12. Kim KW, MacFall JR, Payne ME. (2008) Classification of white matter lesions on magnetic resonance imaging in elderly persons. *Biol Psychiatry* 64: 273-280.
13. Fazekas F, Schmidt R, Scheltens P (1998) Pathophysiologic mechanisms in the development of age-related white matter changes of the brain. *Dement Geriatr Cogn Disord* 1: 2-5.
14. Fernando MS, Simpson JE, Matthews F, Brayne C, Lewis CE, et al. (2006) White matter lesions in an unselected cohort of the elderly: Molecular pathology suggests origin from chronic hypoperfusion injury. *Stroke* 37: 1391-1398.
15. Simpson JE, Fernando MS, Clark L, Ince PG, Matthews F, et al. (2007) White matter lesions in an unselected cohort of the elderly: Astrocytic, microglial and oligodendrocyte precursor cell responses. *Neuropathol Appl Neurobiol* 33: 410-419.
16. Sze G, De Armond SJ, Brant-Zawadzki M, Davis RL, Norman D, et al. (1986) Foci of MRI signal (pseudo lesions) anterior to the frontal horns: Histologic correlations of a normal finding. *AJR Am J Roentgenol* 147: 331-337.
17. Zhan X, Stamova B, Sharp FR (2018) Lipopolysaccharide associates with amyloid plaques, neurons and oligodendrocytes in Alzheimer's disease brain: A Review. *Front Aging Neurosci* 10: 42.
18. Swardfager W, Yu D, Ramirez J, Cogo-Moreira H, Szilagyi G, et al. (2017) Peripheral inflammatory markers indicate microstructural damage within periventricular white matter hyperintensities in Alzheimer's disease: A preliminary report. *Alzheimers Dement (Amst)* 7: 56-60.
19. Barber R, Scheltens P, Gholkar A, Ballard C, McKeith I, et al (1999) White matter lesions on magnetic resonance imaging in dementia with Lewy bodies, Alzheimer's disease, vascular dementia, and normal aging. *J Neurol Neurosurg Psychiatry* 67: 66-72.
20. Scheltens P, Barkhof F, Valk J, Algra PR, van der Hoop RG et al. (1992) White matter lesions on magnetic resonance imaging in clinically diagnosed Alzheimer's disease: Evidence for heterogeneity. *Brain* 115: 735-748.
21. Yoshita M, Fletcher E, Harvey D, Ortega M, Martinez O, et al. (2006) Extent and distribution of white matter hyperintensities in normal aging, MCI and AD. *Neurology* 67: 2192-2198.
22. Holland CM, Smith EE, Csapo I, Gurol ME, Brylka DA, et al. (2008) Spatial distribution of white-matter hyperintensities in Alzheimer disease, cerebral amyloid angiopathy, and healthy aging. *Stroke* 39: 1127-1133.
23. Damulina A, Pirpamer L, Seiler S, Benke T, Dal-Bianco P et al. (2019) White matter hyperintensities in Alzheimer's disease: A lesion probability mapping study. *J Alzheimers Dis.*
24. Bohnen NI, Bogan CW, Müller MLTM (2009) Frontal and periventricular brain white matter lesions and cortical deafferentation of cholinergic and other neuromodulatory axonal projections. *Eur Neurol J* 1: 33-50.
25. Swartz RH, Sahlas DJ, Black SE (2003) Strategic involvement of cholinergic pathways and executive dysfunction: Does location of white matter signal hyperintensities matter? *J Stroke Cerebrovasc Dis* 12: 29-36.
26. de Leeuw FE, de Groot JC, Achten E, Oudkerk M, Ramos LM et al. (2001) Prevalence of cerebral white matter lesions in elderly people: A population based magnetic resonance imaging study. The Rotterdam Scan Study. *J Neurol Neurosurg Psychiatry* 70: 9-14.
27. De Groot JC, De Leeuw F-E, Oudkerk M, Van Gijn J, Hofman A, et al. (2002) Periventricular cerebral white matter lesions predict rate of cognitive decline. *Ann Neurol* 52: 335-341.
28. Makino T, Umegaki H, Suzuki Y, Yanagawa M, Nonogaki Z, et al. (2014) Relationship between small cerebral white matter lesions and cognitive function in patients with Alzheimer's disease and amnesic mild cognitive impairment. *Geriatr Gerontol Int* 14: 819-826.
29. Richter N, Beckers N, Onur OA, Dietlein M, Tittgemeyer M, et al. (2018) Effect of cholinergic treatment depends on cholinergic integrity in early Alzheimer's disease. *Brain* 141: 903-915.