

Voriconazole-Associated Periostitis in a Heart Transplant Patient

Miguel Hernandez Pampaloni*

505 Parnassus Avenue, M-396 San Francisco, CA, 94143, United States

Abstract

A 60 year-old female with a history of a heart transplant was treated with voriconazole for presumed pulmonary aspergillosis. After approximately three months, she began to experience progressively worsening musculoskeletal pain. Her presentation was notable for widespread tenderness, a lack of digital clubbing, and elevated alkaline phosphatase. Bone scintigraphy demonstrated increased activity at multiple locations correlating with the patient's pain. Periostitis was identified in these locations on radiographs. A few months after discontinuing voriconazole, the patient's pain had resolved, alkaline phosphatase had normalized, and abnormal activity on scintigraphy had markedly improved.

Introduction

Voriconazole is commonly used for the treatment and prophylaxis of invasive fungal infections in both immunocompetent and immunocompromised patients. Established adverse effects include visual disturbances, hepatic toxicity, and photosensitivity [1]. Recent reports have described painful periostitis in heart and lung transplant patients receiving voriconazole for treatment or prophylaxis of invasive fungal infections.

Case Report

A 60 year-old female with a history of a heart transplant was treated with voriconazole for presumed pulmonary aspergillosis. After approximately three months, she began to experience right arm pain. One month later, she was in a motor vehicle collision, and she attributed subsequent pain to that event. Her pain progressively worsened, spreading to her upper arms, thighs, hips, knees, and hands. Erythrocyte sedimentation rate and C-reactive protein were elevated, but other inflammatory markers including antinuclear antibodies, anti-double-stranded DNA antibody, and anti-histone antibody were negative.

Voriconazole was discontinued after approximately five months, and the patient was hospitalized for pain control and further work-up. Rheumatology was consulted for possible voriconazole-associated periostitis. Physical exam demonstrated tenderness to palpation at the shoulders and thighs without synovitis of the hands or digital clubbing. Laboratory results were notable for alkaline phosphatase of 304 units/liter at the time of admission (normal range: 31-95 units/liter). Bone specific alkaline phosphatase was also elevated at 90.8 micrograms/liter (normal range: 5.6-29 micrograms/liter). A technetium-99m Methylene Diphosphonate (MDP) bone scan (Figure 1A), a CT chest (Figure 2A), and a radiographic bone survey (Figure 2B, 2C) were obtained. The bone scan demonstrated multiple foci of cortical MDP activity predominantly at the proximal extremities in a relatively symmetric distribution. Radiographs demonstrated periostitis at these locations, which correlated with the patient's pain.

When the patient was discharged approximately 2 weeks later, her pain was improving and her alkaline phosphatase had decreased to 217 U/L. Alkaline phosphatase continued to trend down in the subsequent months. Follow-up bone scan (Figure 1B) approximately 5 months after voriconazole was discontinued demonstrated marked improvement in periostitis. By this time, alkaline phosphatase had normalized.

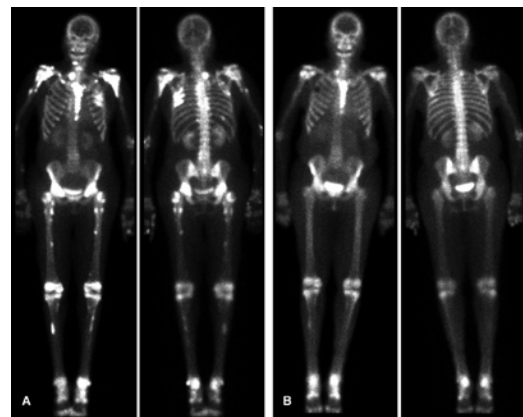


Figure 1: (A) Anterior and posterior whole-body images from a technetium-99m MDP bone scan acquired just after voriconazole was discontinued in a 60 year-old heart transplant patient. Relatively symmetric foci of cortical MDP activity are seen primarily at the proximal extremities and at multiple ribs consistent with periostitis. Diffuse MDP activity in the sternum is secondary to median sternotomy. A pacemaker generator shadow is present at the right upper chest. (B) Follow-up bone scan approximately five months after voriconazole was discontinued demonstrates marked improvement of periostitis.

Discussion

Periostitis associated with voriconazole therapy has been reported in patients with lung transplant [2,3], heart transplant [4,5], and other conditions [6]. These patients present with bone pain and elevated alkaline phosphatase. The lack of digital clubbing may help distinguish voriconazole-associated periostitis from secondary hypertrophic osteoarthropathy. Symptoms improve after voriconazole is discontinued, and radiographic and scintigraphic improvement is seen in the subsequent months.

There are two possible theories to explain the development of

*Corresponding author: Miguel Hernandez Pampaloni, 505 Parnassus Avenue, M-396 San Francisco, CA, 94143, United States, E-mail: miguel.pampaloni@ucsf.edu

Received June 12, 2012; Accepted June 27, 2012; Published July 02, 2012

Citation: Pampaloni MH (2012) Voriconazole-Associated Periostitis in a Heart Transplant Patient. J Clin Case Rep 2:166. doi:10.4172/2165-7920.1000166

Copyright: © 2012 Pampaloni MH. This is an open-access article distributed under the terms of the Creative Commons Attribution License, which permits unrestricted use, distribution, and reproduction in any medium, provided the original author and source are credited.

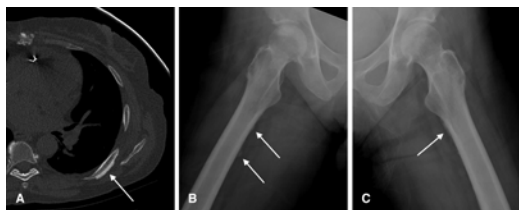


Figure 2: (A) CT chest demonstrating periostitis in a left posterior rib. Frog-leg views of the right (B) and left (C) femur from a radiograph bone survey demonstrate multiple foci of periostitis.

periostitis in patients treated with voriconazole. One is based on the fact that fluorine is organically bound in voriconazole and 5% of it is metabolized to free fluoride. It is therefore possible that voriconazole, via hepatic oxidative metabolism, results in unbound fluoride metabolites that cause variably elevated fluoride levels after extended use in predisposed patients via pharmacogenomic variations in drug metabolism. A second possibility is that renal insufficiency predisposes individuals to fluoride accumulation, because its renal clearance is directly related to glomerular filtration rate.

Differently from other reported cases, symptoms can develop shortly after voriconazole initiation. Recognition of this condition is important since discontinuation typically leads to prompt resolution of often disabling pain related to periostitis.

References

1. Lass-Flörl C (2011) Triazole antifungal agents in invasive fungal infections: a comparative review. *Drugs* 71: 2405-2419.
2. Chen L, Mulligan ME (2011) Medication-induced periostitis in lung transplant patients: periostitis deformans revisited. *Skeletal Radiol* 40: 143-148.
3. Wang TF, Wang T, Altman R, Eshaghian P, Lynch JP 3rd, et al. (2009) Periostitis secondary to prolonged voriconazole therapy in lung transplant recipients. *Am J Transplant* 9: 2845-2850.
4. Wermers RA, Cooper K, Razonable RR, Deziel PJ, Whitford GM, et al. (2011) Fluoride excess and periostitis in transplant patients receiving long-term voriconazole therapy. *Clin Infect Dis* 52: 604-611.
5. Wise SM, Wilson MA (2011) A case of periostitis secondary to voriconazole therapy in a heart transplant recipient. *Clin Nucl Med* 36: 242-244.
6. Rossier C, Dunet V, Tissot F, Aubry-Rozier B, Marchetti O, et al. (2012) Voriconazole-induced periostitis. *Eur J Nucl Med Mol Imaging* 39: 375-376.