

Vision Loss after Endoscopic Sinus Surgery: A First Case Report Assessed by OCT and VEP

Anastasios Lavaris, Tryfon Rotsos and Marilita M Moschos*

Department of Ophthalmology, University of Athens, Athens, Greece

Abstract

Background: Purpose of this case report is to describe, for the first time in literature assessed by optical coherence tomography (OCT) and visual evoked potentials (VEP), a rare case of partially reversible unilateral vision loss accompanied by retrobulbar optic neuritis symptomatology, after nasal polyps removal using endoscopic sinus surgery (ESS) technique.

Case presentation: A 41-year old Greek male developed unilateral vision loss, partially reversible within 72 hours, reduced color vision, superior scotoma and retrobulbar pain on eye movement immediately after recovering from nasal polyp removal with (ESS) technique. He underwent complete ophthalmological examination including optical coherence tomography, fluorescein angiography, visual fields and visual evoked potentials. A magnetic resonance imaging (MRI), neurological examination and laboratory evaluation were also performed revealing no abnormalities.

Conclusions: Sinus surgeons and ophthalmologists should be familiar with the possibility of irreversible visual impairment after endoscopic sinus surgery and enhance collaboration for facilitating better recognition and early treatment.

Keywords: Sinus surgery; Optic neuritis; VEP; OCT; Vision loss

Introduction

Nasal polyps are non-malignant overgrowths of the nasal and paranasal sinuses mucosa. They show increased incidence in patients with chronic rhinosinusitis and allergic asthma [1,2]. Since its introduction in the mid- 1980's endoscopic sinus surgery (ESS) has become the technique of choice for invasive chronic rhinosinusitis treatment. Although, and despite its continuous development over the past three decades complications may still occur, with an overall major complication rate of 1% (most common major complications are cerebrospinal fluid leakage 0.17% and orbital injury 0.07%) [3,4]. Purpose of this case report is to emphasize on the ophthalmic effects of the endoscopic sinus surgery and the fact that despite the advances in the ESS technique, serious ophthalmic complications such as optic neuritis may occur. Also to the best of our knowledge this is the first reported case of sinus surgery associated optic neuritis documented by optical coherence tomography (OCT) and visual evoked potentials (VEP).

Case Report

A 41-year old Greek man with no significant medical history, apart from chronic rhinosinusitis underwent ESS for right paranasal sinus polyposis under general anaesthesia. No intraoperative complications were reported and the surgery was completed without any incident. The patient had no diabetes mellitus, hypertension nor any other systemic vascular disease. Immediately after recovering from the anaesthesia the patient complained for vision loss, reduced color perception, retrobulbar pain worsened on eye movement and total superior scotoma on his right eye. He was then referred to the Electrophysiology Department of Athens University and underwent a complete ophthalmological examination. Visual acuity was 60/60 on his left and 30/60 on his right eye, which increased to 45/60 during the next 72 hours and remains stable since then (follow up examinations were conducted 3 and 6 months post-operatively). Pupillary reflexes examination revealed slightly reduced direct pupillary reflex and relative afferent pupillary defect (RAPD) on the right eye. Fundus examination was performed revealing no abnormalities including the optic discs (Figure 1). An MRI of the orbits and brain (with gadolinium enhancement) was performed, to rule-out other conditions affecting

the optic nerve (e.g. Multiple Sclerosis, tumor, Devic's disease, vascular abnormalities), accompanied by blood tests and a thorough neurological examination. All tests conducted were negative. A visual field examination was performed revealing a dense superior scotoma that occupied the upper-half of his visual field and severe generalized depression of sensitivity (Figure 2); left eye's examination did not reveal anything abnormal. OCT of the macula and optic nerve head on both eyes did not demonstrate any anatomical lesion (Figure 1). Fluorescein angiography was also performed and was also negative. Concerning VEP findings, amplitude of P100 was significantly decreased in the right eye in comparison to the left eye. Peak time of P100 was normal in both eyes (Figure 2).

All above described examinations were performed 48-72 hours postoperatively. Follow-up examinations were conducted 3 and 6 months later, including visual acuity, color sensitivity, OCT and visual fields. VA remained 45/60, OCT and visual fields remained unchanged.

Discussion

Two decades ago, grabbing forceps were used by sinus surgeons to strip away mucosa and extirpate soft tissue, followed by the development of suction forceps. The rate of aspiration and speed of the blade is controlled by the surgeon. Despite its advantages [5], use of the microdebrider can, without entering the orbit, lead to injury to vital orbital structures [6]. Vision loss is an infrequent complication of ESS [7]. In this report, we describe a healthy male from our clinic who presented with acute and permanent vision impairment, documented

*Corresponding author: Marilita M Moschos, Department of Ophthalmology, University of Athens, Athens, Greece, Tel: +306944887319; E-mail: moschosmarilita@yahoo.fr

Received April 13, 2016; Accepted June 16, 2016; Published June 21, 2016

Citation: Lavaris A, Rotsos T, Moschos MM (2016) Vision Loss after Endoscopic Sinus Surgery: A First Case Report Assessed by OCT and VEP. J Clin Case Rep 6: 806. doi:10.4172/2165-7920.1000806

Copyright: © 2016 Lavaris A, et al. This is an open-access article distributed under the terms of the Creative Commons Attribution License, which permits unrestricted use, distribution, and reproduction in any medium, provided the original author and source are credited.

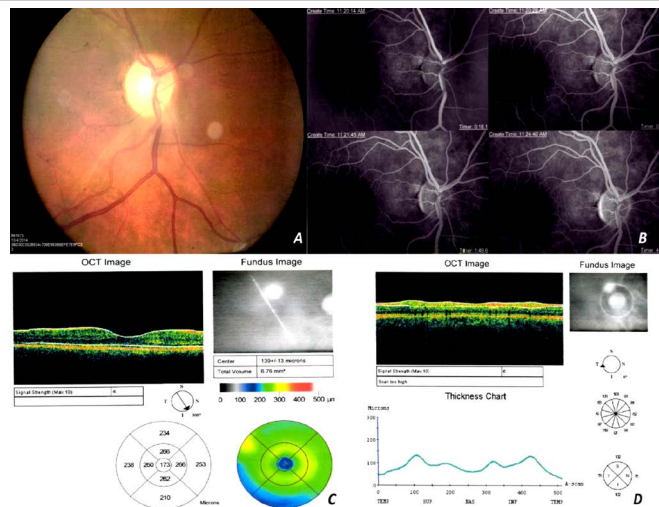


Figure 1: Fundus image including the right ONH at presentation (A). Fluorescein angiography of the right eye at presentation, revealing no leakage (B). OCT scan of the right macula (C) and right ONH (D) showed no abnormalities.

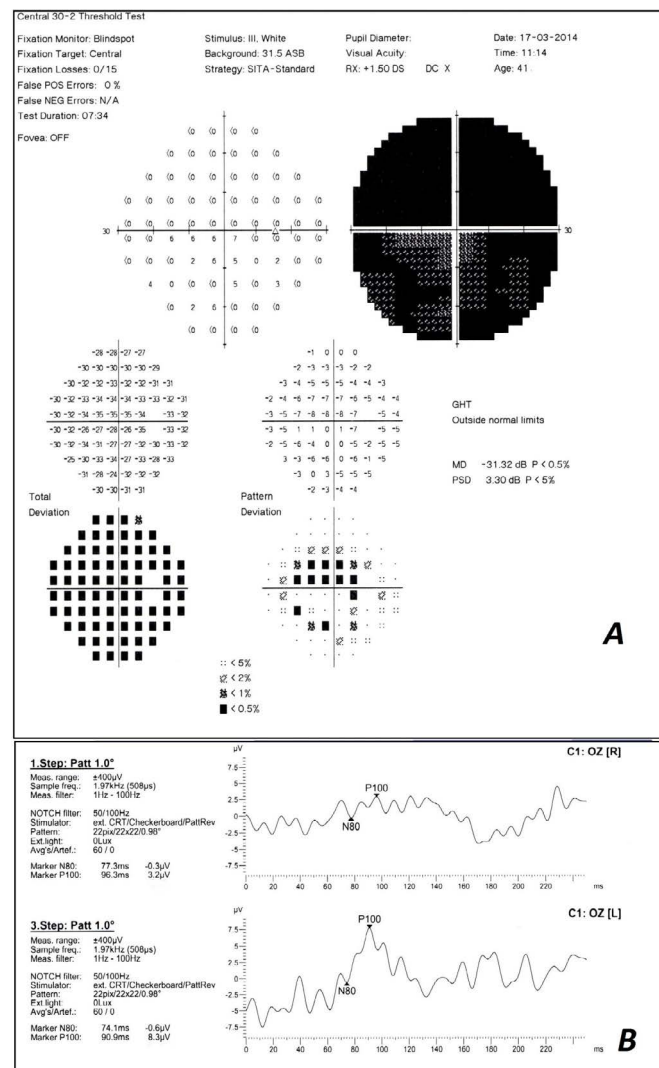


Figure 2: Automated Humphrey visual field of the patient's right eye revealing a total superior scotoma and generalized sensitivity reduction (A). VEP amplitude of the right eye is greatly decreased. Amplitude of P100 of the left eye is normal (B).

for the first time by VEP and OCT, with no clinical or radiographic findings, highlighting the variety of mechanisms that may be involved in the ophthalmic complications associated. In our patient the absence of fundoscopic or radiographic findings cannot define the underlying mechanism of optic nerve injury. MRI images excluded an orbital hematoma causing a compressive optic neuropathy. The other possible mechanism of optic nerve injury in our patient is direct trauma from the use of cautery, not visible by fundoscopy, as it does not involve the optic nerve head. VEP recording showed decreased amplitude of P100 in our patient and the diagnosis of optic neuritis was made, even in the absence of optic nerve head involvement. To the best of our knowledge this is the first reported case of optic neuritis secondary to sinus surgery, documented by VEP and OCT. Sinus surgery can cause major complications in the eye. We believe that both sinus surgeons and ophthalmologists should be familiar with the possibility of irreversible visual impairment after ESS and should enhance collaboration for facilitating better recognition and potential early treatment.

References

1. Settipane GA, Chafee FH (1977) Nasal polyps in asthma and rhinitis. A review of 6,037 patients. *J Allergy Clin Immunol* 59: 17-21.
2. Fokkens W, Lund V, Mullol J (2007) European position paper on rhinosinusitis and nasal polyps 2007. A summary for otorhinolaryngologists. *Rhinol* 45: 97-101.
3. Ramakrishnan VR, Kingdom TT, Nayak JV, Hwang PH, Orlandi RR (2012) Nationwide incidence of major complications in endoscopic sinus surgery. *Int Forum Allergy Rhinol* 2: 34-39.
4. Hosemann W, Draf C (2013) Danger points, complications and medico-legal aspects in endoscopic sinus surgery. *GMS Curr Top Otorhinolaryngol Head Neck Surg* 12: 06.
5. Singh R, Hazarika P, Nayak DR, Balakrishnan R, Gangwar N, et al. (2013) A comparison of microdebrider assisted endoscopic sinus surgery and conventional endoscopic sinus surgery for nasal polypi. *Indian J Otolaryngol Head Neck Surg* 65: 193-196.
6. Stankiewicz JA, Lal D, Connor M, Welch K (2011) Complications in endoscopic sinus surgery for chronic rhinosinusitis: a 25-year experience. *Laryngoscope* 121: 2684-2701.
7. Krings JG, Kallogjeri D, Wineland A, Nepple KG, Piccirillo JF, et al. (2014) Complications of primary and revision functional endoscopic sinus surgery for chronic rhinosinusitis. *Laryngoscope* 124: 838-845.