

Utility of the Inside-Out Technique for Pediatric Occipital Cervical Fusion and Correction of the Clivoaxial Angle: A Case Illustration

Faheem A. Sandhu* and Daniel R. Felbaum

Department of Neurosurgery, Medstar Georgetown University Hospital, Washington DC, USA

Introduction

A variety of techniques exist for tackling stabilization of the craniocervical junction. Historically, craniocervical instability was treated with a simple bone autograft onlay technique and a halo-vest to immobilize the neck and skull [1-3]. Because of fusion failures and patient morbidity associated with use of a halo-vest, surgical techniques have moved toward provision of immediate internal stabilization [3]. Currently, modern internal fixation techniques exist that provide an array of occipital plate constructs to achieve proper fusion through rigid stabilization of the craniocervical junction. The majority of these available constructs require an intact midline keel to allow for fixation of the occiput to the cervical spine [4,5]. In 1999, Pait et al., described an alternative technique, the “inside-out” method that provides a way to treat craniocervical instability in patients [6]. Subsequently, Sandhu et al., utilized this technique in achieving 100% fusion in a group of 21 patients with rheumatoid arthritis [5]. Using bilateral inside-out fixation to the occiput, they achieved bony fusion in all patients available for follow-up at a minimum of 7 months. The inside-out technique has been used successfully to treat a variety of conditions in both adults and children. It can also be used in the setting of previous suboccipital craniectomy without compromising fixation or fusion; use of this technique can be quite advantageous in certain situations such as in the setting of a suboccipital craniectomy and in patients with thin occipital bone [4,6].

Case Illustration

An 11 year-old male with genetically confirmed Ehlers-Danlos Syndrome (EDS) presented with progressive neck pain occurring on a daily basis. The pain was predominantly located at the base of his skull, worse in the upright position, and had been disabling. Because of the severity of his symptoms, he was unable to participate in regular school activities. Review of his imaging revealed a CXA of 124° with his neck in a neutral position (Figure 1). After a four week trial of immobilization in a hard cervical collar, the patient’s pain became more tolerable. Given the debilitating symptoms, response to immobilization, and acute CXA, the patient underwent an occiput to C3 instrumentation and fusion using the “inside-out” technique. One of the main considerations in choosing this technique relates to the thickness of the occipital bone. Review of pre-operative imaging revealed the patient’s occipital bone to be 4 mm in maximal thickness laterally and a small midline keel (Figures 2 and 3). In addition, rib autograft is harvested and employed for fusion. His immediate post-operative course was unremarkable with appropriate placement of hardware and correction of the CXA, now 161° (Figure 4a and 4b). He continued the hard cervical collar for 6 weeks, and then was instructed to wean use. At 9 months follow-up, the patient has resumed all his prior day-to-day activities and is able to return to his regular school work with complete resolution of his previous disabling headaches and neck pain. Consent was obtained from the patient’s parents regarding submission for case illustration and publication.

Description of “inside-out” technique

This operative technique has been described in detail elsewhere, but will be briefly described for purposes of illustration [5-8]. Upon induction of adequate general anesthesia and endotracheal intubation,

the patient is placed in the prone position with the Mayfield head holder for fixation. The head is slightly flexed. The patient is prepped in the normal fashion with IV antibiotics given and appropriate padding. A midline incision is made and subperiosteal dissection is performed to delineate C-1 and C-2 to be able to perform instrumentation. Instrumentation of C-1 and C-2 is performed in a previously described manner [9,10]. Open reduction is then performed under active fluoroscopy. This is achieved by adjusting the Mayfield holder by

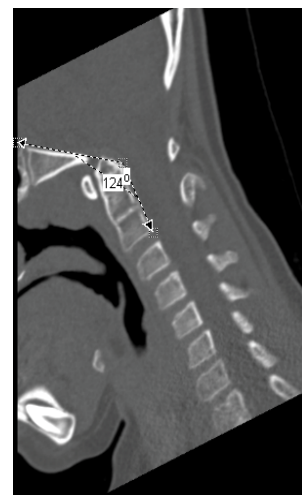


Figure 1: Pre-operative non-contrast CT of the cervical spine demonstrating the acuteness of the clivoaxial angle (125 degrees).

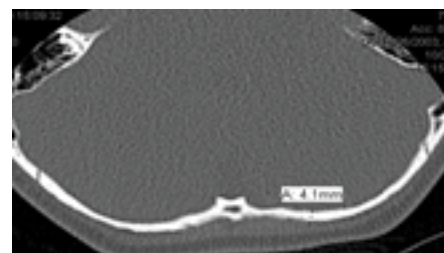


Figure 2: Non-contrast axial CT of the head demonstrating the thinness of the occiput (4.3 mm).

*Corresponding author: Faheem Sandhu, Department of Neurosurgery, Medstar Georgetown University Hospital 3800 Reservoir Road, NW 7th Floor PHC Washington, DC 20007, USA, Tel: 202-444-7315; Fax: 202-444-7344; E-mail: fasandhu@aol.com

Received December 29, 2015; Accepted January 19, 2016; Published January 21, 2016

Citation: Sandhu FA, Felbaum DR (2016) Utility of the Inside-Out Technique for Pediatric Occipital Cervical Fusion and Correction of the Clivoaxial Angle: A Case Illustration. J Spine 5: 278. doi:10.4172/2165-7939.1000278

Copyright: © 2016 Sandhu FA, et al. This is an open-access article distributed under the terms of the Creative Commons Attribution License, which permits unrestricted use, distribution, and reproduction in any medium, provided the original author and source are credited.

the operating surgeon [11]. Attention is then given towards cranial fixation. If the occipital bone is absent, then the bony borders are clearly identified and demarcated. For placement of the occipital bolt, a mark is identified in line with previously placed instrumentation. Then, an elliptical burr hole is placed 1 cm superior to the designated location of the occipital bolt. The burr hole is connected to this location with a trough that approximates the width of the occipital bolt. The bolt is positioned in the burr hole and placed in the desired location. A plate is placed over the bolt and held in place with a nut. A rod is then contoured to the patient's specifications. A rib graft is then harvested and split to increase surface area for bony fusion. This autograft is augmented with demineralized bone matrix. The wound is then closed in anatomic layers in the usual fashion.

Discussion

Because of the mobile topographical nature of the craniocervical junction, application of a rigid construct remains challenging [1]. Currently, the most widely used techniques employ a selection of contoured rods or plates to fixate the occiput. Generally speaking,

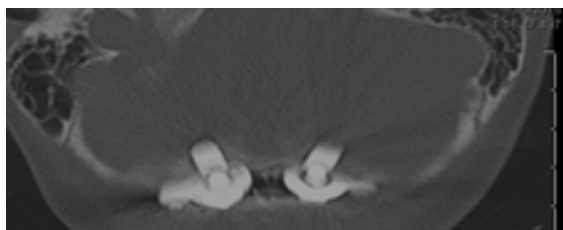


Figure 3: Non-contrast axial CT of the head with post-operative placement and fixation of the bolt/nut construct.

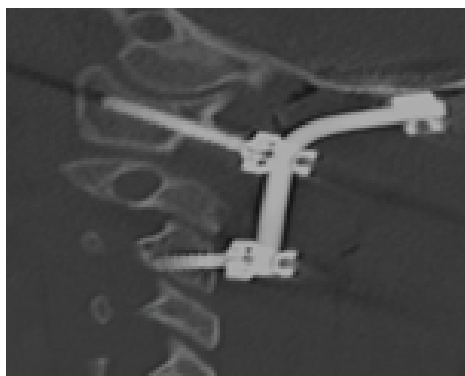


Figure 4a: Sagittal CT of the cervical spine demonstrating the post-operative occipital-cervical construct.

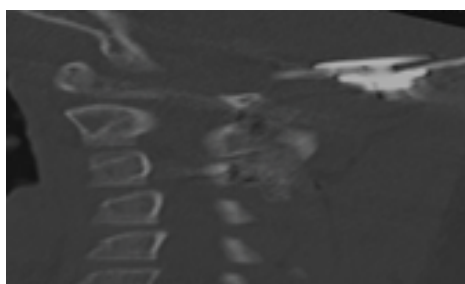


Figure 4b: Sagittal CT of the cervical spine demonstrating the bolt/nut construct in the appropriate location despite the thin bone in the pediatric occipital region.

this requires the presence of an intact and thick midline keel. From an anatomic standpoint, Ebraheim et al., noted maximal bone thickness central to the External Occipital Protruberance (EOP), with a range of 9.7-15.1 mm in adults [12]. In comparison, Geck et al., noted maximal occiput thickness with a range of 8.6 to 10.5 in children [13]. Notwithstanding, the midline keel provides the best bony purchase for pull out strength with decreased strength as one progresses radially outwards [12,14-17]. Strong fixation to thinner occipital bone lateral to the midline keel is not always possible, especially in children, due to bone thickness. Several studies investigating the “inside-outside” technique in pediatric populations have shown success [6,7]. In particular, the nut/bolt construct provides clinically adequate fixation despite findings that occipital bone thinner than 7 mm leads to motion stress in typical occipital screw instrumentation [6]. This may be related to the comparably improved pull out strength of “inside-outside” screws compared to occipital plate/screw constructs [18]. Furthermore, in biomechanical cadaveric studies of occiput-C1-C2 constructs, the laterality of the occipital screw placement may not be as significant a factor affecting overall rigidity of the occipitocervical construct [19,20]. Decidedly, an advantage of the “inside-out” technique is the placement of the bolt/nut construct does not depend on midline bone [5,6,21]. This is clinically relevant in patients who have had previous surgery, such as Chiari decompression or secondary to cranial settling after suboccipital decompression, such that the bolt/nut construct becomes an efficient technique to fixate the occiput [4]. In short, the inside outside technique has distinct advantages in a variety of conditions such as a small or absent midline keel, thinner occipital bone in children, metabolic conditions affecting bone quality. Also, the more lateral location of the of the nut/bolt portion maximizes the bony surface area available for fusion that may be a greater concern for other plate based constructs [7,22]. In addition, the nut/bolt construct requires a single point of fixation, thus a single burr hole, rather than multiple points of fixation that create a higher risk of dural or vascular injury. This would minimize blood loss, potential injury of an occipital sinus in children, while providing more than adequate fixation for fusion [3,6,7]. Looking at a variety of occipital-cervical constructs, Wolfla et al., and Oda et al., independently tested contemporary occipital cervical constructs and both groups concluded that screw-based constructs of the cervical spine provide appropriate support for unstable injuries in a cadaveric model, as compared to sublaminar wires or cable constructs [23,24].

A more recent technique to stabilize the occiput to the cervical spine is to place transcondylar screws with the aid of 3-D navigation [25-27]. Although this technique appears promising, there is limited published literature regarding safety [25,28]. The screw trajectory's proximity to the hypoglossal canal and jugular foramen may place the patients at an unnecessary risk for injury [27,28]. The “inside-out” technique offers high rates of fusion, biomechanical strength, without these added risks. In their original description, Pait et al. employed the technique in both adults and pediatric patients [6]. In their experience, they found the technique to be safe. Importantly, the technique allows rigid fixation to the thinner occipital bone in children. In addition, because the bolt/nut construct has significant resistance to pullout by dispersing force along a larger surface area of bone than a standard cortical screw, the presence of thin occipital bone is not a barrier to achieving strong fixation. Another advantage is the direct visualization of placement of the bolt/nut construct. Given the higher degree of dural vascularity and the higher presence of an occipital sinus, and lower tolerance of blood loss in children, the bolt/nut construct allows for a more controlled and potentially safer occipital fixation [7].

Although the “inside-out” technique shines in the setting of revision and pediatric surgery, it may be considered for use in primary occipital

cervical fusions in an adult setting. Sandhu et al., documented their experience treating rheumatoid arthritis patients with craniocervical instability. They had no complications associated with instrumentation and a 100% fusion rate, excluding the lone peri-operative mortality not associated with surgery. There is little technical difficulty in utilizing this “inside-out” technique and fluoroscopy is not necessary during the occipital portion due to the ability for direct visualization. This may reduce total operative length, unlike transcondylar screws which require the use of 3-D navigation. The primary potential risk involves the placement of the occipital burr hole. This may entail a durotomy, injury to the cerebellum, or the potential of a subdural hematoma. Given direct visualization, these risks are kept to a minimum. With C1/2 instrumentation, the most pressing concern is injury to the vertebral artery, which is seen in less than 5% of cases. Fusion of the occipital cervical junction entails risk of pseudoarthrosis, but in the available series using the “inside-out” technique, fusion rates have been reported to be greater than 95%. Overall, the “inside-out” technique is safe and effective with the major morbidities from performing the less than 1%.

Conclusion

The “inside-out” technique is a valuable technique for spinal surgeons treating craniocervical instability. Although there are distinct advantages with the use of this technique in the setting of revision surgeon, patients with a bony defect, and pediatric patients, the “inside-out” technique should also be considered for use in all occipital cervical fusion as it provides a biomechanically superior construct that is technically safe and efficient to use. Finally, more occipital bone is available for fusion with the inside outside technique than with traditional plate/screw constructs.

References

1. Nockels RP, Shaffrey CI, Kanter AS, Azeem S, York JE (2007) Occipitocervical fusion with rigid internal fixation: long-term follow-up data in 69 patients. *J Neurosurg Spine* 7: 117-123.
2. Perry J, Nickel VL (1959) Total cervical spine fusion for neck paralysis. *J Bone Joint Surg Am* 41-41A: 37-60.
3. Lu DC, Roeser AC, Mummaneni VP, Mummaneni PV (2010) Nuances of occipitocervical fixation. *Neurosurgery* 66: 141-146.
4. Felbaum D, Spitz S, Sandhu FA (2015) Correction of clivoaxial angle deformity in the setting of suboccipital craniectomy: technical note. *J Neurosurg Spine* 23: 8-15.
5. Sandhu FA, Pait TG, Benzel E, Henderson FC (2003) Occipitocervical fusion for rheumatoid arthritis using the inside-outside stabilization technique. *Spine (Phila Pa 1976)* 28: 414-419.
6. Pait TG, Al-Mefty O, Boop FA, Arnaoutovic KI, Rahman S, Ceola W (1999) Inside-outside technique for posterior occipitocervical spine instrumentation and stabilization: preliminary results. *J Neurosurg* 90: 1-7.
7. Sribnick EA, Dadashev VY, Brahma B, Wrubel DM (2012) The use of inside-outside screws for occipitocervical fusion in pediatric patients. *J Neurosurg Pediatr* 10: 392-397.
8. Felbaum D, Spitz S, Sandhu FA (2015) Correction of clivoaxial angle deformity in the setting of suboccipital craniectomy: technical note. *J Neurosurg Spine* 23: 8-15.
9. Thomas JA, Tredway T, Fessler RG, Sandhu FA (2010) An alternate method for placement of C-1 screws. *J Neurosurg Spine* 12: 337-341.
10. Harms J, Melcher RP (2001) Posterior C1-C2 fusion with polyaxial screw and rod fixation. *Spine (Phila Pa 1976)* 26: 2467-2471.
11. Kim LJ, Rekeate HL, Klopfenstein JD, Sonntag VKH (2004) Treatment of basilar invagination associated with Chiari I malformations in the pediatric population: cervical reduction and posterior occipitocervical fusion. *J Neurosurg* 101: 189-195.
12. Ebraheim N, Lu J, Biyani A, Brown J, Yeasting R (1996) An anatomic study of the thickness of the occipital bone: implications for occipitocervical instrumentation. *Spine (Phila Pa 1976)* 21(15): 1725-1729.
13. Geck MJ, Truumees E, Hawthorne D, Singh D, Stokes JK, et al. (2013) Feasibility of Rigid Upper Cervical Instrumentation in Children: Tomographic Analysis of Children Aged 2 to 6. *J Spinal Disord Tech* 27: E110-117.
14. Haheer TR, Yeung AW, Caruso SA, Merola AA, Shin T, et al. (1999) Occipital screw pullout strength. A biomechanical investigation of occipital morphology. *Spine (Phila Pa 1976)* 24: 5-9.
15. Zipnick RI, Merola AA, Gorup J, Kunkle K, Shin T, et al. (1996) Occipital morphology. An anatomic guide to internal fixation. *Spine (Phila Pa 1976)* 21: 1719-1724.
16. Roberts DA, Doherty BJ, Heggeness MH (1998) Quantitative anatomy of the occiput and the biomechanics of occipital screw fixation. *Spine (Phila Pa 1976)* 23(10): 1100-1107.
17. Steinmetz MP, Mroz TE, Benzel EC (2010) Craniovertebral junction: biomechanical considerations. *Neurosurgery* 66: 7-12.
18. Caglar YS, Torun F, Pait TG, Hogue W, Bozkurt M, et al. (2005) Biomechanical comparison of inside-outside screws, cables, and regular screws, using a sawbone model. *Neurosurg Rev* 28: 53-58.
19. Frush TJ, Fisher TJ, Ensminger SC, Truumees E, Demetropoulos CK (2009) Biomechanical evaluation of parasagittal occipital plating: screw load sharing analysis. *Spine (Phila Pa 1976)* 34(9): 877-884.
20. Anderson PA, Oza AL, Puschak TJ, Sasso R (2006) Biomechanics of occipitocervical fixation. *Spine (Phila Pa 1976)* 31: 755-761.
21. Vaccaro AR, Lim MR, Lee JY (2005) Indications for surgery and stabilization techniques of the occipito-cervical junction. *Injury* 36 Suppl 2: B44-53.
22. Finn MA, Bishop FS, Dailey AT (2008) Surgical treatment of occipitocervical instability. *Neurosurgery* 63: 961-968.
23. Wolfla CE (2006) Anatomical, biomechanical, and practical considerations in posterior occipitocervical instrumentation. *Spine J* 6: 225S-232S.
24. Oda I, Abumi K, Sell LC, Haggerty CJ, Cunningham BW, et al. (1999) Biomechanical evaluation of five different occipito-atlanto-axial fixation techniques. *Spine (Phila Pa 1976)* 24: 2377-2382.
25. Kosnik-Infinger L, Glazier SS, Frankel BM (2014) Occipital condyle to cervical spine fixation in the pediatric population. *J Neurosurg Pediatr* 13: 45-53.
26. Uribe JS, Ramos E, Youssef AS, Levine N, Turner AW, et al. (2010) Craniocervical fixation with occipital condyle screws: biomechanical analysis of a novel technique. *Spine (Phila Pa 1976)* 35: 931-938.
27. Le T V, Burkett C, Ramos E, Uribe JS (2012) Occipital condyle screw placement and occipitocervical instrumentation using three-dimensional image-guided navigation. *J Clin Neurosci* 19(5): 757-760.
28. Ahmadian A, Dakwar E, Vale FL, Uribe JS (2014) Occipitocervical fusion via occipital condylar fixation: a clinical case series. *J Spinal Disord Tech* 27: 232-236.