

## Use of Wallace Distractor in Canine Stifle Arthroscopy

Angela Palumbo Piccionello<sup>1\*</sup>, Antonella Volta<sup>2</sup>, Barbara Bonazzoli<sup>1</sup>, Alberto Salvaggio<sup>1</sup>, Adolfo Maria Tambella<sup>1</sup>, Cecilia Vullo<sup>1</sup>, Gian Enrico Magi<sup>1</sup>, Filippo Maria Martini<sup>2</sup>

<sup>1</sup>Department of Veterinary Medicine, School Of Biosciences and Veterinary Medicine, University of Camerino, Italy

<sup>2</sup>Department of Veterinary Medicine, University of Parma, Italy

### Abstract

**Objectives:** To assess the value of the intra-articular Wallace distractor in stifle arthroscopy in the dog.

**Methods-Ex-vivo study:** ten cadaver limbs of dogs were used to explore the stifle joints by arthroscopy each once without and once with the aid of a Wallace distractor. Radiographs and observational data were used to assess the degree of joint distraction and to evaluate any collateral intra-articular damages. In vivo study: distractor-assisted arthroscopy was thereafter performed in 12 consecutive clinical cases of dogs with cranial cruciate ligament rupture. The use of the Wallace distractor, clinical setting, time to complete joint evaluation were recorded.

**Results:** In the cadaver study, radiographic findings showed a significant increase of the joint space after the insertion of the distractor. Visual range during arthroscopy employing the Wallace distractor increased substantially and facilitated the assessment of all visible intra-articular structures. Mean time to evaluate the femoropatellar space was 4,1 minutes, to observe cruciate ligaments 6,5 minutes and to complete joint inspection 10,1 minutes. In the clinical study, the use of Wallace distractor allowed improved arthroscopic observation of all relevant structures, without sub-patellar fat pad removal. Mean time to complete joint inspection was 28,5 minutes.

**Clinical** The use of the Wallace joint distractor may be helpful in the arthroscopic assessment of the canine stifle. It is easy to insert, it allows a considerable distraction of the joint making it easier visibility and reducing the possible need to remove the sub patellar fat pad. With its blunt pins Wallace joint distractor limits the risk of iatrogenic damage and can be easy to use even for surgeons who do not have much experience in knee arthroscopy.

**Keywords:** Wallace Distractor; Stifle Arthroscopy; Dog

**Abbreviations:** CrCL: Cranial Cruciate Ligament, OCD: Osteochondritis dissecans, OA: Osteoarthritis

### Introduction

Arthroscopy in dogs has become a common practice for diagnosis and treatment of selected articular lesions. The arthroscopic approach to the stifle allows direct evaluation of most intra-articular structures and also allows cruciate ligament and meniscal fragment removal [1-6]; in addition, cranial cruciate ligament (CrCL) reconstruction [1,7-11], as well as release of the medial femoropatellar ligament for canine medial patellar luxation [12] and osteochondritis dissecans (OCD) treatment can be performed arthroscopically. Arthroscopic procedures reduce by 2 to 4 the time of hospitalization and of functional recovery compared to treatments by arthrotomy [1].

The stifle is a complex joint that requires a thorough understanding of the anatomy and experience in arthroscopy. Technical difficulties are manifold, especially in chronic arthritis, when villous joint capsule hyperplasia obstructs both, the visual field and the egress cannula [3,10]. Another challenging feature is the presence of the sub-patellar fat pad which often obstructs the view in the already narrow field of vision. Some authors [11] recommend routinely fat pad removal by arthro-shaver or by a radiofrequency probe [6]. However, in the dog, sub-patellar fat pad removal during arthroscopy can provoke substantial bleeding, in turn obstructing the view [11]; this may occur especially when chronic joint inflammation (osteoarthritis - OA) is present as is invariably the case with ruptured cruciate ligaments. Such complication may even render necessary converting arthroscopy into arthrotomy. Furthermore, and as well demonstrated even in human medicine, fat pad removal is not free from long-term complications; reported are joint inflammation and cartilage damage, persistent postoperative anterior knee pain, significant reduction of range of motion (ROM), quadriceps weakness and a significant reduction in the length of patellar tendon [13-20].

To avoid fat pad removal during arthroscopy in dogs, a few experimental studies on the use of different joint distractors have been done previously [16,21,22]. Hulse [21], McKee W and Cook J [22] have described the use of a Hohman retractor for distraction and cranial displacement of the tibia with improved access to the menisci. This can be challenging, especially for the unassisted surgeon, because it is necessary to hold the retractor manually in place throughout the procedure. Furthermore, use of a Hohmann retractor can distort the caudal horns of the menisci, which may impair the assessment of meniscal integrity [23]. Two other methods of joint distraction consist of the use of a pointed retractor (Veterinary Instrumentation, Sheffield, UK) inserted through a small extension of the cranio-medial portal [16], and a external fixator with threaded pins (novel pin distraction device) inserted between the distal portion of the femur and the proximal epiphysis of the tibia [24].

In the 1980's, Professor Larry Wallace, veterinary surgeon at the University of Minnesota, developed an orthostatic distractor, with blunt ends, useful to distract the stifle during arthrotomy (Figure1).

The purpose of this study was to describe and to evaluate the use of the Wallace distractor (SECUROS<sup>®</sup>) for arthroscopy of the stifle joint in an experimental and a clinical setting without sub-patellar fat pad removal.

**\*Corresponding author:** Angela Palumbo Piccionello, Department of Veterinary surgery, School Of Biosciences and Veterinary Medicine, Italy, Tel: 0737/403417; E-mail: [angela.palumbo@unicam.it](mailto:angela.palumbo@unicam.it)

**Received** May 08, 2014; **Accepted** July 28, 2014; **Published** July 30, 2014

**Citation:** Piccionello AP, Volta A, Bonazzoli B, Salvaggio A, Tambella AM (2014) Use of Wallace Distractor in Canine Stifle Arthroscopy. J Veterinar Sci Technol 5: 185. doi:10.4172/2157-7579.1000185

**Copyright:** © 2014 Piccionello AP. This is an open-access article distributed under the terms of the Creative Commons Attribution License, which permits unrestricted use, distribution, and reproduction in any medium, provided the original author and source are credited.



**Figure 1:** Image of SECUROS Wallace Distractor.

## Materials and Methods

The study consists of two parts. First, an ex vivo pilot study was conducted on both stifles of 5 canine cadavers; thereafter we employed the technique in 12 patients who underwent arthroscopy prior to surgery for cruciate ligament rupture (11 TPLO and 1 extracapsular technique).

### Cadaver study

Five fresh dog cadavers of medium to large size (2 Rottweilers, 2 Labrador Retrievers and 1 Cane Corso) were used, with mean bodyweight of 39.5 kg (range 32.7 -49.4 kg) and an average age of 7.6 years (range 6-9 years). Dogs had been euthanatized for reasons unrelated to this study. Each stifle joint (n = 10) was clinically and radiographically examined to exclude any pre-existing pathologic condition. Legs were clipped from tarsus to the hip, and the cadaver was positioned in dorsal recumbency with one of the two limbs to be examined (first the right and then the left) extended caudally with the stifle in neutral position. A 18 G needle was inserted medially to the patellar tendon, midway between the tibial tuberosity and the distal pole of the patella and connected to an infusion system with a pressurized fluid pump set at a constant pressure of 100mm Hg for joint distension. A second 18 G needle was then introduced laterally to the patellar tendon and consequently the cranio-lateral sub-patellar arthroscope portal was established as described [11].

An initial joint exploration allowed to inspect the supratrochlear region, the medial and lateral recesses and the femoropatellar joint. The Wallace distractor arms were then introduced in the medial portal access through a small joint capsule incision (1-2 cm). The proximal distractor jaw was placed into the femoral surface of the intercondylar notch, while the distal jaw was positioned in a more cranial and proximal portion of the tibial plateau. The distractor was opened maximally as judged by the surgeon, who stopped distracting when strong resistance was felt. The distractor was always and only manipulated by the reporting surgeon (APP). In this way, a complete exploration of the joint was performed, with the use of standard 2,7 mm, 30 degree fore-oblique arthroscope. The femorotibial space was then examined. The cruciate ligaments, the medial and lateral menisci were observed and palpated. The time to perform evaluation of these structures was recorded.

At the end of the procedure, the instruments were removed and all joints were subjected to cranio-caudal and medio-lateral X-rays with the distractor in place to objectify the joint distraction; thereafter, joints were submitted to pathological examination, in order to exclude gross intrarticular lesions referable to the procedure.

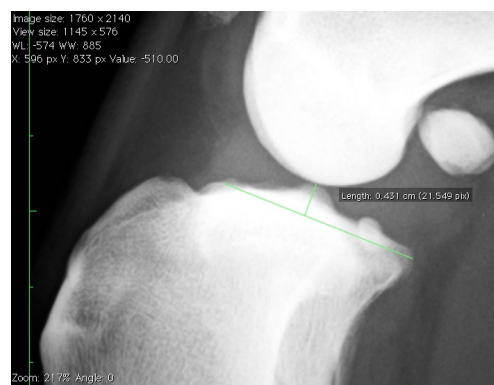
To quantify the stifle distraction when the Wallace distractor

was introduced, the tibial plateau slope was drawn and the length of a perpendicular line to the tibial slope up to the most distal aspect of the femoral condyles was measured in non-distracted and then in distracted joints by medio-lateral radiographs (Figures 2 and 3). Normal distribution of the data was confirmed with Anderson-Darling normality test. Equality of variances was assessed with Levene's test. Statistical comparison was performed using paired Student's t test. A p value <0.05 was considered significant. Statistical data processing was performed using commercial software packages (Microsoft Excel version 14.2.5: 2010 Microsoft Corporation, Redmond, Washington, USA and QI Macros SPC Software for Excel, version 2013.04, KnowWare International Inc., USA).

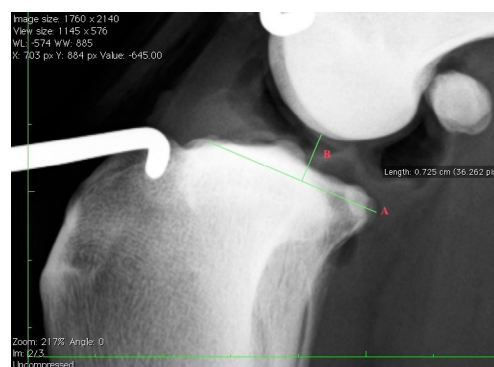### Clinical study

Twelve dogs, 5 females and 7 males, were included in the pilot study with a mean age of 3,3 years (range 2-5 years) and a mean bodyweight of 39,7 kg (range: 25.4 to 75 kg). In all patients cranial cruciate ligament deficiency was diagnosed, associated in four cases with meniscal injury (Table 1).

All patients underwent orthopaedic and neurological examination, routine blood tests and cardiologic auscultation. Subsequently, cranio-caudal and medio-lateral radiographic projections of the stifles were obtained. All patients underwent diagnostic stifle arthroscopy and,



**Figure 2:** Particular of the Medio-Lateral radiograph of a non-distracted stifle joint. A: tibial plateau slope, B: perpendicular line to the tibial slope up to the most distal aspect of the femoral condyles.



**Figure 3:** Particular of the Medio-Lateral radiograph of a distracted stifle joint. A: tibial plateau slope, B: perpendicular line to the tibial slope up to the most distal aspect of the femoral condyles.

after that, eleven had surgical treatment with TPLO (tibial plateau leveling osteotomy) and one dog had an extracapsular stabilization technique done.

The anaesthetic protocol included pre-anesthetic medication with dexmedetomidine (10 µg/kg, Dexdomitor®) associated with tramadol hydrochloride (3 mg/kg, Altadol®) intramuscularly (IM). Anaesthesia was induced, with propofol (3-4 mg/kg, Propovet®) intravenously (IV), and maintained with isoflurane (Isoflurane-vet®) delivered in oxygen. Each dog received 2 mg/kg IV lidocaine loading dose immediately after induction, followed within 5 min by a constant rate infusion (CRI) at 50 µg/kg/min lidocaine in lactated Ringer's solution (B-Braun, Italy) 10 ml/kg/hour. Before undergoing surgery, all patients received cefazolin sodium IV (20 mg/kg, Cefazolina-Dorom®) and 30 min prior the end of surgery buprenorphine (iv 20 µg/kg, Temgesic®). For surgery, patients were placed in dorsal recumbency with the affected limb extended caudally. The arthroscopic procedure was the same as that used on cadavers. The clinical information and the arthroscopic findings were recorded.

The patients were re-evaluated clinically at 7, 15, 30, 60 and 90 days after the surgical procedure; all patients were subjected to palpation of the limb with stress varus/valgus movements and external/internal rotation and at 30, 60 and 90 days also medio-lateral and cranio-caudal radiographs of stifles.

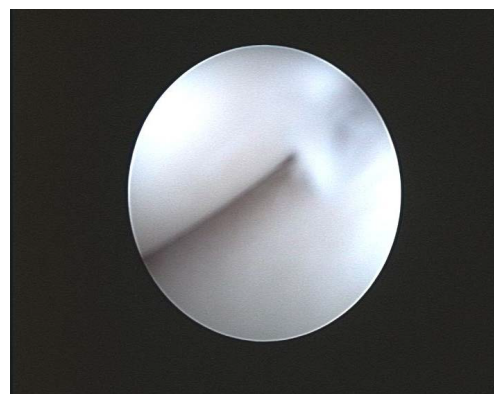
## Results

### Cadaver study

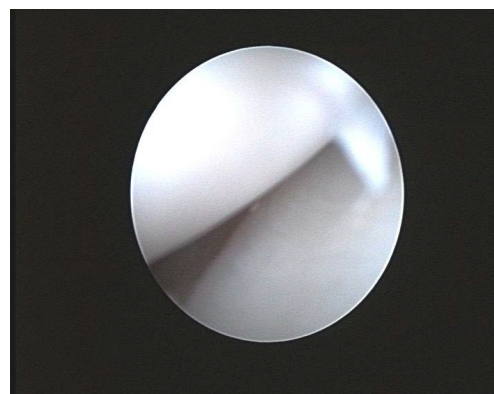
The application of Wallace distractor was easy and fast to perform; the device held well in place without the aid of an assistant. The distractor allowed an easy and accurate assessment of femorotibial joint (Figures 4 and 5). Evaluation and palpation of intraarticular structures was possible in all stifles. Mean time to complete evaluation of the femoropatellar space was 4,1 minutes, to observe the cruciate ligaments 6,5 minutes and to completion of the examination 10,1 minutes. No gross lesions, which may have been caused by the distractor, were found.

Examination and measurements in non-distracted and distracted medio-lateral stifle radiographs showed a substantial increase of articular space when the Wallace distractor was introduced and spread

within the joint (Figures 6 and 7). The mean ( $\pm$  standard deviation) distance between the most distal aspect of the femoral condyles and the tibial slope in non-distracted joints was  $4.4 \pm 0.3$  mm, while in distracted joints was  $7 \pm 0.2$  mm. The average increase was 2.6 mm. The difference was significant ( $P < 0.001$ ).



**Figure 4:** Intraoperative view of the medial femorotibial space before the introduction of the Wallace distractor.

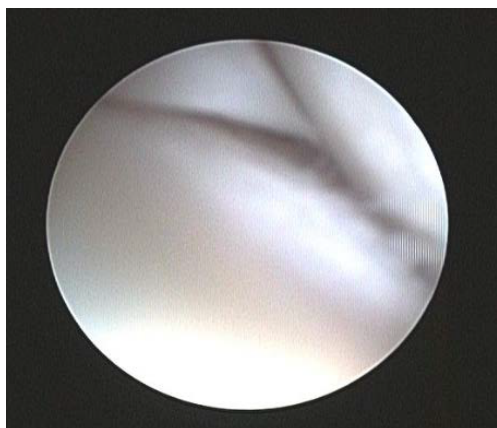

**Figure 5:** Intraoperative view of the medial femorotibial space after the introduction of the Wallace distractor.

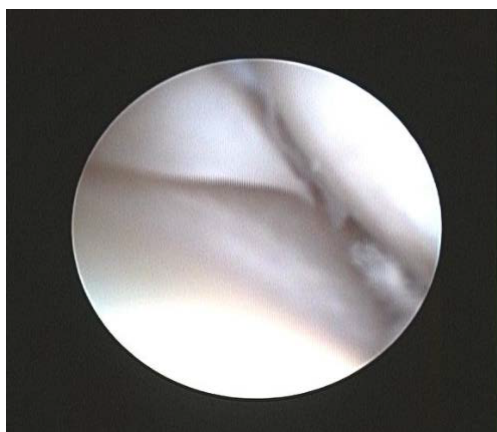
DOG	Breed	Age (y)	Weight (Kg)	Affected Limb	Diagnosis	All Structures Observed	Joint Evaluation (Time)	Complication
1	Cane Corso	3	45,2	Right	Complete CrCL rupture	Yes	27	None
2	St. Bernard	3	75	Right	Complete CrCL rupture	Yes	24	None
3	Mix-breed	4	25,4	Right	Complete CrCL rupture, Medial Meniscal injury	Yes	38	None
4	Leonberger	2	47,3	Left	Complete CrCL rupture	Yes	23	None
5	Rottweiler	2	41,6	Left	Complete CrCL rupture, Medial Meniscal injury	Yes	30	None
6	Rottweiler	3	38,3	Left	Complete CrCL rupture, Medial Meniscal injury	Yes	36	None
7	German Shepherd	5	34,4	Right	Complete CrCL rupture	Yes	26	None
8	Cane Corso	3	42,1	Right	Complete CrCL rupture	Yes	33	None
9	Labrador	4	31,3	Left	Complete CrCL rupture	Yes	22	None
10	Labrador	3	33,3	Right	Complete CrCL rupture	Yes	24	None
11	Golden Retriever	5	34,4	Left	Complete CrCL rupture	Yes	24	None
12	Boxer	3	28,1	Left	Complete CrCL rupture, Medial Meniscal injury	Yes	35	None

**Table 1:** Results of the Clinical Study.





**Figure 6:** Intraoperative view of the medial femoral condyle and medial meniscus before the introduction of the Wallace distractor.



**Figure 7:** Intraoperative view of the medial femoral condyle and medial meniscus after the introduction of the Wallace distractor.

## Clinical study

A full observation of the intra-articular structures of the stifle before insertion of the distractor was challenging. The Wallace distractor application allowed a complete and straightforward visualization of all intra-articular structures, without fat pad removal. Arthroscopic examination in all patients showed a complete rupture of the CrCL and severe synovitis with villous hyperplasia, articular cartilage degeneration and periarticular osteophytes. Patients n. 3, 5, 6 and 12 had also a tear of the medial meniscus. After the diagnosis they were treated also with partial meniscectomy.

Mean time to complete diagnostic evaluation of the joint was 28.5 minutes.

All patients recovered without complication. At the 7 and 15 day check-up, all dogs exhibited some degree of improvement of lameness.

Patients were evaluated again at 30, 60 days; recovery to full function proceeded in eleven cases without any complication or delay. At 90 days, only patient n.3 was still slightly lame. Medio-lateral and cranio-caudal radiographs of stifles, at that time, showed in eleven dogs a mild progression of arthrosis, and in patient n.3 the articular degeneration was severe.

## Discussion

The authors showed that use of the Wallace distractor in stifle arthroscopy allowed substantially increased joint distraction, thereby enlarging the visual field, and allowing better assessment of the femorotibial space without infra-patellar fat pad removal. Sparing this intra-articular structure is important for avoiding intra-operative bleeding on one hand and on the other possible long-term complications; this, because the sub-patellar fat pad, together with the synovial membrane, is an integral anatomical feature mediating the vascular supply to parts of the patellar tendon and to the CrCL. Therefore the integrity of this vascular supply by preservation of the infra-patellar fat pad is an important factor in post-operative healing [25]. As shown by Withney [11], sub-patellar fat pad removal in the dog can cause severe hemorrhagic episodes during arthroscopy, especially if associated with chronic joint inflammation (osteoarthritis-OA). The persistence of a haemarthrosis after surgery can also lead to cartilage damage as a result of synovitis, cartilage matrix degradation and modifications of chondrocytes' metabolism [13-15]. Although the long-term effects of fat pad debridement in the dog are not yet fully understood [16], several recent reports, in people [17,18], showed that fat pad ablation, in patients undergoing total knee replacement, is associated with persistent postoperative anterior knee pain, reduction of range of motion, quadriceps weakness and reduction in the length of patellar tendon [19]. In another study in children [20] it has been demonstrated that the anterior knee fibrosis developing after fat pad removal, limits the patellar tendon growth, therefore preservation of this adipose sub-patellar structure is fundamental for proper patellar tendon growth as well as for prevention of cartilage degeneration.

In this canine study, the Wallace distractor proved not only to enlarge joint space but also was easy to use and atraumatic. The distractor features blunt ends and, once correctly positioned, it does not need to be held in position by an operator, which facilitates manipulation of the joint and it results also atraumatic. These features make it more secure and handier than a Hohman retractor which is frequently used for joint distraction [21,22].

The Wallace distractor is also well usable in arthroscopy procedures which precede surgical treatments such as TPLO, since it does not interfere with the mask-guide application perpendicularly to the major axis of the tibia; this is another advantage over the distraction device designed by Bottcher et al. [24].

In the twelve clinical cases reported, the use of Wallace distractor was free of complications and did not delay functional recovery.

In conclusion, the use of Wallace distractor in stifle joint arthroscopy was helpful to achieve a good distraction of the joint, an adequate assessment of all joint structures without the need of infra-patellar fat pad removal. The procedure was safe and easy to perform. With its blunt pins, Wallace joint distractor limits the risk of iatrogenic damage and it might be easy to use even for surgeons who do not have much experience in knee arthroscopy.

This technique merits further investigation in diagnostic and therapeutic arthroscopy.

## Acknowledgements

Thanks to Prof. Gert Niebauer, for the help given in reviewing this manuscript. Gert Niebauer, dvm, PhD, Dipl. ECVS, Full Professor in surgery at Ecole Veterinaire Paris, gertnieb@tin.it.

Thanks to Prof. Larry J Wallace, for the information provided about the distractor. Larry J Wallace, DVM, MS, DACVS, hipbone37@aol.com

## References

- Tomlinson J (2005) Arthroscopy in the dog-What can be done? Proceedings of the NAVC, 799-801.
- Hulse D (2002) Is meniscal release necessary? Proceedings of the 11th ESVOT Congress, 108-109.
- Bardet JF (2006) Diagnostic and surgical arthroscopy in dogs. Proceedings IAMS Clinical Nutrition Symposium; Montreux, 14-18.
- Hulse D (2000) Arthroscopic meniscal treatment. Proceedings of the 10th ESVOT Congress; Munich, 25-26.
- Ralphs SC, Whitney WO (2002) Arthroscopic evaluation of menisci in dogs with cranial cruciate ligament injuries: 100 cases (1999-2000). *J Am Vet Med Assoc* 221: 1601-1604.
- Ridge PA (2006) Isolated medial meniscal tear in a Border Collie. *Vet Comp Orthop Traumatol* 19: 110-112.
- Whitney WO (1998) Arthroscopic reconstruction of the cranial cruciate ligament in the dog, Proceedings Eighth Annu ACVS Symp. Chicago.
- Hulse D, Beale BS (2000) Arthroscopically assisted "under and over" reconstruction of the cranial cruciate ligament in the dog. Proceedings of 1st surgical forum ECVS; Val'd Isère, 22.
- Hulse D (2000) Arthroscopic intra-articular reconstruction of the CCL deficient stifle using the over the top technique, Proceedings of the 10th ESVOT Congress; Munich, 29-31.
- Rytz U (2010) Benefits and limits of arthroscopy, Proceedings of the 35th WSAVA Congress; Geneva, 1-3.
- Whitney WO (2003) Arthroscopically assisted surgery of the stifle joint. In: Beale BS, Hulse DA, Schulz KS, Whitney WO, Small animal arthroscopy. Philadelphia: Saunders.
- Bevan JM, Taylor RA (2004) Arthroscopic release of the medial femoropatellar ligament for canine medial patellar luxation. *J Am Anim Hosp Assoc* 40: 321-330.
- Roosendaal G, TeKoppele JM, Vianen ME, van den Berg HM, Lafeber FP, et al. (1999) Blood-induced joint damage: a canine in vivo study. *Arthritis Rheum* 42: 1033-1039.
- Hooiveld MJ, Roosendaal G, Vianen ME, van den Berg HM, Bijlsma JW, et al. (2003) Immature articular cartilage is more susceptible to blood-induced damage than mature articular cartilage: an in vivo animal study. *Arthritis Rheum* 48: 396-403.
- Jansen NW, Roosendaal G, Wenting MJ, Bijlsma JW, Theobald M, et al. (2009) Very rapid clearance after a joint bleed in the canine knee cannot prevent adverse effects on cartilage and synovial tissue. *Osteoarthritis Cartilage* 17: 433-440.
- Gemmill TJ, Farrell M (2009) Evaluation of a joint distractor to facilitate arthroscopy of the canine stifle. *Vet Surg* 38: 588-594.
- Tanaka N, Sakahashi H, Sato E, Hirose K, Isima T (2003) Influence of the infrapatellar fat pad resection in a synovectomy during total knee arthroplasty in patients with rheumatoid arthritis. *J Arthroplasty* 18: 897-902.
- Dragoo JL, Johnson C, McConnell J (2012) Evaluation and treatment of disorders of the infrapatellar fat pad. *Sports Med* 42: 51-67.
- Lemon M, Packham I, Narang K, Craig DM (2007) Patellar tendon length after knee arthroplasty with and without preservation of the infrapatellar fat pad. *J Arthroplasty* 22: 574-580.
- Takatoku K, Sekiya H, Hayashi M, Hoshino Y, Kariya Y (2005) Influence of fat pad removal on patellar tendon length during growth. *Knee Surg Sports Traumatol Arthrosc* 13: 706-713.
- Hulse D (2006) Arthroscopy of the stifle. Traditional and non-traditional portal sites. Proceedings of the World Congress WSAVA/FECAVA/CSAVA, Prague, 619-622.
- McKee W, Cook J (2006) The stifle, in Houlton J, Cook J, Innes J, et al: (eds): BSAVA Manual of Canine and Feline Musculoskeletal Disorders. Gloucester, UK, British Small Animal Veterinary Association, 350-395.
- Moses PA (2002) A technique for the surgical repair of caudal peripheral detachment and longitudinal peripheral tears of the medial meniscus in dogs. *Vet Comp Orthop Traumatol* 15: 92-96.
- Böttcher P, Winkels P, Oechtering G (2009) A novel pin distraction device for arthroscopic assessment of the medial meniscus in dogs. *Vet Surg* 38: 595-600.
- Arnoczky SP, Rubin RM, Marshall JL (1979) Microvasculature of the cruciate ligaments and its response to injury. An experimental study in dogs. *J Bone Joint Surg Am* 61: 1221-1229.