

# Updates in Pelvipерineal Reconstruction Options After Abdominoperineal Resection

Dan Cristian Moraru<sup>1\*</sup> and Viorel Scripcariu<sup>2</sup>

<sup>1</sup>Department of Plastic Surgery, "St. Spiridon" Emergency Hospital Iasi, Iasi, Romania

<sup>2</sup>Department of Surgery, Regional Institute of Oncology Iasi, Grigore T. Popa University of Medicine and Pharmacy, Iasi, Romania

## Abstract

Abdominoperineal resection may be the only curative solution for invasive or recurrent malignant tumors in the pelvic-perineal region. Recent studies have established that immediate pelvic-perineal reconstruction following abdominoperineal resection is associated with superior primary healing, decreased postoperative complications, rapid recovery and reinsertion with increased quality of life for the patient. Currently, many reconstructive options for the perineal defect after abdominoperineal resection are available, ranging from primary direct closure to flap reconstruction. Better knowledge of the progress attained in the care of the perineal defect after abdominoperineal and rectal resection can help the surgeon make a better choice for each patient. There is no consensus on the optimal technique after abdominoperineal resection. In this article, various closure techniques are presented, from direct closure, closure fastened with meshes to the autologous reconstruction by musculocutaneous flaps, which until recently have been the "gold standard" for perineal reconstruction. The main donor sites for musculocutaneous flaps include the rectus abdominis, gracilis or gluteus maximus muscles. The reconstruction option should be carefully chosen to establish a significant balance between the reconstructive needs and the morbidity of the donor site. A review of these techniques and their development is provided to offer a general overview of what has been done, what can be done currently and what may be done in the future.

**Keywords:** Rectal cancer; Abdominoperineal rectal resection; Abdominoperineal resection; Pelvipерineal reconstruction; VRAM; TRAM; ORAM; Gluteal fold flap; Gracilis flap; Pediculate flaps; Pudendal flaps; Lotus petal flap; Singapore flap; Posterior thigh flap; Anterolateral thigh flap

## Introduction

Abdominoperineal resection (APR)-total pelvic exenteration-is the therapeutic option for patients with low rectal cancer or severe intestinal inflammatory disease or the salvage procedure for persistent or recurrent anal cancer, invasive or recurrent tumors in the pelvipерineal region [1]. Abdominoperineal resection proposed by Miles in 1908 [2], consists of the resection of the rectum and anal canal, including variable sections of the sigmoid colon, with the full removal of the perianal skin, with incisions made in the abdomen and perineum.

Abdominoperineal resection leaves an important pelvipерineal defect; local tissues may be compromised by preoperative radiotherapy that alters tissue vascularization and delays the healing process [3]. The pelvipерineal defect is of variable size, three-dimensional and transfixing with the existence of a communication between the abdominal cavity and the external environment [3]. Removing the rectum and the anus from the pelvis leads to a large cavity. This pelvic "dead space" is prone to fluid build-up and blood clots that increase the incidence of abscesses, defect and perineal sinus infection.

The complex nature of the defect exposes the region to some rare complications: infections, seroma, abscesses, dehiscence, delayed healing and perineal sinus, which occur frequently and can be severe [4], as well as the persistence of the pelvic "dead space" predisposed to infection, intestinal prolapse, occlusions and fistula, accentuated morbidity with slow, delayed healing [3]. The incidence of perineal defect complications following abdominoperineal resection is very high in the literature, with different rates, from 14 to 80% [5-8]. A major contributor to the increased rate of complications is tissue ischemia, which is probably due to an increased tension of the perineal defect and to pressure, as well as to neoadjuvant radiotherapy [9]. Clifford Scheckter [10] refers

to complications as belonging to the perineal incision, the donor site and to other medical complications (small intestine obstruction, growth retardation).

Perineal complications subdivided into specific categories by frequency are as follows:

- Cellulites-non-suppurative inflammations of the incision requiring antibiotic treatment;
- Abscesses-a purulent collection involving drainage;
- Dehiscence-defined as dermal separation greater than 1/3 of the defect gap without infection;
- Flap loss-by necrosis of at least 1/3 of the tissue;
- Prolonged slow healing-defined as the absence of dermal overlap or persistent non-suppurative drainage 3 weeks after surgery.

These complications cause significant morbidity frequently associated with prolonged and repeated hospitalization, extensive home care and increased costs [11]. Patients with significant complications of the perineal defect have an increased incidence of local tumoral relapses that affect long-term survival [12].

**\*Corresponding author:** Dan Cristian Moraru MD, Plastic Surgery and Burns Unit, "St. Spiridon" Emergency Hospital Iasi, Iasi, Romania, Tel: +40 (0) 232 24 08 22; Fax: +40 (0) 232 21 77 81; E-mail: [morarudc@gmail.com](mailto:morarudc@gmail.com)

**Received** December 06, 2017; **Accepted** December 20, 2017; **Published** December 27, 2017

**Citation:** Moraru DC, Scripcariu V. Updates in Pelvipерineal Reconstruction Options after Abdominoperineal Resection. Journal of Surgery [Jurnalul de chirurgie]. 2017; 13(4): 115-122 DOI: [10.7438/1584-9341-13-4-2](https://doi.org/10.7438/1584-9341-13-4-2)

**Copyright:** © 2017 Moraru DC, et al. This is an open-access article distributed under the terms of the Creative Commons Attribution License, which permits unrestricted use, distribution, and reproduction in any medium, provided the original author and source are credited.

The specific risk factors that influence healing of the defect after APR are: operative care of the perineal defect, preoperative radiotherapy and the nature of the primary disease (rectal cancer, anal cancer and intestinal inflammatory disease) [4]. After total pelvic exenteration, immediate pelviperineal reconstruction is followed by good primary local healing, significant decrease in postoperative complications, rapid recovery and social reinsertion and an increase in the patient's quality of life [3].

The defect resulting from total pelvic exenteration is extremely slowly healed if secondary healing is preferred.

Factors that cause delayed healing and increased morbidity are: increased local mobility, poor hygiene, low bandage frequency and gradual decrease in patient compliance [3]. Peripheral wound contraction is reduced and local infectious processes maintain the vicious circle of slow healing. In total pelvic exenteration, the reconstructive solution should provide consistent, well-vascularized tissue support, and the donor area of the flap should not create additional morbidity [3]. All authors have correlated reconstructive procedures with promoting primary healing and reducing intestinal and infectious complications (Table I) [13-16].

Many surgical methods are used for reconstruction after abdominoperineal resection (APR).

- Several factors will be considered:
- The volume of the tissue to be resected;
- Addition of radiotherapy;
- The potential donor site;
- Stoma, scars.

The typology of the reconstruction is the following: filling the "dead pelvic space", restoring the pelvic floor, reconstructing the perineal defect and total vaginal reconstruction where appropriate. There are various closure techniques and their presentation will provide a vision of what can be done, what needs to be done, and what we need to do in the future. These reconstructive techniques are noted in Table II. We present herein the advantages and disadvantages of every technique.

## Direct closure

In the past, the perineum was left open and folded to support the perineal floor and to promote hemostasis and drainage [17]. This technique has led to major discomfort and to a delayed healing of the defect, often in four months or more.

Since 1970, four critical aspects of the perineal defect closure have been identified:

- Primary closure of the defect;
- Closure of the peritoneum;
- Closed suction drainage (negative pressure) of the pelvis through trans-abdominal or perineal drainage;
- Irrigation of the pelvic defect and closed active drainage.

The closure of the pelvic peritoneum after primary closure during pelvic abdominal reconstruction is associated with prolonged healing time of the perineal defect [18]. The closure of the peritoneum and of the perineum results in the creation of a closed "dead pelvic space" that cannot be easily drained and leads to infection of the declive accumulation of fluid and hematoma.

When the peritoneum is open, it allows the intra-abdominal viscera to occupy the presacral space; some use omentum or the uterus to fill the dead space, preventing small intestine adherence to the pelvis

[19-21]. Currently, direct closure is done by closing the perineum, filling the dead pelvic space with the omentum and suction drainage of the pelvic cavity. We need to underline that the rate of non-healing postoperative wounds remains high [4]. There is significant literature data on the complications of primary closure that highlights the problems associated with the healing of the perineal defect. Closure under tension is an important factor for poor local development. The infection of the defect after primary closure has been reported recently as representing between 13-30% of the complications and pelvic abscesses up to 48% [22]. Delayed healing of the defect due to infections and abscesses was reported in 22% cases by Althumeiri [22].

The increased rate of complications following standard techniques such as direct closure has led surgeons to look for other surgical treatment options such as:

- The use of myocutaneous flaps [23] to fill dead space and perineal reconstruction.
- The use of synthetic or biological meshes [24,25].

## Closure with synthetic or biological meshes

Absorbable and non-absorbable meshes are used to separate the

**Table I:** Pelvi-perineal reconstruction goals.

1	Defect coverage
2	Filling the pelvic dead space
3	Separating the pelvic and abdominal cavities
4	Bowel protection
5	Prevention of post-operative perineal herniation
6	Wound healing
7	Adequate micturition
8	Proper evacuation of fecal stream
9	Aesthetics
10	Restore of sexual function
11	Minimal donor site morbidity
12	Low rate of complications
13	Good quality of life

**Table II:** Pelvi-perineal reconstruction options.

A)	DIRECT CLOSURE
B)	MESH ENHANCED CLOSURE
C)	NON-PEDICLED FLAPS
-	Rectus abdominis flap
-	Gracilis muscular/musculocutaneous flap
-	Gluteus Maximus flap
D)	PEDICLED FLAPS
1	Abdominal flaps
-	VRAM
-	Ms VRAM
-	Fs VRAM
-	DIEP
2	Gluteal flaps
-	SGAP/IGAP
-	IGAM
-	V-Y gluteal perforator flap
3	Pudendal flaps
-	Pudendal thigh (Singapore)
-	GFF
-	Lotus petal flap
4	Thigh flaps
-	Gracilis flap
-	ALT
-	Posterior thigh flap

abdominal cavity from the anal injury after direct defect closure. This reconstructive process reduces the complications of adjuvant postoperative radiotherapy [12].

The use of meshes determines postoperative adhesions between the small intestines and the new pelvic floor; for the prevention of adhesions, some surgeons use biomaterials.

- Seprafilm® (a bioresorbable, sodium hyaluronate based membrane) from Genzyme was used [24], especially for patients undergoing adjuvant radiotherapy. The pelvic floor was rebuilt with a double layer of Vicryl mesh. Before closing the abdomen, a piece of Seprafilm was inserted to separate the small intestines from the pelvic floor with an incision on the median line. Seprafilm® acts as an ideal mechanical barrier to prevent adhesions after proctocolectomy and myomectomy [25-28].
- Human acellular dermal matrix (HADM) was also used [29]. HADM is a dermal biomaterial from which all cellular elements have been removed, being as durable as permanent synthetic meshes but with better compatibility [30]. The use of HADM is accompanied by complications such as: seroma with an incidence between 6-26% and perineal pain in 33% cases [31-33] or eventration (the material becomes lax). At present, the use of meshes is not safe due to the large number of complications of synthetic material and the lack of randomized multicentre studies on the efficiency of biomaterials.

### Non-pedicled flaps

Myocutaneous flaps were the “gold standard” treatment for perineal reconstruction. The main donor sites for the myocutaneous flaps included the rectus abdominis, gracilis and gluteus maximus muscles [34].

**The rectus abdominis flap:** On lower pedicle transposed in the pelvic-perineal region is a therapeutic option of first intention in reconstructive surgery to cover defects after total pelvic exenteration. Recent studies [35] attach great importance to this flap and underline its reconstructive value. The cutaneous flap portion may be oblique (Taylor flap-ORAM-Oblique rectus abdominis muscle), horizontal TRAM (Transvers rectus abdominis myocutaneous) [36] or vertical, along the muscle-VRAM (Vertical rectus abdominis myocutaneous) [37]; the muscle is raised on the epigastric vessels and passed through the perineum.

The most commonly used variant is the one with the vertically oriented cutaneous portion-VRAM (Vertical rectus abdominis muscle). In this process, the closure of the anterior aponeurotic cavity provides increased resistance to pelvic floor restoration and the skin area provides enough tissue to obliterate the pelvic-perineal defect [3]. The pedicled VRAM flap has been used in various situations for difficult periabdominal defects, with fewer perineal complications compared to the primary closure of the defect [10]. This procedure has a smaller perineal morbidity as compared to primary closure and excellent long-term survival [38].

Kokossi reports that studies that examine the efficiency of VRAM flap for reconstruction in APR defects have demonstrated a relatively high rate of complications through this procedure-over 15% [9]. However, this technique is superior to the gracilis flap reconstruction in terms of complications [38]. The use of a VRAM flap can be associated with a greater risk of dehiscence and hernia at the donor site as well as the limitation of colostomy placement or replacement in the future. The incidence of dehiscence is 60% for VRAM [9].

The use of the VRAM flap can be limited by positioning, anterior abdominal surgery, scarring and the number of required colostomies.

The use of oblique cutaneous flap ORAM (Oblique rectus abdominis muscle) [39] provides a larger cutaneous area and an increased rotation arch of the flap by extending the cutaneous portion to the medial axillary line without intercepting teguments intended for colostomy. The simple muscular flap is useful in case of a minimal perineal defect or in multi-flap procedures; it involves minimal complications by keeping the aponeurotic anterior laminae intact. The rectus abdominis muscle flap has the following advantages: constant, dominant (profound inferior epigastric) vascular pedicle that can vascularize the entire muscular body, high reliability with few vascular complications, freedom of choice in the planning and dissection of the cutaneous area. Removal of the flap in the abdominal area is associated with minimal complications, the arc of rotation allowing the easy reach of the pelvic-perineal region. The flap provides sufficient tissue material to close the “pelvic dead space” and the perineal wound.

The dissection can be accomplished concurrently with the perineal time of the pelvic exenteration-thus shortening the duration of the intervention [3]. Buchel EW et al. in a recent study [35] using the rectus abdominis myocutaneous flap indicates complete healing of perineal pelvic defects after total pelvic exenteration within 30 days in 94% of cases.

**Muscular and myocutaneous gracilis flap:** Described in 1976 by Mc Craw [40], it was a procedure commonly used for perineal and pelvic reconstruction, but also for partial or total vaginal reconstruction. The gracilis muscle can be used for unilateral or bilateral reconstruction with myocutaneous or muscular flap. This technique is a common option for reconstruction, especially in neo-adjuvant radiotherapy due to its benefits and ease of harvesting [12]. The harvesting site of the gracilis flap is outside the irradiation field, thus providing a healthy tissue for reconstruction. Scarring at the harvest site and functional disorders are minimal after harvesting the muscular gracilis flap [12].

The use of the bilateral gracilis flap is a useful indication in covering the defect in the pelvic-perineal region, which in many cases complements the tissue support provided by the abdominal flap. The main complication of the flap is represented by partial or total necrosis of the flap skin because the vascular pedicle is susceptible to spasms, thermosensitive and fragile; the development of necrosis areas may also be influenced by the anatomical features of cutaneous perforators. Partial or total necrosis of the flap skin was reported in the literature [3]. The complication rate is increased: between 21-42%. MC Craw signals partial necrosis of the flap in 6 out of 22 patients (27%), and major necrosis in 2. Heath [41] reports dehiscence and marginal necrosis in 3 out of 8 patients with bilateral gracilis flaps vaginal reconstruction.

### Gluteus maximus flap

The bilateral or unilateral myocutaneous flap has been described as a local solution. Reconstruction with gluteus maximus myocutaneous flap has the advantage of not destroying the abdominal wall and avoiding the insertion of foreign material. The gluteus maximus muscle is a major extensor for the hip, being important for posture and balance. After surgery, 78% of patients have early or late complications. This flap is less used and less attractive due to increased morbidity. Until recently, standard perineal reconstruction used muscular flaps or myocutaneous flaps with: rectus abdominis, gracilis or gluteus maximus muscles. The myocutaneous flaps were the “gold standard” for perineal reconstruction [12].

### Pedicled flaps

Perforator flaps used in perineal reconstruction are described as new reconstructive solutions. According to the donor site, they are classified as follows:

1. Abdominal flaps: VRAM, Ms-VRAM, Fs-VRAM, DIEP.
2. Gluteal flaps: SGAP, IGAP, IGAM.
3. Pudendal flaps: pudendal flap, gluteal flap, lotus flap, Singapore flap.

4. Gracilis flaps.
5. Posterior thigh flap.

Perforator flaps have considerably expanded the treatment options in plastic and reconstructive surgery with their use, thus avoiding the morbidity of the donor site [42-44] and the complications related to muscle transfer. [12].

The principle of perforator flaps is to harvest and transpose a vascularised flap based on a pedicle that is dissected in the muscle. The modern classification of pedicled flaps based on the number of major/minor pedicles that support the muscular flap is proposed by Mathes and Nahai (Table III).

**Abdominal flaps-including the rectus abdominis muscle:** The use of the myocutaneous flaps remains the preferred technique. The flap pedicle can be obliquely oriented (Taylor flap-ORAM), horizontally-TRAM flap (Transvers rectus abdominis musculocutaneous) or vertical, along the muscle (VRAM-vertical rectus abdominis myocutaneous) [37,38,45]. The main complications after harvesting muscles and fascia are: hernia, parietal hypotonia and incisional hernias-which will require strengthening with synthetic material meshes [46]. As a result of anatomical knowledge and improvement of the radiological detection of perforators, flaps can be cut along a single myocutaneous perforator vessel.

The cutaneous pedicle can be placed completely independent of the direction of the muscle so long as to include at least one of these periumbilical perforators [47,48]. Neither the muscle nor the fascia represents the support for flap vascularization.

### Fs-VRAM flap

Morbidity at the donor site can be reduced by harvesting fascia sparing VRAM (Fs-VRAM). To protect the fascia, the flap has to be detached at both ends of the selected perforator vessel. The fascia is then incised so that only one strip contains the selected perforator vessel. Closure can be done in the absence of tension and without the use of prosthetic material [49,50].

### Ms-VRAM flap

The procedure can be improved by "saving" the muscle, as is the case with breast reconstruction [51,52]. The perforator that irrigates the flap is dissected through the muscle to preserve muscular integrity. Some authors have suggested that the Ms-VRAM technique (the muscular sparing VRAM) is appropriate to salvage the muscle and reduce the abdominal morbidity cited for the classic VRAM flap.

### DIEP flap

The DIEP (Deep Inferior Epigastric Artery Perforator) flap is an effective method of perineal reconstruction.

It was described by Koshima and Soede in 1989 [53]. Currently the DIEP flap is routinely used for breast reconstruction by free transfer; it has the advantage of a long vascular pedicle with good blood irrigation involving minimal lesions in the structure of the abdominal muscle fascia. The flap can be harvested as a pedicled insular flap for perineal reconstruction for a pelvipereineal defect or vaginal reconstruction. [54,55]

The DIEP flap is used in perineal reconstruction, providing several advantages:

- It is a one-step procedure;
- It has a safe, big and long vascular pedicle without requiring microanastomosis (not free transferred);
- It provides adequate tissue to cover any perineal defect or vaginal reconstruction;
- The donor site can be closed primarily without leaving an important scar;
- It is correlated with a much lower risk of abdominal hernia.

The flap may be too bulky for the receptor site, which may require thinning. Preoperative abdominal CT angiography can highlight the DIEP flap anatomy that helps reduce flap harvesting time and guide the flap thinning. It can be concluded that the pedicled DIEP flap can provide a suitable pedicle for perineal reconstruction and can be thinned without damaging the inner blood network of the superficial epigastric vein [56].

### Gluteal flaps

The gluteal region was a source for unilateral or bilateral myocutaneous flaps [57]. The use of the gluteus maximus flap is a satisfactory local solution [58].

For the classic technique, the following variants were suggested:

- a. The SGAP/IGAP flap (The superior or inferior Gluteal Artery Perforator Flap).
- b. The IGAM flap (The Inferior Gluteal Artery myocutaneous flap).
- c. The v-y gluteal perforator flap.
- a. SGAP/IGAP flap.

**Perforator/free flaps based on gluteal vessels (IGAP/SGAP flaps):** Are commonly used for breast reconstruction and surgical therapy of sacral pressure ulcers [59] and of the pilonidal sinus [60]; Wagstaff [61] describes the use of these flaps for vaginal reconstruction. The choice between SGAP and IGAP flaps for perineal reconstruction depends on the location of the perforator and on the preoperative color Doppler results [23].

Table III: Mathes and Nahai classification of muscular flaps.

Mathes and Nahai	Dominant pedicle	Minor pedicle	Muscle
Type I	1		Gastrocnemius Rectus femoris Tensor fascia lata
Type II	1	1	ADM, FDB Abductor hallucis Temporalis Trapezius Gracilis
Type III	2		Gluteus maximus Rectus abdominis Serratus anterior Semimembranosus
Type IV		multiple	EHL, FHL Sartorius Tibialis anterior
Type V	1	multiple	Pectoralis major Latissimus dorsi



**IGAM flap:** Since SGAP and IGAP flaps require laborious dissection and associate a risk of pedicle injury, Boccola [61] presented a myocutaneous flap based on the inferior gluteal artery, involving only 1/5 medial of the muscle.

**V-Y gluteal perforator flap:** The v-y gluteal perforator flap is another possible variant of the gluteal flap.

Perforator vessels used for the v-y flap are derived from either the upper or the lower gluteal arteries.

The skin adjacent to the gluteal defect is used to form a v-y advancement flap without the need for gluteus maximus dissection [62]. Consequently, the entire pedicle is detached from the underlying muscle leaving only the connection with the perforator vessels. These v-y flaps based on perforators allow greater skin mobility than conventional v-y flaps.

### Pudendal flaps

These flaps are based on the internal pudendal artery (the terminal branch of the internal iliac artery) and have been used in many cases for perineal reconstruction [63], more for perineal coverage than for pelvic filling [57]. This flap was often chosen for perineal reconstruction after cylindrical amputation.

These flaps are based on perforators irrigated by vessels derived from the internal pudendal artery with various types of pedicle mobility and shape. There are between 3-5 perforators on an area of 6 sq cm between the medial edge of the gluteus maximus and the vulva. A very large flap from the intergluteal cleft can be harvested on these perforators and used to fill the adjacent perineal defect. The literature describes many flaps based on the internal pudendal artery (the terminal branch of the internal iliac artery) that have received various names: the gluteal fold flap [64,65], the lotus petal flap [66] and the Singapore flap [67], but they all depend on the perforators of the internal pudendal artery with various pedicle patterns.

### The gluteal fold flap

Described by Yui and Niranjana in 1996, GFF [66] is a fasciocutaneous flap based on the perforators of the internal pudendal artery that appear near the median line of the perineum between the anus and the ischial tuberosity [63].

It was originally used in vulvar and vaginal reconstruction after tumor excision [68].

The authors described it as a flap model with a base around the vaginal opening that resembles the petals of a lotus flower—that is why it was called the “lotus petal flap” [34]. Pantelides HM et al. considers that the gluteal fold flap is an excellent option for perineal reconstruction after anorectal excision for anorectal cancer [69]. The flap remains viable due to the rich anastomotic blood network, brings a reasonable volume of tissue to fill the pelvic “dead space” and can be used bilaterally or in combination with other flaps. It has a 100% survival rate and allows primary healing even in previously irradiated regions. In practice, the shape of the flap is cut to meet the needs of the local defect, but the long axis of the flap is centered over the inferior gluteal fold.

### Thigh flaps

The following are described:

- a. Gracilis flap
- b. Anterolateral thigh flap
- c. Posterior thigh flap

**Gracilis flap:** The gracilis muscle is a narrow muscle that starts

from the pubic symphysis, the inferior ramus of the pubis and the ischion in order to insert distally on the medial condyle of the knee. It is vascularized by the medial circumflex femoral vessels. Although the gracilis flap is not a perforator flap per se [70], the sequelae remaining after harvesting are associated with minimal functional dysfunctions [71,72]. Only the proximal pedicle has satisfactory blood irrigation. To improve reconstructive techniques with optimal donor site preservation, Hallock [73] proposed a variant based on the myocutaneous perforator vessels of the gracilis muscle, the medial circumflex femoral gracilis perforator flap.

**b. Anterolateral thigh flap:** Reconstruction with the anterolateral thigh flap is an interesting option for situations where the conventional donor site is not available for a long time [74]. This is one of the most popular perforator flaps in plastic surgery [75]. The pedicle is harvested from the anterolateral thigh surface and is irrigated by perforator vessels derived from the descending branch of the lateral circumferential femoral artery [76]. The dissection of this artery as far as possible from its origin provides a sufficient arc of rotation to reach the posterior perineum [57].

**c. Posterior thigh flap:** The flap is vascularized by the lower gluteal artery and its downstream branches. The main limiting factor is the laxity of the posterior thigh, which should allow primary donor site closure. The flap should be bilateral to provide sufficient volume. The posterior thigh flap, described by Hurwitz in 1981, [77] is a widely used solution for sensitive reconstruction (vaginal reconstruction in particular) [78,79].

Although multiple reconstruction variants are available, each comes with its own advantages and disadvantages (Table IV), depending on the specific profile of each case. Choosing a surgical treatment strategy is challenging, with caution to be taken on all the variables involved and with the support of a vast experience of the surgical team. However, because the modern approach is to develop and follow protocols based on decisional algorithms, surgical teams should be well informed on the latest studies on these subjects. An example of a decision tree algorithm for perineal reconstruction is illustrated in Figure 1 (Table IV).

### Conclusion

Immediate pelviperineal reconstruction following abdominoperineal resection is associated with superior primary healing, decreased postoperative complications, rapid recovery and reinsertion with increased quality of life for the patient.

With multiple reconstruction options available after abdominoperineal resection, a better knowledge of the surgical techniques and recent progresses might help the surgeon to take the best choice for each patient, as there are no official protocols available.

The chosen reconstructive technique must offer a balance between the reconstructive requirements and the donor site morbidity. Muscular and myocutaneous flaps have been until recently considered to be the “gold standard” for perineal reconstruction.

Technical advancements have been recently made with the use of perforator flaps, which are considered new reconstructive options; these flaps have led to lower morbidity rates, thus extending the reconstructive options for plastic surgeons.

Facing a variety of available reconstructive options, the choice to be taken relies on knowing the advantages and disadvantages of each technique, a multidisciplinary approach and the use of trusted decisional reconstruction algorithms.

Table IV: Pelvipereineal flap reconstruction-advantages and disadvantages.

Pelvi-perineal flap reconstruction		
Donor site	Advantages	Disadvantages
1. Abdominal flaps - VRAM - Ms-VRAM - FS-VRAM - DIEP	-Single patient position -Reliability -Good Volume -No additional donor site required with laparotomy present	-VRAM: abdominal sequelae -DIEP: muscle transaction limits the flap advantages -Stoma next to the incision -Deformation of the abdominal wall
2. Gluteal flaps - SGAP - IGAP - IGAM	-Abdominal incision avoided -Possible bilateral -Adapted for cylindrical abdominoperineal excision -Single position	-Preoperative imaging required -Radiation area involved -Limited arc of rotation
3. Pudendal flaps - Pudendal flap - Gluteal fold flap (GFF) - Lotus flap - Singapore flap	-Same as Gluteal flaps -Residual scar in gluteal sulcus	-Preoperative imaging required -Radiation area involved -Limited arc of rotation
4. Gracilis flap	-Use of non-irradiated area -Minimal functional sequelae	-Small volume -Inconstancy of distal skin paddle
5. Posterior thigh flap	-Use of non-irradiated area -Preserved sensitivity	-Small volume -"Stocking seam" donor site scar

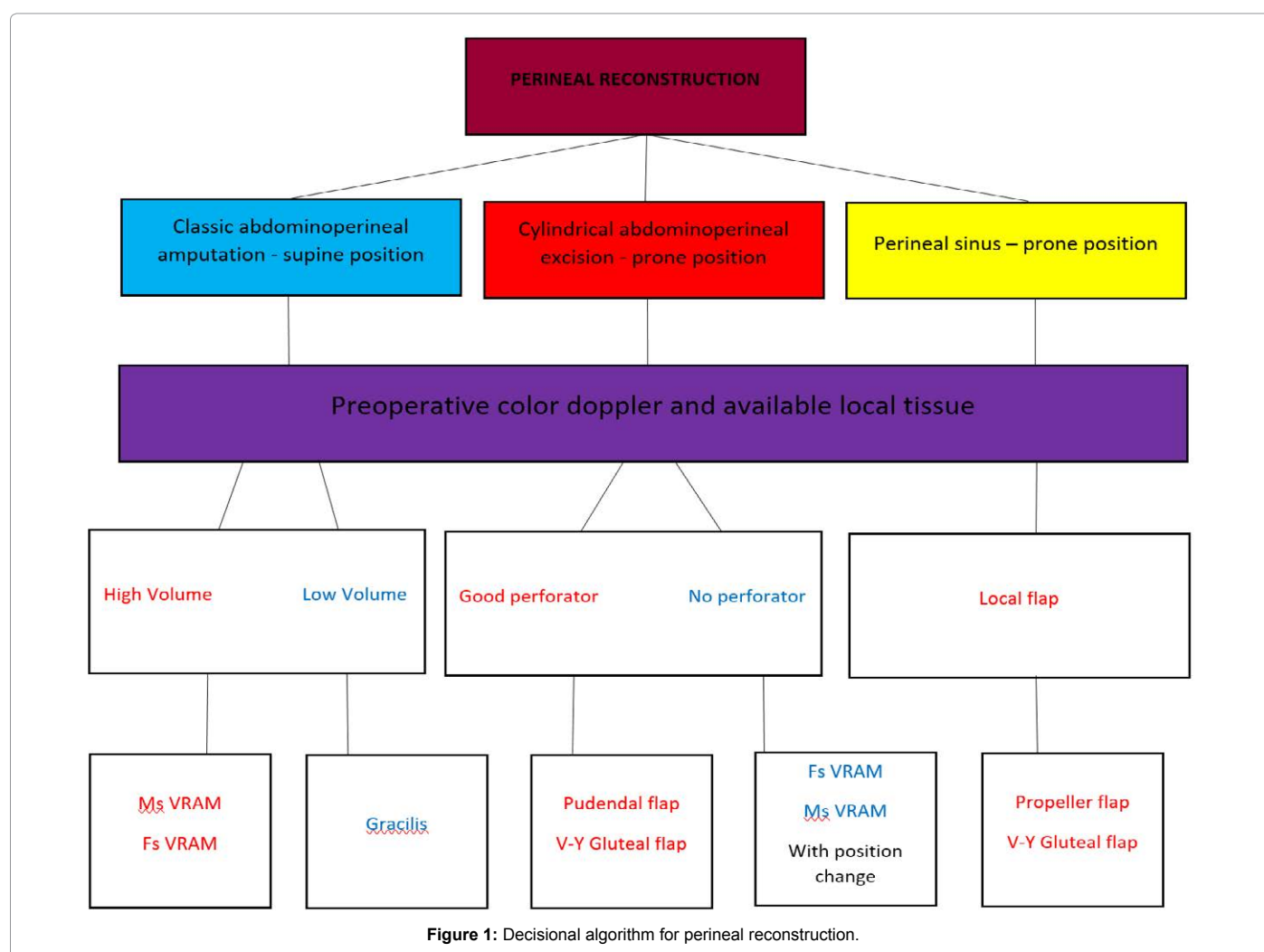


Figure 1: Decisional algorithm for perineal reconstruction.

## Conflict of Interest

Authors have no conflict of interest to disclose.

## References

- Mauvais F, Sabbagh C, Brehant O, Viart L, Benhaim T, et al. (2011) The current abdominoperineal resection: oncological problems and surgical modifications for low rectal cancer. J Visc Surg 148: e85-93.
- Miles WE (1908) A method of performing abdomino-perineal excision for carcinoma of the rectum and of the terminal portion of the pelvic colon. Lancet 21: 1812-1813.
- Stăngu C, Mitulescu G, Ungureanu C, Popescu I (2017) Reconstructia defectelor tisulare după exenterația pelvină totală. Chirurgia, 102(4) 389-399.
- Artioukh DY, Smith RA, Gokul K (2007) Risk factors for impaired healing of the perineal wound after abdominoperineal resection of rectum for carcinoma. Colorectal Dis 9: 362-367.
- Pollard CW, Nivatvongs S, Rojanasakul A, Ilstrup DM (1994) Carcinoma of the rectum. Profiles of intraoperative and early postoperative complications. Dis Colon Rectum 37: 866-874.

6. Rothenberger DA, Wong WD (1992) Abdominoperineal resection for adenocarcinoma of the low rectum. *World J Surg* 16: 478-485.
7. Rosen L, Veidenheimer MC, Collier JA, Corman ML (1982) Mortality, morbidity, and patterns of recurrence after abdominoperineal resection for cancer of the rectum. *Dis Colon Rectum* 25: 202-208.
8. Papaconstantinou HT, Bullard KM, Rothenberger DA, Madoff RD (2006) Salvage abdominoperineal resection after failed Nigro protocol: modest success, major morbidity. *Colorectal Dis* 8: 124-129.
9. Kokosis G, Sun Z, Avashia YJ, Adam MA, Levinson H, et al. (2017) V-Y fasciocutaneous flap closure technique is a safe and efficacious alternative to primary closure of the perineal wound following abdominoperineal resection. *Am J Surg* 213: 371-376.
10. Shekter CC, Shakir A, Vo H, Tsai J, Nazerali R, et al. (2016) Reconstruction following abdominoperineal resection (APR): Indications and complications from a single institution experience. *J Plast Reconstr Aesthet Surg* 69: 1506-1512.
11. Woods JE, Beart RW (1983) Reconstruction of nonhealing perineal wounds with gracilis muscle flaps. *Ann Plast Surg* 11: 513-516.
12. Sinna R, Alharbi M, Assaf N, Perignon D, Qassemayr Q, et al. (2013) Management of the perineal wound after abdominoperineal resection. *J Visc Surg* 150: 9-18.
13. Jurado M, Bazán A, Elejabertia J, Paloma V, Martínez-Monge R, et al. (2000) Primary vaginal and pelvic floor reconstruction at the time of pelvic exenteration: a study of morbidity. *Gynecol Oncol* 77: 293-297.
14. Kroll SS, Pollock R, Jessup JM, Ota D (1989) Transpelvic rectus abdominis flap reconstruction of defects following abdominal-perineal resection. *Am Surg* 55: 632-637.
15. O'Connell C, Mirhashemi R, Kassira N, Lambrou N, McDonald WS (2005) Formation of functional neovagina with vertical rectus abdominis musculocutaneous (VRAM) flap after total pelvic exenteration. *Ann Plast Surg* 55: 470-473.
16. Radice E, Nelson H, Mercill S, Farouk R, Petty P, et al. (1999) Primary myocutaneous flap closure following resection of locally advanced pelvic malignancies. *Br J Surg* 86: 349-354.
17. Pemberton JH (2003) How to treat the persistent perineal sinus after rectal excision. *Colorectal Dis* 5: 486-489.
18. Robles CR, Garcia AJ, Parrila PP, Cifuentes J, Lujan MJA, et al. (1992) Management of the perineal wound following abdominoperineal resection: prospective study of three methods. *Br J Surg* 79: 29-31.
19. Moreaux J, Horiot A, Barrat F, Mabilie J (1984) Obliteration of the pelvic space with pedicled omentum after excision of the rectum for cancer. *Am J Surg* 148: 640-644.
20. John H, Buchmann P (1991) Improved perineal wound healing with the omental pedicle graft after rectal excision. *Int J Colorectal Dis* 6: 193-196.
21. De Broux E, Parc Y, Rondelli F, Dehni N, Turet E, et al. (2005) Sutured perineal omentoplasty after abdominoperineal resection for adenocarcinoma of the lower rectum. *Diseases of the Colon and Rectum* 48: 476-481.
22. Althumairi AA, Canner JK, Gearhart SL, Safar B, Sacks J, et al. (2016) Predictors of perineal wound complications and prolonged time to perineal wound healing after abdominoperineal resection. *World J Surg* 40: 1755-1762.
23. Nisar PJ, Scott HJ (2009) Myocutaneous flap reconstruction of the pelvis after abdominoperineal excision. *Colorectal Dis* 11: 806-816.
24. Kusunoki M, Yanagi H, Shoji Y, Noda M, Ikeuchi H, et al. (1999) Reconstruction of the pelvic floor using absorbable mesh with a bioresorbable membrane (Septrafil) after abdominoperineal rectal excision. *J Surg Oncol* 70: 261-262.
25. Wille-Jørgensen P, Pilsgaard B, Møller P (2009) Reconstruction of the pelvic floor with a biological mesh after abdominoperineal excision for rectal cancer. *Int J Colorectal Dis* 24: 323-325.
26. Becker JM, Dayton MT, Fazio VW, Beck DE, Stryker SJ, et al. (1996) Prevention of postoperative abdominal adhesions by a sodium hyaluronate-based bioresorbable membrane: A prospective, randomized, double-blind multicenter study. *J Am Coll Surg* 183: 297-306.
27. Burns JW, Colt MJ, Burgees LS, Skinner KC (1997) Preclinical evaluation of Septrafil bioresorbable membrane. *Eur J Surg Suppl* 577: 40-48.
28. Diamond MP (1996) Reduction of adhesions after uterine myomectomy by Septrafil membrane (HAL-F): a blinded, prospective, randomized, multicenter clinical study. *Septrafil Adhesion Study Group. Fertil Steril* 66: 904-910.
29. Han JG, Wang ZJ, Gao ZG, Xu HM, Yang ZH, et al. (2010) Pelvic floor reconstruction using human acellular dermal matrix after cylindrical abdominoperineal resection. *Dis Colon Rectum* 53: 219-223.
30. Wong AK, Schommeyr B, Singh P, Carlson DL, Li S, et al. (2008) Histologic analysis of angiogenesis and lymphangiogenesis in acellular human dermis. *Plast Reconstr Surg* 121: 1144-1152.
31. Butler CE, Langstein HN, Kronowitz SJ (2005) Pelvic, abdominal, and chest wall reconstruction with AlloDerm in patients at increased risk for mesh-related complications. *Plast Reconstr Surg* 116: 1263-1275.
32. Glasberg SB, D'Amico RA (2006) Use of regenerative human acellular tissue (AlloDerm) to reconstruct the abdominal wall following pedicle TRAM flap breast reconstruction surgery. *Plast Reconstr Surg* 118: 8-15.
33. Gupta A, Zahriya K, Mullens PL, Salmassi S, Keshishian A (2006) Ventral herniorrhaphy: experience with two different biosynthetic mesh materials, Surgisis and AlloDerm. *Hernia* 10: 419-425.
34. Sinna R, Qassemayr Q, Benhaim T, Lauzanne P, Sabbagh C, et al. (2010) Perforator flaps: A new option in perineal reconstruction. *J Plast Reconstr Aesthet Surg* 63: e766-774.
35. Buchel EW, Finical S, Johnson C (2004) Pelvic reconstruction using vertical rectus abdominis musculocutaneous flaps. *Ann Plast Surg* 52: 22-26.
36. McCraw J, Kemp G, Given F, Horton CE (1988) Correction of high pelvic defects with the inferiorly based rectus abdominis myocutaneous flap. *Clin Plast Surg* 15: 449-454.
37. Sunesen KG, Buntzen S, Tei T, Lindegaard JC, Nørgaard M, et al. (2009) Perineal healing and survival after anal cancer salvage surgery: 10-year experience with primary perineal reconstruction using the vertical rectus abdominis myocutaneous (VRAM) flap. *Ann Surg Oncol* 16: 68-77.
38. Nelson RA, Butler CE (2009) Surgical outcomes of VRAM versus thigh flaps for immediate reconstruction of pelvic and perineal cancer resection defects. *Plast Reconstr Surg* 123: 175-183.
39. Lee MJ, Dumanian GA (2004) The oblique rectus abdominis musculocutaneous flap: revisited clinical applications. *Plast Reconstr Surg* 114: 367-673.
40. McCraw JB, Massey FM, Shanklin KD, Horton CE (1976) Vaginal reconstruction with gracilis myocutaneous flaps. *Plast Reconstr Surg* 58: 176-183.
41. Heath PM, Woods JE, Podratz KC, Arnold PG, Irons GB (1984) Gracilis myocutaneous vaginal reconstruction. *Mayo Clin Proc* 59: 21-24.
42. Sinna R, Qassemayr Q, Pérignon D, Benhaim T, Robbe M (2011) About perforator flaps...20 years later. *Ann Chir Plast Esthet* 56: 128-133.
43. Sinna R, Boloorchi A, Mahajan AL, Qassemayr Q, Robbe M (2010) What should define a "perforator flap"? *Plast Reconstr Surg* 126: 2258-2263.
44. Sinna R (2011) Reply: The nomenclature of perforator flaps. *Plast Reconstr Surg* 128: 334-335.
45. Kuntscher MV, Mansouri S, Noack N, Hartmann B (2006) Versatility of vertical rectus abdominis musculocutaneous flaps. *Microsurgery* 26: 363-369.
46. Zienowicz RJ, May JW (1995) Hernia prevention and aesthetic contouring of the abdomen following TRAM flap breast reconstruction by the use of polypropylene mesh. *Plast Reconstr Surg* 96: 1346-1350.
47. Bell SW, Dehni N, Chaouat M, Lifante JC, Parc R, et al. (2005) Primary rectus abdominis myocutaneous flap for repair of perineal and vaginal defects after extended abdominoperineal resection. *Br J Surg* 92: 482-486.
48. Abbott DE, Halverson AL, Wayne JD, Kim JY, Talamonti MS, et al. (2008) The oblique rectus abdominal myocutaneous flap for complex pelvic wound reconstruction. *Dis Colon Rectum* 51: 1237-1241.
49. Nohira K, Shintomi Y, Hosokawa M, Yajima K, Sasaki S, et al. (1999) TRAM flap breast reconstruction using a fascia-sparing technique. *Nihon Geka Gakkai Zasshi* 100: 547-550.
50. Erni D, Harder YD (2003) The dissection of the rectus abdominis myocutaneous flap with complete preservation of the anterior rectus sheath. *Br J Plast Surg* 56: 395-400.
51. Man LX, Selber JC, Serletti JM (2009) Abdominal wall following free TRAM or DIEP flap reconstruction: A meta-analysis and critical review. *Plast Reconstr Surg* 124: 752-764.
52. Granzow JW, Levine JL, Chiu ES, Allen RJ (2006) Breast reconstruction with the deep inferior epigastric perforator flap: history and an update on current technique. *J Plast Reconstr Aesthet Surg* 59: 571-579.
53. Fang BR, Ameet H, Li XF, Lu Q, Wang XC, et al. (2011) Pedicled thinned deep inferior epigastric artery perforator flap for perineal reconstruction: a preliminary report. *J Plast Reconstr Aesthet Surg* 64: 1627-1634.

54. Wang X, Qiao Q, Burd A, Liu Z, Zhao R, et al. (2007) A new technique of vaginal reconstruction with the deep inferior epigastric perforator flap: A preliminary report. *Plast Reconstr Surg* 119: 1785-1790.
55. Zeng A, Xu J, Yan X, You L, Yang H (2006) Pedicled deep inferior epigastric perforator flap: an alternative method to repair groin and scrotal defects. *Ann Plast Surg* 57: 285-288.
56. Wang X, Qiao Q, Burd A, Liu Z, Zhao R, et al. (2006) Perineum reconstruction with pedicled anterolateral thigh fasciocutaneous flap. *Ann Plast Surg* 56: 151-155.
57. Gangloff D, Ferron GE, Garrido I (2006) Reconstruction pelvi-perineale. EMC (Elsevier SAS, Paris) Technique chirurgicales. Chirurgie plastique reconstructrice et esthétique.
58. Leow M, Lim J, Lim TC (2004) The superior gluteal artery perforator flap for the closure of sacral sores. *Singapore Med J* 45: 37-39.
59. Acartürk TO, Parsak CK, Sakman G, Demircan O (2010) Superior gluteal artery perforator flap in the reconstruction of pilonidal sinus. *J Plast Reconstr Aesthet Surg* 63: 133-139.
60. Wagstaff MJ, Rozen WM, Whitaker IS, Enajat M, Audolfsson T, et al. (2009) Perineal and posterior vaginal wall reconstruction with superior and inferior gluteal artery perforator flaps. *Microsurgery* 29: 626-629.
61. Boccola MA, Rozen WM, Ek EW, Teh BM, Croxford M, et al. (2010) Inferior gluteal artery myocutaneous island transposition flap reconstruction of irradiated perineal defects. *J Plast Reconstr Aesthet Surg* 63: 1169-1175.
62. Benito P, García J, Juan A, Alcazar JA, Elena E, et al. (2009) Reconstruction of a perianal defect by means of a bilateral V-Y advancement flap based on the perforating arteries of the gluteus maximus shaped over a cicatricial area. *J Plast Reconstr Aesthet Surg* 62: 412-414.
63. Hashimoto I, Murakami G, Nakanishi H, Sakata-Haga H, Seike T, et al. (2001) First cutaneous branch of the internal pudendal artery: an anatomical basis for the so-called gluteal fold flap. *Okajimas Folia Anat Jpn* 78: 23-30.
64. Winterton RI, Lambe GF, Ekwobi C, Oudit D, Mowatt D, et al. (2013) Gluteal fold flaps for perineal reconstruction. *J Plast Reconstr Aesthet Surg* 66: 397-405.
65. Hashimoto I, Nakanishi H, Nagae H, Harada H, Sedo H (2001) The gluteal-fold flap for vulvar and buttock reconstruction: anatomic study and adjustment of flap volume. *Plast Reconstr Surg* 108: 1998-2005.
66. Yii NW, Niranjana NS (1996) Lotus petal flaps in vulvo-vaginal reconstruction. *Br J Plast Surg* 49: 547-554.
67. Sawada M, Kimata Y, Kasamatsu T, Yasumura T, Onda T, et al. (2004) Versatile lotus petal flap for vulvoperineal reconstruction after gynecological ablative surgery. *Gynecol Oncol* 95: 330-335.
68. David FB (1972) Constructing confidence sets using rank statistics. *J Am Stat Assoc* 67: 687-690.
69. Pantelides NM, Davies RJ, Fearnhead NS, Malata CM (2013) The gluteal fold flap: a versatile option for perineal reconstruction following anorectal cancer resection. *J Plast Reconstr Aesthet Surg* 66: 812-820.
70. Peek A, Müller M, Ackermann G, Exner K, Baumeister S (2009) The free gracilis perforator flap: anatomical study and clinical refinements of a new perforator flap. *Plast Reconstr Surg* 123: 578-588.
71. Deutinger M, Kuzbari R, Paternostro-Sluga T, Quittan M, Zauner-Dungl A, et al. (1995) Donor-site morbidity of the gracilis flap. *Plast Reconstr Surg* 95: 1240-1244.
72. Carr MM, Manktelow RT, Zuker RM (1995) Gracilis donor site morbidity. *Microsurgery* 16: 598-600.
73. Hallock GG (2004) Further experience with the medial circumflex femoral (GRACILIS) perforator free flap. *J Reconstr Microsurg* 20: 115-122.
74. Luo S, Raffoul W, Piaget F (2000) Anterolateral thigh fasciocutaneous flap in the difficult perineogenital reconstruction. *Plast Reconstr Surg* 105: 171-173.
75. Wei FC, Jain V, Celik N, Chen HC, Chuang DC, et al. (2002) Have we found an ideal soft-tissue flap? An experience with 672 anterolateral thigh flaps. *Plast Reconstr Surg* 109: 2219-2226.
76. Zhang Q, Qiao Q, Gould LJ, Myers WT, Phillips LG (2010) Study of the neural and vascular anatomy of the anterolateral thigh flap. *J Plast Reconstr Aesthet Surg* 63: 365-371.
77. Hurwitz DJ, Swartz WM, Mathes SJ (1981) The gluteal thigh flap: a reliable, sensate flap for the closure of buttock and perineal wounds. *Plast Reconstr Surg* 68: 521-532.
78. Achauer BM, Turpin IM, Furnas DW (1983) Gluteal thigh flap in reconstruction of complex pelvic wounds. *Arch Surg* 118: 18-22.
79. Oomen JW, Spauwen PH, Bleichrodt RP, Goor H (2007) Guideline proposal to reconstructive surgery for complex perineal sinus or rectal fistula. *Int J Colorectal Dis* 22: 225-230.