

## Unusual Location of Primary Hydatid Cyst: Soft Tissue Mass in the Supraclavicular Region of the Neck

Slim Jarboui<sup>1\*</sup>, Abdelwaheb Hlel<sup>1</sup>, Alifa Daghfous<sup>2</sup> and Andre Lepandru<sup>1</sup>

<sup>1</sup>Department of general Surgery of Sidi Bouzid Hospital-Tunisia

<sup>2</sup>Department of Radiology in Trauma Center of Ben Arous –Tunisia

### Abstract

**Introduction:** Hydatid cyst is a zoonosis caused by *Echinococcus granulosus*. It may affect any organ and tissue in the body, in particular the liver and Lung. Musculoskeletal or soft tissue hydatidosis accounts for about 0.5 – 5% of all echinococcal infections in endemic areas, and is almost secondary to the hepatic or pulmonary disease.

**Case presentation:** We report an unusual case of primary subcutaneous hydatidosis in the left supraclavicular region of the neck. A 53 year old female patient was admitted with three months history of pain and gradually growing mass located in the left supraclavicular region. Physical examination revealed a moderately hard, painful and erythematous mass. The blood cell count was normal. Computed tomography demonstrated, a multilocular cystic lesion with thin borders, thin wall. The mass is binocular and extend to the scapula. CT showed no involvement of the lung. From these signs the patient was diagnosed as having abscess (bacterial infection or tuberculosis). The diagnosis of *Echinococcus granulosus* infection was made preoperatively after visualization of the cyst wall and the daughter cysts. Following irrigation of cystic cavity with hypertonic saline solution, the cyst wall was excised along with a portion of surrounding tissue. Histopathological examination of the specimen confirmed the hydatid origin. Hemagglutination tests for *Echinococcus* and ELISA were negative. Ultrasound of the abdomen was normal. The patient received albendazole (400 mg/day) for 8 weeks postoperatively. No sign of recurrence could be detected by physical examination and imaging (CT) at 4-month follow-up.

**Conclusion:** The case illustrate that echinococcal disease should be considered in the differential diagnosis of every cystic mass in every anatomic location, especially when they occur in endemic areas.

**Keywords:** Hydatid cyst; *Echinococcus*; Supraclavicular region; Neck; Albendazole

### Introduction

Hydatid disease is an important infestation caused by the parasite *Echinococcus granulosus* and still common in countries in the temperate zones, including the Mediterranean countries, the Middle East, South America, New Zealand, Australia and Southeast Asia. Hydatids are mostly found in the liver and/or in lungs for physiopathological reasons, but several other encysting sites are possible, bone included. The musculoskeletal involvement has been registered in only 1- 4% of the cases. It has been hypothesized that the presence of lactic acid in the muscle does not allow the larvae to grow into cysts. Only few cases of primary subcutaneous hydatidosis have been reported and even in regions with echinococcosis is endemic, hydatidosis of cervicofacial region is extremely rare.

We would like to point out that, regardless of the site involved, this zoonotic infection should always be considered in the differential diagnosis of any cystic lesion.

### Case Report

A 53- year-old woman presented to our hospital with a three month history of painful mass growing on the left lateral side of the neck. She reported neither fever nor a weight loss. Upon physical examination, some hard, painful and fluctuant with 10 x 7 cm was palpable on the supraclavicular region of the lateral neck. The overlying skin was inflammatory. We didn't found any regional lymphadenopathy. The blood cell count was normal except an increased erythrocyte sedimentation rate (ESR 40 mm/h). No abnormality was found in chest X- ray.

CT scan demonstrated a binocular mass on the left supraclavicular region with cystic aspect. Its dimensions 14x10 cm and containing

numerous cystic formations with thin outlines (Figure 1). From this clinical and radiographic signs, the patient was diagnosed as having pyogenic abscess or tuberculosis and its excision or drainage was planned. The diagnosis of *Echinococcus granulosus* infection was confirmed preoperatively after visualization of the cyst wall and daughter cysts (Figure 2). A purulent liquid was drained. Following irrigation of cystic cavity with hypertonic saline solution, the cyst wall was excised with a portion of overlying skin and muscle (Figure 3). Histopathological examination of the specimen revealed hydatid cyst. Scoleces were also detected within the surgical specimen (Figure 4). The patient was subjected to ultrasound of the abdomen and urologic examination. Hemagglutination tests for *Echinococcus* and ELISA were negative. The investigation did not reveal any extra cervical sites for other hydatid cyst. The patient received Albendazole (400 mg/day) for eight weeks postoperatively. No sign of recurrence could be detected by physical examination and imaging at the 4-month follow-up.

### Discussion

Hydatid cyst disease is still a major health problem in agricultural countries including Tunisia. The parasite is named *Echinococcus granulosus* and humans can be an incidental intermediary host in the life cycle of the parasite. Although cysts are most commonly located in

**\*Corresponding author:** Slim Jarboui, Department of general Surgery of Sidi Bouzid Hospital-Tunisia, Tel: 98339887; E-mail: [drslimjarboui@yahoo.fr](mailto:drslimjarboui@yahoo.fr)

Received May 01, 2012; Accepted May 19, 2012; Published May 30, 2012

**Citation:** Jarboui S, Hlel A, Daghfous A, Lepandru A (2012) Unusual Location of Primary Hydatid Cyst: Soft Tissue Mass in the Supraclavicular Region of the Neck. J Clin Case Rep 2:151. doi:10.4172/2165-7920.1000151

**Copyright:** © 2012 Jarboui S, et al. This is an open-access article distributed under the terms of the Creative Commons Attribution License, which permits unrestricted use, distribution, and reproduction in any medium, provided the original author and source are credited.

the liver (50-650%) and the lungs (20-30%), multi-organ involvement is seen in 20-30% of cases [1-4]. The musculoskeletal involvement has been registered in only 1-5 % [3,4]. It has been hypothesized that the presence of lactic acid in the muscle does not allow the larvae to grow into cysts. Soft – tissue hydatid cysts occur in 2-3% of cases reported from endemic areas [1-3].

Diagnosis of *Echinococcus* should be considered when slowing growing soft tissue is present in patient from a rural area especially endemic country. The clinical manifestation of the disease is a result of the localization and pressure effect of the slowly growing cyst on the infected organ. The main complaints of patients have been pain and sense of malaise [1,3,5,6]. As in our case, clinical findings and physical examination did not reveal the correct diagnosis. Our initial diagnosis was soft tissue suppuration or tuberculosis. *Echinococcus granulosus* infection may also mimic malignancy because of sudden enlargement of the cyst and the formation of structural deformities in the tissue over time.

Echinococcosis is diagnosed essentially by the patient's history, physical examination findings, radiologic imaging modalities, and serological tests. Although imaging methods usually exhibit nonspecific findings, they may be helpful for making the diagnosis. Ultrasonography, computed tomography and magnetic resonance imaging can imaging the association of the cyst with neighboring tissues, the internal laminar wall of the cyst, and intraluminal daughter cysts [1,5-7]. As in our case, the diagnosis was missed in the CT scan of the neck and chest and the mass was reported as a simple cystic structure. Abdominal and chest X- rays, ultrasound and CT scans should be performed in order to investigate various organ involvements, particularly liver and lungs.

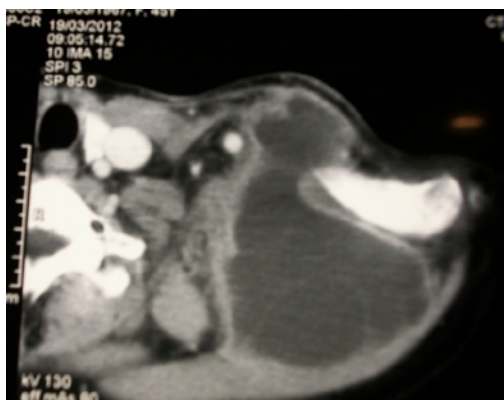


Figure 1: CT scan demonstrated cystic structure in the left supraclavicular region with multivesicular lesions.

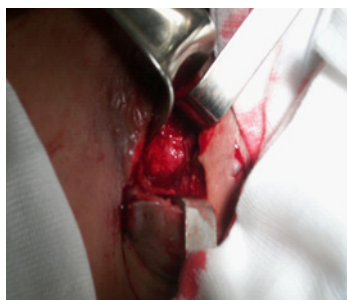

Figure 2: Subcutaneous hydatid cyst in the left supraclavicular region of the neck.

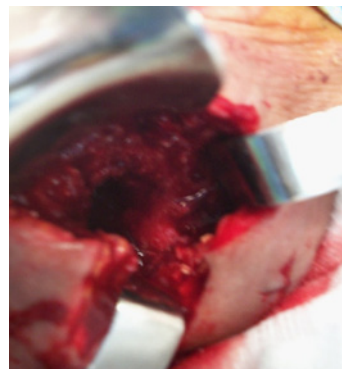


Figure 3: Operative field after cyst resection. The cyst pouch was irrigated with protoscolicidal solutions.

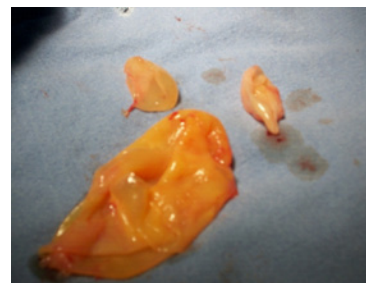


Figure 4: A view of the resected cyst and its germinative membrane with daughter cysts.

Eroglu et al. [8], Iynen et al. [4], each have been reported an unusual case of hydatid cyst found in the neck, and just like our case report, there was no pulmonary or hepatic involvement.

To confirm diagnosis serologic tests, including direct hemagglutination, latex agglutination, immunoelectrophoresis, skin tests, and Enzyme-Linked Immunosorbent Assay (ELISA) are widely used. However, all serologic tests have low diagnostic sensitivity and specificity. Hydatid serology is only valuable when it is positive, negative serologic test does not exclude the diagnosis. We performed hemagglutination test and ELISA test in our patient and the result was negative [1,2,4,7-10].

The best treatment option is total surgical excision without opening the cyst. If the cyst cannot be excised without opening, the fluid contents should be removed, the laminated membrane should be totally excised, and the cyst pouch should be irrigated with protoscolicidal solutions [2,4,7,8,11]. Subcutaneous located cysts are more prone to rupture since they have not been diagnosed pre operatively. Medical treatment with antihelminthic drugs, such as mebendazole and albendazole, should be included especially for disseminated, inaccessible hydatidosis and for patients who do not favor the morbidity of an operative process [4,8,10-14]. These drugs may also play an important role in conjunction with surgery, both preoperatively for sterilization of the cyst and postoperatively in case of spillage [4,12,14].

## Conclusion

This case illustrate that echinococcal disease should be considered in the differential diagnosis of every cystic mass in any anatomic location, especially when occur in areas where the disease is endemic like Tunisia.

## References

1. Karaman E, Yilmaz M, Ada M, Yilmaz RS, Isildak H (2011) Unusual location of primary hydatid cyst: Soft tissue mass in the parapharyngeal region. *Dysphagia* 26: 75-77.
2. Dirican A, Unal B, Kayaalp C, Kirimlioglu V (2008) Subcutaneous hydatid cysts occurring in the palm and the thigh: two case reports. *J Med Case Rep* 2: 273.
3. Kouskos E, Chatziantoniou J, Chrissafis I, Anitsakis C, Zamtrakis S (2007) Uncommon locations of hydatid cysts. *Singapore Med J* 48: e119-e121.
4. Iynen I, Sogut O, Guldur ME, Kose R, Kaya H, et al. (2011) Primary hydatid cyst: an unusual cause of a mass in the supraclavicular region of the neck. *J Clin Med Res* 3: 52-54.
5. Orhan Z, Kara H, Tuzuner T, Sencan I, Alper M (2003) Primary subcutaneous cyst hydatid disease in proximal thigh: an unusual localisation: a case report. *BMC Musculoskelet Disord* 4: 25.
6. Ozsoy M, Keles C, Kahya M, Keles G (2011) Primary echinococcal cyst in the axillary region. *J Infect Dev Ctries* 5: 825-827.
7. Vicidomini S, Cancrini G, Gabrielli S, Naspetti R, Bartoloni A (2007) Muscular cystic hydatidosis: case report. *BMC Infect Dis* 7: 23.
8. Eroglu A, Atabekoglu S, Kocaoglu H (1999) Primary hydatid cyst of the neck. *Eur Arch Otorhinolarygol* 256: 202-204.
9. Ates M, Karakaplan M (2007) Hydatid cyst in the biceps and gluteus muscles: case report. *Surg Infect (Larchmt)* 8: 475-478.
10. Kayaalp C, Dirican A, Aydin C (2001) Primary subcutaneous hydatid cysts: a review of 22 cases. *Int J Surg* 9: 117-121.
11. Ozturk S, Devec M, Yildirim S (2001) Hydatid cyst in the soft tissue of the face without any primary. *Ann Plast Surg* 46: 170-173.
12. Yildirim M, Erkan N, Vardar E (2006) Hydatid cysts with unusual localizations: diagnostic and treatment dilemmas for surgeons. *Ann Trop Med Parasitol* 100: 137-142.
13. Cöl C, Cöl M, Lafçi H (2003) Unusual localizations of hydatid disease. *Acta Med Austriaca* 30: 61-64.
14. Cannon CP, Nelson SD, Panosian CB, Seeger LL, Eilber FR, et al. (2001) Soft tissue echinococcosis: a report of two cases and review of the literature. *Clin Orthop Relat Res* 186-191.