

Case Report

Open Access

Unilateral Live Tubal Twin Ectopic Pregnancy

Aneeta Bai, Maysea Eltayg, Jayakumari Perchani, Kuntal Rao and Vaidyanathan Gowri*

Department of Obstetrics and Gynecology, Sultan Qaboos University Hospital, Muscat, Sultanate of Oman, Oman

Keywords: Ectopic pregnancy; Uterus; Human chorionic gonadotropin

Introduction

Twin pregnancy in the fallopian tube is quite rare with a reported incidence of 1:200 ectopic pregnancies. It was, first described in 1891 by De Ott [1]. Unilateral live twin ectopic pregnancies are even rarer and occur at a frequency of 1 in 125,000 [2]. We present a case of twin ectopic pregnancy in the left fallopian tube with both live embryos.

Case History

A 36 year old gravida 3 para 0 presented to the emergency room with nine weeks pregnancy and severe lower abdominal pain. There was no associated vaginal bleeding, nausea or vomiting.

She had a miscarriage (in the first trimester) in her first pregnancy and her second pregnancy was a right sided ectopic pregnancy managed surgically with right salpingectomy 2 yrs back. There was no significant past medical or surgical history other than what is mentioned above.

Physical examination revealed that her vital signs at the time of admission were: blood pressure 114/95 mm of Hg; pulse rate 94/minute;-respiratory rate 20/minutes.

Systemic review was unremarkable. On abdominal examination there was mild tenderness with guarding in the left lower quadrant. Bimanual examination revealed a bulky uterus and tenderness in the left adnexa.

The hemoglobin level was 9.0 g/dL. Her serum beta human chorionic gonadotropin (hCG) was 61,798 mIU. Endovaginal ultrasound revealed an empty uterus and 2 live fetuses with cardiac activities in the left adnexa (Figure 1). Both ovaries were normal. A minimal amount of fluid was noted in the Cul de sac.

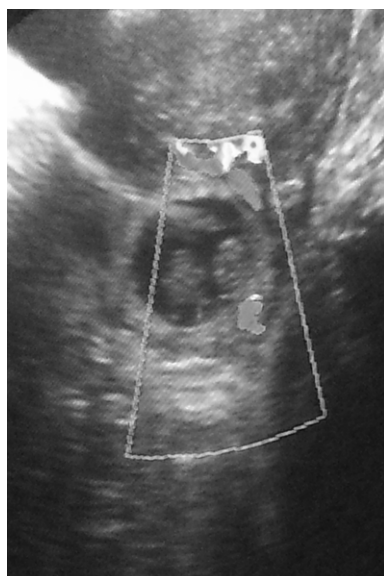


Figure 1: Endovaginal ultrasound revealed an empty uterus and 2 live fetuses with cardiac activities in the left adnexa.

Laparotomy was done in view of previous surgery and suspected adhesion. At laparotomy hemoperitoneum about 600 ml was present with clots. Both ovaries were adherent to the posterior aspect of the uterus. Right tube was absent due to previous surgery. Left tube was ruptured at the ampullary region, which was almost 4×5 cms in size. Two embryos with some cardiac activity were seen in two sacs with clear fluid around (Figure 2). Left salpingectomy was done after removal of embryos. Postoperative hemoglobin was 6.4 gm so two units of packed red blood cells were transfused. Salpingosotomy or partial salpingectomy as other treatment options were considered. There were many adhesions most probably due to her pelvic surgery and the ectopic pregnancy had ruptured with more than half the fallopian tube involvement. Hence Salpingostomy and salvaging the tube was not really possible.

Discussion

Ectopic pregnancies account for 2% of all pregnancies. It represents a major health risk for women of childbearing capacity, which can result in life-threatening complications if not treated properly. The incidence of ectopic pregnancies has been increasingly diagnosed due to early diagnostic measures like serum beta human chorionic beta hCG and high resolution ultrasound techniques. The classic clinical triad of ectopic pregnancy is pain, amenorrhea and vaginal bleeding. Risk factors that contribute to the incidence of ectopic pregnancy include pelvic inflammatory disease, previous ectopic pregnancy, history of tubal surgery, and conception after tubal ligation, use of fertility drugs and assisted reproductive technology. The risk factor in this patient was previous ectopic surgery.

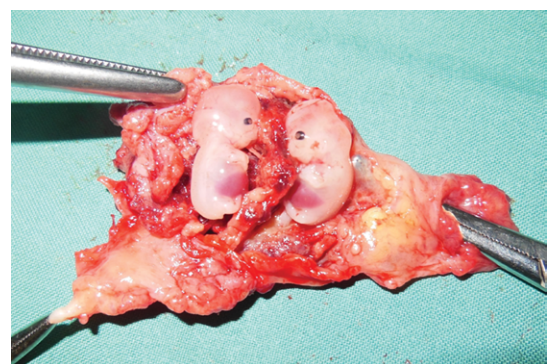


Figure 2: Ectopic pregnancy.

*Corresponding author: V Gowri, Department of Obstetrics and Gynecology, PO BOX 35, Postal code 123 Sultan Qaboos University, Muscat, Sultanate of Oman, Tel: +968 99416909; Fax: +968 24141162; E-mail: gowrie61@hotmail.com

Received February 26, 2014; Accepted March 28, 2014; Published March 31, 2014

Citation: Bai A, Eltayg M, Perchani J, Rao K, Gowri V (2014) Unilateral Live Tubal Twin Ectopic Pregnancy. J Clin Case Rep 4: 363. doi:10.4172/2165-7920.S1-001

Copyright: © 2014 Bai A, et al. This is an open-access article distributed under the terms of the Creative Commons Attribution License, which permits unrestricted use, distribution, and reproduction in any medium, provided the original author and source are credited.

Live twin-ectopic gestations are extremely rare. More than 100 twin tubal pregnancies have been reported, but 13 cases with cardiac activities demonstrated in both fetuses have been diagnosed [3]. The first case of live twin-ectopic pregnancy was described in 1994 [4]. Unilateral twin-ectopic pregnancies occur in 1:200 ectopic pregnancies [5]. Most cases are monochorionic and monozygotic [6]. A rare case of diamniotic dichorionic unilateral twin ectopic pregnancy was reported by Ghike et al. and it appears this patient also had a diamniotic dichorionic twin [7]. They result from the abnormal implantation and maturation of the conceptus outside the endometrial cavity. Diagnosis is made by transvaginal ultrasound and it is crucial to make the diagnosis as soon as possible so that conservative tubal surgery can be planned.

The diagnosis was made on time but the rupture started happening before the laparotomy preparation. Methotrexate was not an option due to the level of beta hCG and the size of the mass. Salpingectomy was necessary due to the size of the ectopic and as it had ruptured. She was counseled on *In vitro* fertilization. Laparoscopy is the standard of care but was not possible due to the lack of technical expertise as it was out of usual working hours.

Conclusion

Live twin-ectopic gestations are extremely rare but there are treatment options. These have typically been classified as either

conservative or surgical. Patients are sent for surgical intervention if they are at high risk of tubal rupture, hypotension, anemia or if they have an ectopic pregnancy >3 cm in diameter. Surgery was necessary in this patient due to high risk of rupture.

References

1. De Ott D (1891) A case of unilateral tubal twin gestation. *Annales de Gynecologie et d'Obstetrique*. 36:304.
2. Parker J, Hewson AD, Calder-Mason T, Lai J (1999) Transvaginal ultrasound diagnosis of a live twin tubal ectopic pregnancy. *Australas Radiol* 43: 95-97.
3. Summa B, Meinhold-Heerlein I, Bauerschlag DO, Jonat W, Mettler L, et al. (2009) Early detection of a twin tubal pregnancy by Doppler sonography allows fertility-conserving laparoscopic surgery. *Arch Gynecol Obstet* 279: 87-90.
4. Gualandi M, Steemers N, de Keyser JL (1994) [First reported case of preoperative ultrasonic diagnosis and laparoscopic treatment of unilateral, twin tubal pregnancy]. *Rev Fr Gynecol Obstet* 89: 134-136.
5. Breen JL (1970) A 21 years survey of 654 ectopic pregnancies. *Am J Obstet Gynecol* 106: 1004-1019.
6. Storch MP, Petrie RH (1976) Unilateral tubal twin gestation. *Am J Obstet Gynecol* 125: 1148.
7. Ghike S, Somalwar S, Mitra K, Kulkari S, Ladikar M, et al. (2011) Unilateral Twin Ectopic pregnancy (Diamniotic-Dichorionic): A Rare case. *Journal of South Asian Federation of Obstetrics and Gynecology* 3:103-105.

This article was originally published in a special issue, **Obstetrics and Gynecology** handled by Editor. Dr. Yigit Cakiroglu, Kocaeli University, Turkey