

Tuberculosis of a Single Lumbar Vertebra Presenting with a Solitary Local Osteolytic Lesion in Young Adults: A Report of Five Cases

Ping Zhen*, Xu-Sheng Li and Hao Lu

Department of Orthopedics, The General Hospital of PLA, Lanzhou, 333 Southern Binhe Road, Lanzhou 730050, Gansu Province, People's Republic of China

Introduction

Spinal tuberculosis in its classical form (i.e., “two-vertebra disease with the destruction of the intervening intervertebral disc and a paravertebral or psoas abscess”) is easily recognized and readily treated [1] in areas where tuberculosis is endemic [2-4]. Atypical spinal tuberculosis without the aforementioned clinical or radiographic features [5], although occurring less frequently [6], has been well documented [6-8]. However, only a few articles had reported the isolated tuberculosis which involved a single vertebral body [1,9,10]. Single vertebra tuberculosis presenting with a local solitary osteolytic lesion in normal architecture of the vertebral body is exceedingly rare in spinal tuberculosis, and there is limited information about this entity in the English-language literature [1,2,5,6-10].

The purpose of this report is to describe the five identified patients who suffered from single vertebra tuberculosis presenting in a form of local solitary osteolytic lesion with normal architecture and arrangement of the vertebral bodies. This unusual atypical pattern of spinal tuberculosis is studied to further characterize the radiological features and differential diagnosis of the single vertebra disease.

Case Reports

Case 1

A twenty-two-year-old woman presented with low back pain that had increased over the previous 2 months and radiated down her left leg. She denied weakness, gait disturbance, fever, or chills. She had ordered an MRI study to evaluate her low back pain further as plain radiography and routine intervertebral discs CT scan revealed no abnormalities (Figure 1A). The MRI study revealed a low-intensity mass surrounded by low-intensity change on T1-weighted images and a high-intensity mass surrounded by high-intensity change on T2-weighted images which involved the single vertebral body of L2 (Figure 1B and 1C). Cross-sectional CT scan of the involved lumbar vertebral body revealed a circumscribed osteolytic lesion with well-defined margins in L2 vertebra (Figure 1D). There was no residual fragment within the lesion and no paravertebral soft tissue extension around the affected vertebral body.

Physical examination revealed a well-nourished woman in no acute distress. The findings of the examination were unremarkable and there were no motor deficits or sensory changes. Laboratory studies showed an erythrocyte sedimentation rate of 19 mm/h. Therefore, the possibility of an inflammatory or local infectious process was entertained.

Surgical treatment was performed, using a left retroperitoneal approach. Following removal of the left cortical bone of the L2 vertebral body, a caseating soft tissue mass was found. This lesion was curetted and filled with cancellous bone chips from the left iliac crest. On pathologic examination, a necrotizing granulomatosis was seen. Material collected from operative curetting was cultured for the acid fast bacillus (A.F.B.) and positive cultures after 6-12 weeks incubation were seen. The diagnosis of tuberculosis was confirmed with these findings. For 6 months after the operation, the patient had received a daily antituberculous chemotherapy regimen of isoniazid (300mg), pyrazinamide (500mg), rifampin (300mg), and pyridoxine (50mg). Since 3 months postoperatively, she had been symptom free.

Case 2

A twenty-five-year-old woman, previously healthy, presented with pain in the lower back of 4 months' duration. There was no history of recent fever, rash, or weight loss. Local tenderness was present over the back of the sacrum and the spinous process of the fifth lumbar vertebra. Laboratory studies showed an erythrocyte sedimentation rate of 29 mm/h. Plain radiographs showed the normal architecture and arrangement of the lumbar spine. Computed tomographic scan of

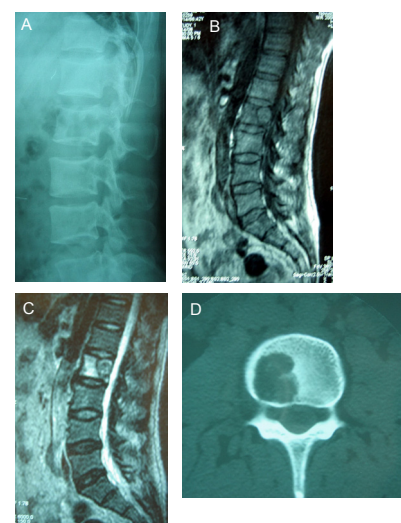


Figure 1: A 22-year-old man with a solitary osteolytic lesion occupied almost half of the L2 vertebral body.

- A. Lateral view of a plain lumbar spine radiograph showing normal architecture and vertebral body arrangement without bone destruction in the vertebrae and appendages. The heights of the intervertebral disc spaces are normal.
- B. T1-weighted sagittal MRI demonstrated a globular low intensity mass surrounded by low-intensity signal changes in the L2 vertebral body. The shape of the vertebral body kept normal, without compression or collapse.
- C. T2-weighted sagittal MRI showed a high intensity mass surrounded by high intensity changes in the residual vertebral body with a normal signal from the adjacent intervertebral discs.
- D. Cross-sectional imaging of the vertebral body by CT scan showing a local solitary circumscribed osteolytic lesion with well-defined margins in a single vertebral body without paravertebral soft tissue extensions.

***Corresponding author:** Ping Zhen, Department of Orthopedics, The General Hospital of PLA, Lanzhou, 333 Southern Binhe Road, Lanzhou 730050, Gansu Province, People's Republic of China, Tel: 0086-0931-8995287; Fax: 0086-0931-8995287; E-mail: zhenpingok@163.com

Received January 23, 2012; **Accepted** February 08, 2012; **Published** February 10, 2012

Citation: Zhen P, Li XS, Lu H (2012) Tuberculosis of a Single Lumbar Vertebra Presenting With a Solitary Local Osteolytic Lesion in Young Adults: A Report of Five Cases. J Spine 1:112. doi:10.4172/2165-7939.1000112

Copyright: © 2012 Zhen P, et al. This is an open-access article distributed under the terms of the Creative Commons Attribution License, which permits unrestricted use, distribution, and reproduction in any medium, provided the original author and source are credited.

the lumbar vertebra showed a well-defined, solitary local lytic lesion surrounded by a sclerotic ring edges at the level of the L5 vertebra (Figure 2A). MRI revealed a high-intensity mass surrounded by high-intensity change on T2-weighted images which involved the single vertebral body of L5 (Figure 2B). As the patient refused operation, a computed tomographic-guided fine-needle aspiration cytologic examination and concurrent core biopsy of the lesion were performed. Subsequent histological examination of the needle core biopsy material showed caseating granulomata. Gram stains for bacteria were negative, but acid-alcohol-fast bacilli were found in the specimen. A diagnosis of tuberculous abscess was made. Recovery of low back pain was rapid and complete, following appropriate antituberculous therapy.

Case 3

This thirty-eight-year-old man presented with a six-month history of dull back pain with radiating pain to the right hip. On physical examination no abnormal findings or neurological deficits were observed, laboratory studies showed an erythrocyte sedimentation rate of 15 mm/h. Radiographs of the spine were completely normal. CT scan showed a local lytic lesion with residual fragments of bone in the body of the 3rd lumbar vertebra (Figure 3A). On MRI, a hypointense signal was seen on the T1W images and hyperintense signal on T2W images in the L3 vertebral body with normal shape of vertebral body and intervertebral discs on either side (Figure 3B and 3C). Laminectomy was carried out, granulation tissue; pus and debris were found at the posterior part of vertebral body. Pedicle screws fixation was performed after the lesion was curetted and filled with cancellous bone chips from the right iliac crest (Figure 3D). Histopathology showed tubercular granuloma and AFB were found in it. Antituberculous therapy was started after operation. Postoperatively the patient's back pain resolved and she returned to normal daily life. The grafted iliac bone got bone healing at 3 months postoperatively (Figure 3E).

Case 4

A twenty-one-year-old woman first sought orthopedic consultation in December 2010 for dull back pain. CT scan and Magnetic resonance imaging demonstrated a small well-defined osteolytic lesion in L5 vertebral body (Figure 4A and 4B). CT-guided biopsy was carried out and revealed tuberculous granulation tissue with no acid fast bacilli. The

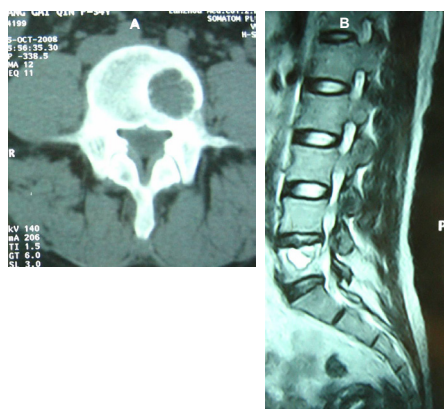


Figure 2: A 25-year-old woman with a solitary osteolytic lesion in the middle part of the L5 vertebral body.

A. CT demonstrated a solitary intraosseous lytic lesion in the middle part of the L3 vertebral body, with slight sclerotic margins around the lesion and without residual small bone fragments in the focal lesion.

B. T2-weighted sagittal MRI showed a small high intensity mass surrounded by a high intensity signal in the L3 vertebral body.

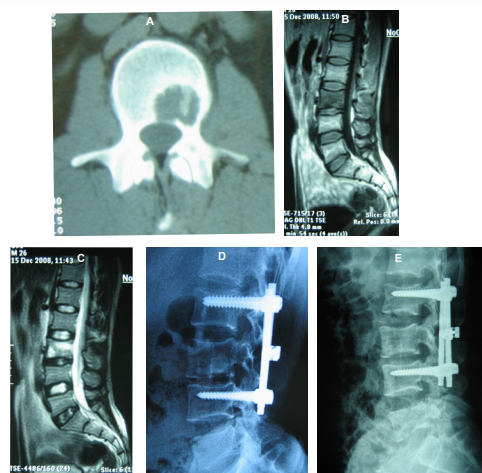


Figure 3: A 38-year-old man with a solitary osteolytic lesion in the posterior part of the L3 vertebral body.

A. CT scan showed a local lytic lesion with residual fragments of bone in the body of the 3rd lumbar vertebra.

B. MRI showed a hypointense signal with normal shape of vertebral body on the T1W images.

C. MRI showed hyperintense signal with normal signal of intervertebral discs on either side on the T2W images.

D. Pedicle screws fixation was performed after the lesion was curetted and filled with cancellous bone chips from the right iliac crest.

E. The grafted iliac bone got bone healing at 3 months postoperatively.

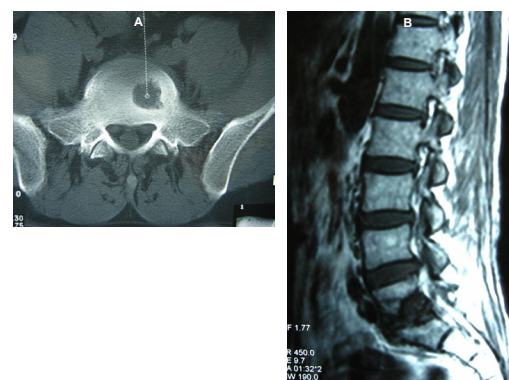


Figure 4: A 21-year-old woman with a small solitary osteolytic lesion in L5 vertebral body.

A. CT scan demonstrated a small well-defined osteolytic lesion in L5 vertebral body.

B. T1-weighted sagittal MRI demonstrated a globular low intensity mass in the L5 vertebral body.

culture taken from the fresh tissue grew *Mycobacterium tuberculosis*. Antituberculous therapy was started after operation. Postoperatively the patient's back pain resolved and she returned to normal daily life.

Case 5

A thirty-one-year-old man presented with a three-month history of backache. Straight leg raising was restricted on the right side and there was slight weakness of dorsiflexors of the right foot. Radiographs of the spine were completely normal. CT scan and MRI showed a lytic lesion in the posterior part of the L4 vertebral body (Figure 5A and 5B). The patient had undergone right L4 hemilaminectomy and curettage

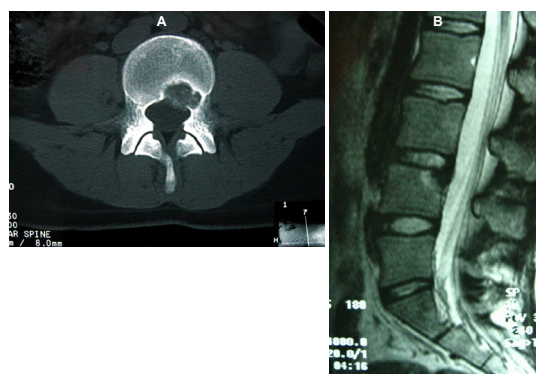


Figure 5: A 31-year-old man presented with a lytic lesion in the posterior part of the L4 vertebral body.

A. CT scan showed a small lytic lesion in the posterior part of the L4 vertebral body.

B. T2-weighted sagittal MRI showed a small low intensity mass surrounded by high intensity ring in posterior part of L4 vertebral body with a normal signal from the adjacent intervertebral discs.

of the lesion. Histopathology showed tubercular granuloma. AFB were found in and cultured from the biopsy specimen. Antitubercular chemotherapy was started postoperatively. Follow-up 6 months later showed complete resolution of symptoms and neurological deficits.

Discussion

The literature on single vertebra tuberculosis is so sparse that most involvements are misdiagnosed [1,9,10]. Solitary osteolytic lesions represent a unique form of single vertebra tuberculosis; therefore, radiological studies and clinical findings may not result in a definitive diagnosis for it [11,12].

Pathogenesis of single vertebral body tuberculosis

The origin of tuberculosis spondylitis is usually hematogenous rather than from involvement via a contiguous paraspinal site. The anterior-inferior aspect of the vertebral body is the initial site of infection. The route of infection is controversial [11]. The arterial route of transmission is recognized as more important [13], although some investigators favor Batson's valveless venous vertebral plexus for the spread of tuberculosis [14-17]. Tuli proposed that the central type of single vertebral body lesion arises as a result of infection reaching the vertebral body through Batson's venous plexus or branches of the posterior vertebral artery [5]. Although the involvement of a single vertebra in tuberculosis without involvement of the disc has been recognized [5-10,12,18,19], the mechanism by which the tubercle bacillus is deposited in a single vertebral body without the involvement of adjacent vertebrae and the intervertebral disc is unclear. The initial stage of spinal tuberculosis seems to be the most likely explanation [5,9]. Concentric collapse of the vertebral body or vertebra plana is the commonest form of single vertebra tuberculosis in the literature [1,5,10] and is easily confused with secondary deposits in the vertebral body [9]. In the cases of single vertebra tuberculosis described here, the presence of a solitary local lytic lesion within an isolated vertebral body without involvement of the intervertebral discs and paraspinal soft tissue could be due to weakness of the tubercle bacillus in the deposition process or a good immune response to the infection. However, it is difficult to explain why this unusual form of single vertebra tuberculosis only occurred in young adults and only involved the lumbar section, rather than affecting the anterior part of the vertebral body, where deposits are more common [19].

Clinical and radiographic characteristics

Most of the patients in our study were in their third or fourth decade of life. Because this small solitary osteolytic lesion started independently and was localized only to a single lumbar vertebral body, the patients presented with local back pain and tenderness but without clinical manifestations of typical spinal tuberculosis, such as obvious deformity, palpable paraspinal abscess, or constitutional symptoms of tuberculosis.

Plain radiography has limitations in assessing the small solitary osteolytic lesions in spine. Usually, foci less than 1 cm in diameter cannot be well demonstrated by plain radiographs since the elements are superimposed on the vertebral body [20]. Such shortcomings limit the accurate delineation of a local secluded lesion in a single vertebral body, and also may easily lead to a missed diagnosis.

Advanced imaging techniques such as CT or MRI are highly sensitive modalities for detecting secluded lesions in the spine and paravertebral soft tissue mass [21,22]. CT has been demonstrated to be much more sensitive than radiographs in evaluating bone destruction, appendage involvement, and soft tissue extension in spinal tuberculosis [20]. Nevertheless, a lumbar CT scan cannot easily find a small solitary osteolytic lesion in an isolated vertebral body in a clinical setting, because routine lumbar CT scans are usually performed to detect intervertebral disc diseases rather than the vertebral body, especially in the absence of obvious clinical manifestations and a precise definition of the location of the secluded lesion by plain film. In fact, MRI first detected this kind of solitary osteolytic lesion in three of our five cases, and CT detected two of them incidentally while imaging a suspected lumbar intervertebral disc herniation.

MRI is preferred to plain radiography, CT, and nuclear medicine studies in detecting abnormalities of the bone marrow and soft tissues because it is more sensitive [10,11,22]. Changes in both T1- and T2-weighted images are mainly due to the increased water content of the inflamed vertebrae and associated ischemic changes in bone marrow, resulting in early detection of the pathological process [9,23]. Meanwhile, MRI also has the capacity of multiplanar imaging and contemporary visualization of the secluded lesion in all elements of the spine [12,13]. MRI is useful for the evaluation of spinal tuberculosis because the signal intensity of the affected vertebral marrow is decreased on T1-weighted images and increased on T2-weighted images due to replacement of the normal fat content by edematous inflammatory involvement [12]. The solitary local lesions in our series of cases usually had a low-to-intermediate signal intensity on T1-weighted and low-to-intermediate signal intensity mass surrounded by high signal intensity margins on T2-weighted magnetic resonance images. The residual part of the vertebral body showed high-intensity changes on T2-weighted imaging.

The imaging presentation of single vertebra tuberculosis presenting with a solitary local osteolytic lesion has not been reported previously [1,2,6-9]. The typical image in our series of five cases was a small solitary "lytic" zone in an isolated lumbar vertebral body, approximately 0.5 to 1.8 cm in size, with clear margins from the encompassing minimal osteosclerotic reaction peripherally, accidental residual bone fragments within the lesion and rarely extending to the soft tissues. This presentation may represent the localized bone erosion from tuberculosis or tuberculous spondylitis in the initial stage. In adult cases of solitary osteolytic lesion in a single vertebral body, tuberculosis should be considered. CT combined with MRI is of great value for both diagnostic and therapeutic considerations in this rare occurrence in spinal tuberculosis.

Differential diagnosis

Single vertebra tuberculosis presenting with a solitary local osteolytic lesion is often confused with other single vertebra diseases that may have a similar imaging appearance, such as focal infection [23] and some secondary deposits in a single vertebral body [14], especially solitary bone cysts [24,25], osteoid osteomas [26], osteoblastomas [27], and eosinophilic granulomas [28].

Differentiating a localized spinal tuberculosis lesion from focal pyogenic spondylitis is usually difficult in the presence of isolated bone destruction on the basis of imaging findings alone [9,12,29]. Collapse of the vertebral body is rarely seen in pyogenic spinal infection but is common in spinal tuberculosis [30]. In the chronic stage, tubercular spondylitis shows a slightly hyperintense signal of the vertebral body on T1-weighted images, whereas non-tuberculous spondylitis shows low signal intensity [23]. On CT, well-defined margins around the local lytic lesion may provide valuable information for the diagnosis of tuberculosis rather than spinal focal infection.

A solitary bone cyst involving the spine is extremely rare, and only a few cases of histologically proven solitary bone cysts affecting the vertebral body have been reported [24]. A large osteolytic lesion surrounded by obvious bone sclerosis is the typical imaging finding [25], and may help to differentiate it.

Osteoid osteoma is a benign lesion, approximately 1 to 2 cm in size, with clear margins from the encompassing reactive bone. About 10-20% of all osteoid osteomas are found in the spine. The posterior elements are most commonly affected, such as the perpendicular region of the arch, pedicle, lamina, or transverse process, and less than 10% of spinal osteoid osteomas affect the vertebral body. The nidus of the tumor may not be visible on routine studies, but a CT scan is usually able to detect central nidus calcification [26].

Osteoblastoma is another benign tumor of bone; it is histologically identical to an osteoid osteoma but is several centimeters larger [27]. This expanding osteolytic lesion may affect not only the lamina and transverse processes but also the adjacent rib. Spinal osteoblastomas are typically expansile with a scalloped or lobulated contour, well-defined margins, and possibly a sclerotic rim.

In children, eosinophilic granuloma mainly involves the vertebral bodies and can present with solitary vertebral body involvement. Posterior element involvement is less common. Involvement of the vertebral body may result in anterior wedging or near collapse with a characteristic “vertebra plana” appearance. However, the involvement of eosinophilic granuloma in the adult lumbar spine is very rare, and only a few cases have been reported in the English-language literature [28]. MRI revealed an isointense mass surrounded by a low-intensity change on T1-weighted images and a high-intensity mass surrounded by high-intensity change on T2-weighted images.

Conclusions

A local solitary osteolytic lesion in a single vertebral body is rare form in spinal tuberculosis. Diagnosis is often delayed because local osteolytic lesions are not usually evident on plain radiographs and conventional lumbar intervertebral disc CT. When a vertebral column lesion is suspected, CT scan of the cross-vertebral body followed by MRI is very helpful for precisely defining the location of the secluded lesion and extent of osseous involvement. Evaluating a solitary local osteolytic lesion in a single vertebra can be a perplexing task; however, a distinct diagnosis may be achieved by CT-guided biopsy or surgical intervention.

References

1. Naim-ur-Rahman (1980) Atypical forms of spinal tuberculosis. *J Bone Joint Surg Br* 62: 162-5.
2. Tuli SM (2002) General principles of osteoarticular tuberculosis. *Clin Orthop Relat Res* : 11-19.
3. Griffith JF, Kumta SM, Leung PC, Cheng JC, Chow LT, et al. (2002) Imaging of musculoskeletal tuberculosis: a new look at an old disease. *Clin Orthop Relat Res* : 32-39.
4. Watts HG, Lifeso RM (1996) Tuberculosis of bones and joints. *J Bone Joint Surg Am* 78: 288-298.
5. Pande KC, Babhulkar SS (2002) Atypical spinal tuberculosis. *Clin Orthop Relat Res* 67-74.
6. Yalniz E, Pekindil G, Aktas S (2000) Atypical tuberculosis of the spine. *Yonsei Med J* 41: 657-661.
7. Babhulkar SS, Tayade WB, Babhulkar SK (1984) Atypical spinal tuberculosis. *J Bone Joint Surg Br* 66: 239-242.
8. Pande KC, Pande SK, Babhulkar SS (1996) An atypical presentation of tuberculosis of the spine. *Spinal Cord* 34: 716-719.
9. Lolge S, Maheshwari M, Shah J, Patkar D, Chawla A (2003) Isolated solitary vertebral body tuberculosis—study of seven cases. *Clin Radiol* 58: 545-550.
10. Ousehal A, Adil A, Abdelouafi A, Kadiri R (2000) Centrosomatic spinal tuberculosis: radiographic features in 10 cases. *J Neuroradiol* 27: 247-252.
11. Ahmadi J, Bajaj A, Destian S, Segall HD, Zee CS (1993) Spinal tuberculosis: atypical observations at MR imaging. *Radiology* 189: 489-493.
12. Smith AS, Weinstein MA, Mizushima A, Coughlin B, Hayden SP, et al. (1989) MR imaging characteristics of tuberculous spondylitis vs vertebral osteomyelitis. *AJR Am J Roentgenol* 153: 399-405.
13. Gouliamos AD, Kehagias DT, Lahanis S, Athanassopoulou AA, Mouloupoulou ES, et al. (2001) MR imaging of tuberculous vertebral osteomyelitis: pictorial review. *Eur Radiol* 11: 575-579.
14. Batson OV (1940) The function of the vertebral veins and their role in the spread of metastases. *Ann Surg* 112: 138-149.
15. Batson OV (1957) The Vertebral Vein System. Caldwell Lecture, 1956. *Am J Roentgenol Radium Ther Nucl Med* 78: 195-212.
16. Weaver P, Lifeso RM (1984) The radiological diagnosis of tuberculosis of the adult spine. *Skeletal Radiol* 12: 178-186.
17. Desai SS (1994) Early diagnosis of spinal tuberculosis by MRI. *J Bone Joint Surg Br* 76: 863-869.
18. Naim-Ur-Rahman, Al-Arabi KM, Khan FA (1987) Atypical forms of spinal tuberculosis. *Acta Neurochir (Wien)* 88: 26-33.
19. Algra PR, Heimans JJ, Valk J, Nauta JJ, Lachniet M, et al. (1992) Do metastases in vertebrae begin in the body or the pedicles? Imaging study in 45 patients. *AJR Am J Roentgenol* 158: 1275-1279.
20. Jain R, Sawhney S, Berry M (1993) Computed tomography of vertebral tuberculosis: patterns of bone destruction. *Clin Radiol* 47: 196-199.
21. Gupta RK, Agarwal P, Rastogi H, Kumar S, Phadke RV, et al. (1996) Problems in distinguishing spinal tuberculosis from neoplasia on MRI. *Neuroradiology* 38 Suppl 1: S97-104.
22. Danchaivijitr N, Temram S, Thepmongkhol K, Chiewvit P (2007) Diagnostic accuracy of MR imaging in tuberculous spondylitis. *J Med Assoc Thai* 90: 1581-1589.
23. Maiuri F, Iaconetta G, Gallicchio B, Manto A, Briganti F (1997) Spondylodiscitis. Clinical and magnetic resonance diagnosis. *Spine (Phila Pa 1976)* 22: 1741-1746.
24. Fujimoto T, Nakamura T, Ikeda T, Koyanagi E, Takagi K (2002) Solitary bone cyst in L-2. Case illustration. *J Neurosurg* 97: 151.
25. Matsumoto K, Fujii S, Mochizuki T, Hukuda S (1990) Solitary bone cyst of a lumbar vertebra. A case report and review of literature. *Spine (Phila Pa 1976)* 15: 605-607.
26. Caldicott WJ (1969) Diagnosis of spinal osteoid osteoma. *Radiology* 92: 1192-1195.

-
27. Saifuddin A, White J, Sherazi Z, Shaikh MI, Natali C, et al. (1998) Osteoid osteoma and osteoblastoma of the spine. Factors associated with the presence of scoliosis. Spine (Phila Pa 1976) 23: 47-53.
 28. Nakamura H, Nagayama R (2008) Eosinophilic granuloma presenting with local osteolysis in an adult lumbar spine. J Clin Neurosci 15: 1398-1400.
 29. Sharif HS (1992) Role of MR imaging in the management of spinal infections. AJR Am J Roentgenol 158: 1333-1345.
 30. Maiuri F, Iaconetta G, Gallicchio B, Manto A, Briganti F (1997) Spondylodiscitis. Clinical and magnetic resonance diagnosis. Spine (Phila Pa 1976) 22: 1741-1746.