

Trichoscopy of Hair Shaft: White Nodules

Ana Maria Costa Pinheiro^{1,2}, Eduardo Botelho Silva Mauad², Luis Fernando Amarante Fernandes^{2*} and Gustavo Henrique Soares Takano^{2,3}

¹Department of Dermatology, University of Brasília, Brazil

²Department of Medicine, University of Brasília, Brazil

³Department of Pathological Anatomy, University of Brasília, Brazil

Abstract

Trichoscopy is a tool each time more used in the diagnosis of hair disorders. We describe two cases of white nodules on the hair shaft, their findings under microscopy and trichoscopy. The diagnosis of these hair shaft abnormalities is usually done by microscopy or electron microscopy of the affected hair; but trichoscopy was an easy, rapid, comfortable and useful method in the differential diagnosis of these conditions.

Keywords: Trichoscopy; Hair shaft; Pili annulati; Trichorrhexis nodosa

Introduction

Trichoscopy, that corresponds to scalp and hair dermoscopy, is a tool each time more used in the diagnosis of capillary abnormalities and even considered by some authors as an indispensable tool in the differential diagnosis of hair and scalp diseases [1]. It represents a valuable noninvasive and low-cost method, still underutilized, which uses video dermoscopy of hair and scalp at higher magnifications (20-160) [2], and that has been increasingly used as an aid in the diagnosis, follow-up and prognosis of hair disorders [3].

Trichoscopy can be used in the diagnosis of congenital diseases and acquired diseases, for example, in the diagnoses of hair shaft abnormalities. Hair shaft abnormalities encompass a group of congenital (genetic abnormality) and acquired (external injury) alterations which involve the hair shaft [4] trichoschisis, tricorrhexis invaginata, pili annulati, trichoptilosis, trichonodosis, pili torti, pili bifurcate, trichoschisis, trichoclasia, trichorrhexis nodosa and others. Among the hair shaft abnormalities, some appear as white nodules on scalp hair. We describe two cases of patients with white nodules in the hair shaft.

Case Synopsis

Case 1

A 50-year-old female patient with white nodules in her hair since childhood. Report of a sister with the same manifestation; this sister could not be examined. Microscopy of hairs showed a random pattern of intermittent abnormal cavities (Figures 1A and 1B). Trichoscopy demonstrated hair shafts with regular light bands (Figure 1C). Light bands observed by clinical examination and trichoscopy appeared as dark bands when imaged by light microscopy, reflecting cortical spacers containing air in the light bands and fluid in the dark bands. These findings established the diagnosis of pili annulati.

Case 2

A 37-year-old male patient with white nodules on three scalp areas 2 years ago. Deny associated symptoms. Personal history of seborrheic dermatitis using anti-dandruff shampoo. Microscopy and trichoscopy showed a brush-like image (Figures 2A-2C), allowing the diagnosis of trichorrhexis nodosa.

Case Discussion

White nodules can be present in several acquired or congenital diseases, such as white piedra, nits of pediculosis, hair cast, trichorrhexis nodosa, monilethrix and others. The diagnosis of these hair shaft abnormalities is usually done by microscopy [4] or electron microscopy

of the affected hair, but can also be done by trichoscopy [5]; wherein each of these methods has its merits and demerits [6]. Besides being a rapid, easy and more comfortable for the patient- there is not the need to tear or cut the hair for diagnostic procedures, a study published in 2008 by Rakowska demonstrated that trichoscopy gives results comparable to a microscopic examination and concluded that in all the hair shaft abnormalities, except for trichodistrofia, the diagnosis can be made based solely on trichoscopy directly in the dermatologist's office, reinforcing it as an important tool in practice dermatologist and clinical diagnosis of hair diseases [4].

Pili annulati (PA) is a rare variable of capillary stem, in which the hair has a spotted and shiny appearance, with a characteristic alternation between light and dark bands along the hair shaft. The other characteristics of the hair are maintained-growth and tensile strength, for example - and, thus, the AP is classified as a change of capillary stem without fragility. The scalp is the most frequently affected region, but other regions can also be affected [5].

Diagnostic suspicion can be raised especially if there is a positive family history associated with the characteristic clinical presentation [7]. The diagnosis is usually established by the microscopy of the affected hair. Under microscopy, the hairs of PA patients show a random pattern of intermittent abnormalities. The light bands observed at the clinical examination, when under light microscopy, appear as dark bands, reflecting cortical spaces containing air [4]. This pattern, and especially the presence of air, is the basis for some of the mechanisms proposed to explain its pathogenesis, where there would be an underlying cyto keratin abnormality, a matrix formation defect or a defect of a regulatory protein, affecting structural proteins in the extracellular matrix. Trichoscopy in patients with AP shows hair with regular light bands, corresponding to the same air cavities that appear dark on microscopic examination [8].

Trichorrhexis nodosa (TN) is a hair shaft anomaly, often presented by an intermittent whitish swelling nodes of hair fibers and splitting of tips. Its primary cause is trauma, although many hereditary syndromes can predispose to weakness of the hair [9,10]. Despite most commonly observed in scalp hair, it can affect other areas such as body and genito

*Corresponding author: Luis Fernando Amarante Fernandes, Department of Medicine, University of Brasília, Brazil, Tel: 5561982715481; E-mail: lfamarante@gmail.com

Received June 07, 2017; Accepted June 26, 2017; Published June 29, 2017

Citation: Pinheiro AMC, Mauad EBS, Fernandes LFA, Takano GHS (2017) Trichoscopy of Hair Shaft: White Nodules. J Clin Case Rep 7: 981. doi: 10.4172/2165-7920.1000981

Copyright: © 2017 Pinheiro AMC, et al. This is an open-access article distributed under the terms of the Creative Commons Attribution License, which permits unrestricted use, distribution, and reproduction in any medium, provided the original author and source are credited.

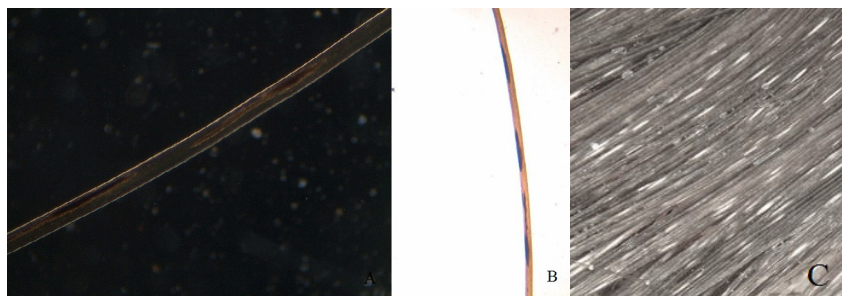


Figure 1: Pili annulati: (a) Microscopic examination (b) Microscopic examination (c) Trichoscopy showing hair shafts with alternative light and dark bands.




Figure 2: Trichorrhexis nodosa: (a) Microscopic examination (b) Microscopic examination (c) Trichoscopy.

inguinal hair. Clinically, the hair appears dry and brittle with signs of fragility and with a tendency to break at different lengths. Trichoscopy may show nodular thickenings along hair shafts at low magnifications. The hairs bend with a rounded edge at the level of the nodes. When broken at the level of the nodule, it is seen a thickened, rounded hair shaft end-that can appear darker than the light-colored hair, or lighter in case of darker hair. Using higher magnifications, numerous small fibers can be noticed, resembling two brushes aligned in opposition in consequence of the broken cortex. Diagnosis is based on the clinical presentation and changes are observed on light microscopy and scanning-electron microscopy [10,11].

Conclusion

We describe two cases of white nodules on the hair shaft- pili annulati and trichorrhexis nodosa, their findings under microscopy and trichoscopy. These results show that the trichoscopy is as effective as microscopy in the diagnosis of these conditions and an important tool for the diagnosis of hair disorders.

References

1. Rudnicka L, Olszewska M, Rakowska A, Slowinska M (2011) Trichoscopy update case report. J Dermatol Case Rep 5: 82-88.
2. Bhamla SA, Dhurat RS, Saraogi PP (2013) Is trichoscopy a reliable tool to diagnose early female pattern hair-loss?. Int J Trichology 5: 121-125.
3. Pedrosa AF, Morais P, Lisboa C, Azevedo F (2013) The Importance of trichoscopy in clinical practice. Dermatol Res and Prat 986970.
4. Rakowska A, Slowinska M, Kowalska-Oledzka E, Rudnicka L (2008) Trichoscopy in genetic hair shaft abnormalities. J Dermatol Case Rep 2: 14-20.
5. Akoglu G, Emre S, Metin A, Erbil KM, Akpolat D, et al. (2012) Pili annulati with fragility: Electron microscopic findings of a case. Int J Trichology 4: 89-92.
6. Dhurat R, Saraogi P (2009) Hair evaluation methods: Merits and Demerits. Int J Trichology 1: 108-119.
7. Berk DR, Bayliss SJ, Giehl KA (2013) Pili annulati: A report of 2 American families. Cuti. 91: 254-257.
8. Wallace MP, De Berker DA (2010) Hair diagnoses and signs: The use of dermatoscopy. Clin Exp Dermatol 35: 41-46.
9. Forsiind B, Andersson MK, Alsterborg E (1991) Hereditary hair changes revealed by analysis of single hair fibers by scanning electron microscopy. Scanning Microsc 5: 867-874.
10. Schwartz RA (2017) Trichorrhexis Nodosa.
11. Rudnicka L, Olszewska M, Rakowska A (2012) Atlas of Trichoscopy: Dermoscopy in hair and scalp disease. Springer, London, UK 159-160.