

## Treatment of Bone Defects in War Wounds Retrospective Study

Predrag Grubor<sup>1\*</sup>, Milan Grubor<sup>1</sup> and Luigi Meccariello<sup>2</sup>

<sup>1</sup>Clinic of Traumatology, University Hospital Clinical Center Banja Luka, Bosnia and Herzegovina

<sup>2</sup>Department of Medical and Surgical Sciences and Neuroscience, Section of Orthopedics and Traumatology, University of Siena, University Hospital "Santa Maria alle Scotte", Siena, Italy

### Abstract

**Introduction:** Results of the treatment of open fractures primarily depend on the treatment of connected soft tissue injuries.

**Objective:** The aim was to present the experience and methods gained during the treatment of diaphyseal bone defects as a consequence of gunshot fractures of war trauma.

**Patients and Methods:** The study consisted of 116 patients with the diaphyseal bone defect who were treated with the usage of primary and delayed autotransplantation of bones, transplants of the fibula and Ilizarov distraction osteogenesis. The results of compensation of bone defect less than 4 cm and conducted by an early cortico-spongioplastics were as follows: good in 8 respondents (45%), satisfactory in 6 (34%) and poor in 4 respondents (21%). In cases of delayed cortico-spongioplastics, the abovementioned results were: good in 36 (41%) respondents, satisfactory in 24 (34%) and poor in 16 (25%) respondents. The results of compensation of bone defect greater than 4 cm with the usage of fibular transplant were as follows: good in 3 (38%) respondents, satisfactory in 3 (38%) and poor in 2 (24%), and with the usage of using the Ilizarov method, the results were as follows: good in 8 (57%) respondents, satisfactory in 3 (21.5%) and poor in 3 (21.5%) respondents.

**Conclusion:** The results showed that, in cases of compensation of bone defects less than 4 cm, the advantage is given to the primary spongioplastics over the delayed one. In cases of compensation of bone defects greater than 4 cm, the advantage is given to the Ilizarov distraction osteogenesis when compared to the fibular transplant. War wounds caused by firearms; characterize the extensive destruction of tissues, organs and the primary contamination polymorphic bacterial flora. Upon receipt of the injured we have not been in position to take from contributory a swab from the wounds of war, to identify the primary causes of infection and prescribe targeted, obtained by the antibiotic, antibiotic therapy. This is due to the material and technical conditions. We are a small country, where there is no industry for the production of medical equipment, disposable medical supplies, antibiotics. We were dependent on the humanitarian organizations and the not specially organized industry, we organized the production of external fixator because it was easiest.

**Keywords:** Open fractures; Diaphyseal bone; Gunshot fractures; Fibular transplant; Antibiotics

### Introduction

War wounds caused by firearms, represent damage to the body, whose features are extensive destruction of the tissue, primary contamination with polymorphic bacterial flora and altered reactivity of the organism [1].

War trauma injuries are usually injuries to the extremities (about 70%), out of which about 40% is accompanied with comminuted fracture [1]. They occur due to the force of projectiles from firearms or a piece of grenade, land mines or other explosive devices [1]. The treatment of gunshot fractures of the extremities is never conducted simultaneously. It is most frequently conducted in two continuous phases.

In the first phase, not later than 8 hours after the injury, primary treatment of a gunshot wound is conducted. This is the most important surgical operation, after which the gunshot wound should be "sterile" [1,2]. The stabilization of broken bones is about 90% stabilized with an external fixator and delayed primarily closure of the wound [3].

In the second phase, usually 7-10 days after the primary treatment, the war gunshot wound is definitely closed or covered [3]. The amount of extinct bone fragments is influenced by: damage to blood vessels of periosteum and endostatin and the number of dead osteocytes on the fragments of broken bones. In post war period trauma, osteocytes withering in the diaphyseal section is about 1-2 mm, while in metaphyseal section is about 2-5 mm from the fracture [4].

Defects in gunshot fractures occur as a consequence of the removal of free bone fragments and resection of devitalized bone fragments in the primary or secondary surgical treatment. In the time of the bone tissue processing, it is difficult to estimate the vitality of fragments, as there are no specific indicators for intraoperative assessment of the bone vitality [4]. The most common indicators are: bleeding from the exposed ends of the bones, a state of periosteal of bone fragments and the size of bone fragments.

After infections, the most serious complications of gunshot injuries of extremities are pseudarthrosis and bone defects whose treatment represents a complex problem in reconstructive surgery. When it comes to the choice of methods for treating these complications, there is no unanimous attitude [2-4]. The methods of treatment are:

- Osteoplasty with a cast or external fixator immobilization,

**\*Corresponding author:** Predrag Grubor, Clinic of Traumatology, University Hospital Clinical Center Banja Luka, Bosnia and Herzegovina, Tel: +38765513115; E-mail: [predraggrubor@gmail.com](mailto:predraggrubor@gmail.com)

Received August 05, 2015; Accepted April 28, 2016; Published April 30, 2016

**Citation:** Grubor P, Grubor M, Meccariello L (2016) Treatment of Bone Defects in War Wounds Retrospective Study. J Trauma Treat 5: 302. doi:10.4172/2167-1222.1000302

**Copyright:** © 2016 Grubor P, et al. This is an open-access article distributed under the terms of the Creative Commons Attribution License, which permits unrestricted use, distribution, and reproduction in any medium, provided the original author and source are credited.

- Osteoplasty and AO plate osteosynthesis
- Corticotomy and distraction osteogenesis according to Ilizarov

Grafts and hemotransplants from the bone bank are most commonly used for compensation of bone defects. Specialized institutions compensate the bone defect with vascularized grafts, fibula, ribs, radius, iliac, etc [5].

## Objective

The aim was to present the experience and methods gained during the treatment of diaphyseal bone defect as a consequence of gunshot fractures of war trauma. Furthermore, to identify the advantages of one method over another in the treatment of bone defects.

## Patients and Methods

The study was retrospective.

2,462 wounded with injuries of the musculoskeletal system were primarily taken care of at the Clinic of Orthopaedic and Traumatology in Banja Luka in the period from 1991-1995. After the primary treatment of the war wound, external fixator was used in 1573 (64%) patients.

116 patients with the bone defect were treated at the same time. In order to compensate the bone defect, we used a bone graft and method of bilocal synchronous Ilizarov apparatus for compressive-distraction osteosynthesis. We could not use the bone homotransplants because we did not have the so-called "Bone bank". We also did not use vascularized grafts because we did not have qualified professional team capable of using the abovementioned method. The diagnosis was set on the basis of preoperative radiographic and intraoperative findings during the primary treatment of gunshot fractures. The size of the bone defect was conditioned by the choice of donor sites. The appearance of the wound, swab taken on the eighth day and laboratory findings: erythrocyte sedimentation rate, complete blood count and leukocyte count were the parameters for the assessment of the presence of infection and decision regarding the day of surgical intervention.

The order of work in primary spongioplasty was the following: cleaning and garnishing the operational field of the bone defect and donor sites. Preparation of the spongioplasty anchorage was done as follows: wound was staged, skin firm and rinsed with up to 8 litres of saline. Wet gauze was placed in the prepared anchorage with a healthy granulation tissue. The gauze was previously soaked in the saline. After that, the prepared place for the autotransplant was covered with dry gauze. Spongious graft up to 1 cm<sup>3</sup>, that is, cortico-spongious bone according to Phemister, was taken from the selected donor site which was determined by the size of the bone defect [6].

By applying this method, osteocytes from the grafts were the least exposed to weather and other non-physiological conditions, which may accelerate osteocytes withering from the graft. The bone defect was filled with a sufficient amount of bone grafts and the wound was closed in layers. The bone graft was covered with well vascularized muscle tissue. In cases when the coverage by muscles was not technically feasible, healthy skin was used. Upon the completion of graftation, the donor's site was closed in layers, along with the wound drainage.

On the first postoperative day, a physical therapy and static exercises of the operated limb were done in bed. On the third postoperative day, the patients began to walk with the help of crutches under their armpits, depending on the stability and size of the bone defect. The decision to walk without support, with a touch support or support from 5-10 kg was

made on the basis of the size of the defect and the stability of the bone fragments. On the average, the patients were sent to home treatment on the 10th day. Initial controlling radiography was conducted 6 weeks later. Most frequently, the patient or family member (educated at the clinic by the physiotherapist), did kinesiotherapy or hydrotherapy at home.

Clinical examinations were carried out every 15 days. The clinical examination monitored the dynamics of the repair of soft tissue and gave an insight into required maintenance around the pins of external fixators.

Radiographic control conducted every 30 days enabled the evaluation of the fracture rehabilitation, assessment of the load degree and the establishment of a full functional use of the extremities. The evaluation of final results was conducted in relation to major complications: nonunion, infection, neurovascular and functional results (Table 1).

Early autogenous spongioplasty (primary spongioplasty) was performed for the first time in 1994. It was performed in 18 males with the bone defects that occurred due to projectiles or shrapnel of high initial velocity. The average age was 29.77 (from 19-42) years. The primary surgical treatment was performed, on the average, 5.53 hours after the wounding. The average size of the bone defect, formed after the wounding and primary surgical treatment of the war wound was 2.01 (4 cm -1 cm) cm. Compensation of bone defect was made 12.22 days after the surgical treatment of the war wound. Earliest compensation of the bone defect was done on the 7th day and not later than 15 days after the primary surgical treatment. The average number of surgeries was 2.2 and the treatment duration was 13.3 months (4-18 months). The external fixator was a final solution in 14 cases, while in 4 cases, re-osteoplastic and AO plates were used. In 5 patients, out of 18, primary graft was taken from both iliac crests. Early spongioplasty was conducted on the femur in 7 patients, on the humerus in 3, on the tibia in 3, on the radius in 4, and on the ulna in 3 patients. Complications of primary spongioplasty of war wounds were manifested as follows: pseudoarthrosis in 4 patients, transient infections around the pins in 12, joint contractures in 3, and the lower limb-length discrepancy of 2.5 cm in 2 patients. Neurovascular outbreaks did not occur (Table 2).

76 patients, that is, 72 (95%) males and 4 (5%) females, average age 31.79 (19-58) years, were included in the clinical research of diaphyseal gunshot fractures that had been treated, at the stage of secondary surgery, with AO plate osteosynthesis and the delayed Phemister's spongioplastics. After the primary surgical treatment of the war wound, in 60 (79%) patients the abovementioned fractures were stabilized with the external fixator and in 16 (21%) patients with the plaster splint. The area affected by fractures of the bones was as follows: femur in 28 (37%) patients, humerus in 19 (25%), tibia in 9 (12%), both forearm bones in 4 (5%), radius in 11 (14%) and ulna in 5 (7%) patients. The average bone defect was 1.5 cm (0.5 cm-4 cm).

All patients underwent the first phase of treatment:

RESULTS	GOOD	SATISFACTORY	POOR
nonunion	No	No	Yes
osteomyelitis	No	No	Yes
neurovascular disturbance	No	moderate	severe
joint mobility	Normal	to 70%	under 70%
limb-length discrepancy	No	to 3 cm	over 3 cm

Table 1: Criteria for the result assessment of the Phemister's spongioplasty.

**Functional results of primary Phemister's spongionasty in treatment of 18 patients**

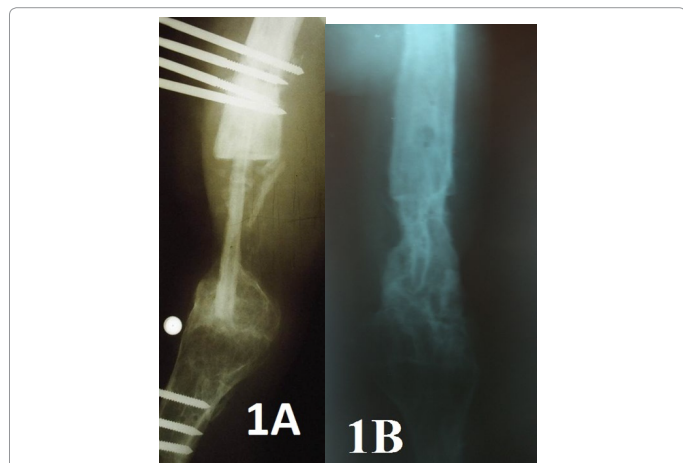
BONE	GOOD	FAIR	POOR	TOTAL
Femur	4 (57%)	2 (29%)	1 (14%)	7
Tibia	1 (34%)	1 (33%)	1 (33%)	3
Humerus	2 (66%)	1 (34%)		3
Radius	1 (50%)	1 (25%)	1 (25%)	3
Ulna		1 (50%)	1 (50%)	2
Total	8 (45%)	6 (34%)	4 (21%)	18

**Table 2:** Results of primary spongionasty of war wounds.

**Functional results of Osteosynthesis and AO plate and Phemister's spongionasty in treatment of 76 patients**

BONE	GOOD	SATISFACTORY	POOR/LOŠ	TOTAL
Femur	16 (57%)	8 (28%)	4 (15%)	28
Tibia	2 (18%)	4 (44%)	3 (34%)	9
Humerus	12 (63%)	6 (32%)	1 (5%)	19
Radius	7 (64%)	3 (27%)	1 (9%)	11
Ulna	1 (20%)	2 (40%)	2 (40%)	5
Both bones	1 (25%)	1 (25%)	2 (50%)	4
Total	36 (41%)	24 (34%)	16 (25%)	76

**Table 3:** Functional results of osteosynthesis and AO plate and Phemister' spongionasty.



**Figure 1:** 1A) Femur defect recovered by the fibular graft. 1B) Result after 17 years.

**Functional results of bone defects treated with fibular graft-8 patients**

BONE	GOOD	FAIR	POOR	TOTAL
Femur	2 (40%)	2 (40%)	1 (20%)	5
Humerus	1 (50%)	1 (50%)		2
Ulna			1 (100%)	1
Total	3 (38%)	3 (38%)	2 (24%)	8

**Table 4:** Functional results of bone defects treated with fibular graft-8 patients.

- The wound was closed or covered with high-quality skin,
- Fracture rehabilitation did not occur, nor there were any chances for healing,
- There was a bone defect to 4 cm in length,
- Clinical or laboratory signs of infection were not manifested.

After the primary treatment, the war wounds of long bones fragments were stabilized with the external fixators to keep the length of the limbs, quick mobility and proper repair of the soft tissue. There were cases when the intraoperative findings suggested that a proper rehabilitation of the bone would be achieved, but clinical and

radiographic findings after 3.6 months on the average (2.1-5.8 months) renounced it.

Upon the removal of the external fixator, preoperative preparation for surgical treatment was conducted. Normal general and local examination was usually conducted on the 10th day, after which the secondary surgery compensation of the bone defect was performed using the Phemister's spongionastics and AO osteosynthesis plate. The average number of surgeries was 3.6 and treatment duration was 32.5 months (9.33-48.83 months). The assessment of the final results was carried out in relation to major complications: nonunion, infection, neurovascular and functional results (Table 1).

The fracture healing was achieved in 67 (88%) patients and in 9 (12%) patients a rehabilitation did not occur (Table 3). The latter was managed with re-osteosynthesis. Re-osteosynthesis and re-osteoplastic were conducted in 3 femur bones, 3 tibia bones, 2 ulna bones and 1 humerus bone.

Fibular graft has established itself to be very successful in the treatment of bone defects higher than 5 cm. (Figure 1). Averagely, the fibula is 30 cm long 3 cm in diameter, and hence is very suitable for large forearms bone defects. In humerus, femur and tibia defects, it can be placed in the medullary canal as well.

Gilbert's modification of the original Taylor's posterior approach is the most suitable method to apply when taking the fibular graft [7]. It is approached through the cleavage between the perineal muscles and m. soleus. The m. soleus fibers are separated from the fibula and proximal and distal osteotomy of the fibula is done in necessary line segment of the defect. One cortical screw is placed three centimeters above the ankle joint in order to stabilize the distal part of the fibula and tibia. The screw is used to restore the ankle joint stability that had previously been provided by the fibula. The obtained fibular autotransplant of appropriate length is placed on the previously prepared long bone bearing.

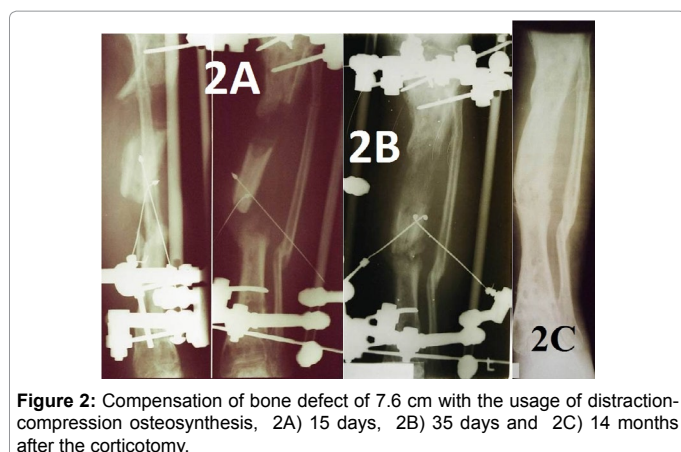
8 patients, 7 males and 1 female, average age 29.97 (19-45) years were included in the clinical research of diaphyseal gunshot fractures which had been treated, at the stage of secondary surgery, with fibular graft. After the primary surgical treatment of the war wound, the abovementioned fractures were stabilized with the external fixator. The area affected by fractures of the bones was as follows: femur in 5 patients, humerus in 2 and ulna in 1 patient. The average bone defect was 6.2 cm (5-9.6 cm). The average follow-up was 22.5 months (9.33-38.32 months). The assessment of the final results was carried out in relation to major complications (Table 1).

The fracture healing was achieved in 6 patients while in 2 patients the rehabilitation of the bone did not occur. The fibular graft ingrowth was not achieved in 2 patients treated for bone defects in the ulna and humerus. Functional results of bone defects treated with fibular graft are shown in (Table 4).

Compensation of the tibia bone defect in 14 patients, that is, 12 (86%) males and 2 (14%) females, average age 30 years (22-42 years), was performed using the Ilizarov technique of extension of one of the fragments in order to reconstruct the tibia bone defect. The average length of the tibia defect was 5.6 cm (3.5-8.5 cm). The tibia defects were accompanied with various neurological and vascular damage and injuries of tendons and muscles of the lower leg. All patients had a flexion-extension contracture of the knee and/or ankle joint equinus, as well as the significant soft tissue defect due to the initial injury or debridement.

Averagely, the rehabilitation was 10 months long (4-17 months).





In 10 patients, the average bone defect was 4.7 cm (3.5-6.0 cm), with interfragmentary diastasis of 1.5 cm (1-2.5 cm) and anatomical discrepancy of 3.1 cm (2.0-5.0 cm).

The method of bilocal synchronous compressive-distraction osteosynthesis with the Ilizarov fixator was used to recover these bone defects. It involved simultaneous immediate compression to the contact of the fragments in the area of the defect, with the goal of healing and gradual distraction in the zone of osteotomy of one of the fragments in order to form the bone regenerates of the required length.

In 4 patients with the average length of the defect of 6.4 cm (4.0-8.5 cm) and interfragmentary diastasis of 5.5 cm (4.5-7.5 cm) and anatomical discrepancy of 1.6 cm (1-2 cm), the bilocal alternating compressive-distraction osteosynthesis was used. It involved gradual, graded distraction of the removed part of one of the fragments of the bone to its contact with the opposite lying fragment, along with simultaneous formation of the bone regenerates of the required length (Figure 2).

In 13 patients, the osteotomy was performed in the proximal and in 1 patient in the distal fragment of the tibia. Radiographic evaluation was performed every 2 weeks during the distraction phase and every 4 weeks during the consolidation phase.

We evaluated the results of treatment according to the classification of the Association for the Study and Application of the Ilizarov Method, graded as: excellent, good, fair and poor [8].

Monitoring of the patients lasted about 32 months (18-48 months). During the treatment, the mean distraction index value was 10.6 (10-11), maturation index was 39.8 (36-45), and external fixation index was 52.5 (49-57.4). The average duration of wearing the external fixator was 8.5 months (from 6.0-12.0 months). The healing of points of contact of the fragments was registered in 11 patients. In 3 patients, there was no healing (pseudoarthrosis was formed) and they underwent the additional surgical treatment, which involved the application of the Ilizarov apparatus for the compression osteosynthesis along with opening and processing of the contact. Upon this surgical intervention, the healing occurred at the point of contact, with extended treatment duration. The average healing of the points of contact of the fragments was 4.6 months (4-5 months). In 3 patients, angular deformity of the tibia of 10° was established. Postoperative leg length discrepancy did not occur in 3 patients, while 8 patients had the average discrepancy of 1.6 cm (1-3 cm). Subsequent surgical correction of the shin length was recommended to 3 patients with the discrepancy of 3 cm, and they rejected it.

On the last medical check-up, we found an infection in 2 patients. In 9 patients, "bone result" was excellent, while it was good in 5 patients. Significant postoperative limping occurred in 6 patients, 4 of them had fixed contractures of the knee and ankle, and 2 of them had atrophy of the shin muscles of mild degree. 8 patients did not complain of pain, while 5 patients reported moderate pain, and only 1 patient suffered from acute pain. Taking these criteria into consideration, the functional outcome was excellent in 8, good in 3, and fair in 3 patients.

A total of 16 complications occurred in 14 patients. The most common complication, which occurred in 8 patients, was inflammation and maceration of soft tissue around the needle. It occurred as a result of non-compliance with the aseptic and antiseptics principles as well as weak tension of the pins. The inflammation was local and was quickly recovered with a prompt treatment (uniform tension of the pins, bandaging, perifocal administration of antibiotics). In 1 patient, after the abovementioned treatment, the inflammatory process was not repaired and it extended along with the formation of abscesses. We had to remove the needle from the area of inflammation, soft tissues were indicated and drained and antibacterial therapy was administered. Upon the soothing of the inflammation, the needle was re-applied through the healthy parts of the skin. During needle placement in 2 patients, due to termonecrosis of the bone, sequestration ring that was the cause of "osteomyelitis needles" was created. The needles were drawn out and the needle canal expanded and drained which led to remediation of the infection. During the treatment, the acute exacerbation of chronic osteomyelitis occurred in 2 patients, and in 3 patients the wound did not heal and pseudoarthrosis occurred. All 5 patients were subjected to the additional surgical treatment. In the treatment process, dermatitis occurred in 1 patient.

## Discussion

Results of treatment of open fractures depend on the treatment of joint soft tissue injuries. Adequate coverage with soft tissue and revascularization will provide the best conditions for the incorporation of the bone graft and the subsequent bone formation [1]. Spongioplasty will provide good results when the place of implantation is well vascularized. Therefore, unnecessary delay of spongioplasty is not recommended [2].

In their study, Atesalpa et al. analyzed the results of treatment of 43 patients with a bone defect. 18 patients with the bone defect had chronic osteomyelitis of the tibia as well. The average length of the defect was 10.1 cm (2-15 cm). The average duration of external fixation was 15.8 months. In all cases the treatment was carried out without antibiotic therapy. The authors annotated this with an aggressive debridement of necrotic and infected bone, as well as with the increase of the intramedullary circulation by the osteotomy of one of the fragment of the tibia [9].

According to Gustillo, in cases of open fractures type II and III, spongioplasty can be performed 2 weeks after the soft tissue coverage, using the skin graft or local muscle flap [3]. In cases of the third degree fracture which requires major reconstruction of soft tissue using free tissue transfer, it would be useful to postpone the spongioplasty for 4-6 weeks after the reconstruction of soft tissue [2]. Insistence on this approach lies in the uncertainty that the adequate debridement has been done, because in cases of the injurie inflicted by a high energy, additional debridement needs to be done. Many authors recommend war wounds re-excision within 24-48 hours, as it is difficult to make a precise assessment of the tissue vitality at the time of primary excision [4].

In his experimental studies, Albreht discovered that local

administration of antibiotics up to three hours after the injury may provide a 72-hours delay of the primary surgical management of the wound without increasing the incidence of local infection. Jackson came to similar conclusion during the Falklands War. Antibiotic therapy was administered not later than 6 hours after the wounding. The results showed that there were no septic complications when the antibiotics were administered three hours after the wounding, because they inhibited the growth of bacteria in the gunshot wounds [10].

During the treatment of 1.361 patients with gunshot fractures of long bones in Angola, Karapetjen and Petrov adopted the attitude that the internal osteosynthesis can be performed with previous administration of antibiotics. Apart from the abovementioned osteosynthesis, after 21 days the tibial or fibular bone grafting was performed in 17 patients. The result of treatment was satisfactory in 11 patients and poor in 8 [11].

Mironov used the property of spongiosis resistance to infection, and laminated the osteomyelitic defects using the spongiosis parts and leaving the wound open after the lamination. Mironov called this method "the open spongioplastics" [12].

On the basis of the experiences in the Afghanistan war regarding the treatment of bone defects, Gricanov et al. preferred the external fixators and insisted on compressive and distraction external fixators with hinged joints [13]. Jovanovic submitted criteria for treatment of the bone defect in long bones with autogenous bone grafts and stabilization of bone fragments with the compressive AO plates [14].

Spongioplasty is generally accepted to be able to provide a satisfactory result if the bone defect is 4 cm or less and soft tissue coverage is good [1-3].

## Conclusion

Having a modest selection of medical supplies, antibiotics, ANAT vaccine... We used an external fixator. Base on mentioned material (We had no other choice during war) our experience was that the application of early autogenous spongioplasty in bone defects of war wounds proved to be successful and possible in the primary stage of treatment. It can be used if it meets the following criteria: the primary surgical treatment of war wounds is made according to military surgical doctrine, stable stabilization of bone fragments with an external fixator, lack of clinical and laboratory signs of infection and the bone defect should not exceed 4 cm. The bone graft must be covered with healthy muscular or cutaneous tissue. When compared to delayed autospongiolasty, the application of the early spongioplasty reduces the number of surgical treatments for the injured person. In other words, early cancellous bone grafting averagely avoids one surgery for the wounded patient. Rigid osteosynthesis with AO plate along with delayed spongioplasty proved to be very successful in the secondary treatment of large number of samples taken from the abovementioned war. The basic condition for the use of this method is: the first phase is completed; lack of clinical and laboratory signs of infection and the bone defect not higher than 4 cm.

Fibular graft is used in bone defects larger than 4 cm. This method

requires long-term hospitalization and is followed by the possibility of the occurrence of number of complications due to the graft size and its incorporation.

The extension of one of the fragments using the Ilizarov method can successfully compensate for the bone defect of 11.5 cm and equalize the limb in one act. This method brings the possibility of "unlimited" creation of bone tissue. The use of antibiotics is not required, because during the period of distraction, the Ilizarov apparatus increases the bactericidal activity of the tissue.

The results show that, in compensation of bone defect, the advantage is given to the primary spongioplastics over the delayed spongioplastics in cases of bone defects not higher than 4 cm. In cases of bone defects over 4 cm, the advantage is given to the Ilizarov distraction osteogenesis over the fibular grafting.

## References

1. Grubor P (2014) Treatment of War Wounds the Extremities, Nova Science Publishers, New York, USA
2. Grubor P (2012) Treatment of Bone Defects, LAP LAMBERT Academic Publishing GmbH&Co, Saarbrücken, Germany
3. Grubor P, Grubor M, Asotic M (2011) Comparison of Stability of Different types of External Fixation. *Med Arh.* 65: 157-159.
4. Grubor P, Falzarano G, Medici A, Grubor M, Franzese R, et al. (2014) The Damage Control Orthopedics and External Fixation in traffic accident after 20 Years in the Bosnian War: Our Experience and a Review of the Literature. *SYLWAN.* 158: 90-109.
5. Grubor P, Faizarano G, Grubor M, Piscopo A, Franzese R, et al. (2014) Treatment of the cronic War tibial osteomyelitis, Gustilo tipe IIIb and cierny IIIb, using various methods. A retrospective study. *Euromediterran Biomedical Journal.* 9: 7-18.
6. Phemister DB (1947) Treatment of ununited fractures by onlay bone grafts without screw or tie fixation and without breaking down of the fibrous union. *J Bone Joint Surg Am.* 29: 946-960.
7. Taylor GI, Miller GD, Ham FJ (1975) The free vascularized bone graft. A clinical extension of microvascular techniques. *Plast Reconstr Surg* 55: 533-544.
8. Ilizarov GA, Barabash AP, Larionov AA (1983) Experimental and clinical approval of a method of replacing extensive defects in the long bones. *Ortop Travmatol Protez.* 6-9.
9. Atesalp AS, Basbozkurt M, Erler E, Sehrioglu A, Tunay S, et al. (1998) Treatment of tibial bone defects with the Ilizarov circular external fixator in high-velocity gunshot wounds. *Int Orthop* 22: 343-347.
10. Albreht M, Šćepanović D, Ceramilac A, Milivojević V, Berger S, et al. (1979) Experimental soft tissue wounds caused by standard military rifles. *Acta Chir. Scand. Suppl.* 489: 185-189.
11. Karapetjan S, Petrov V (1984) Taktika hirurgičeskog lečenja ognestrelnih prelomov trubčatih kostej. *Ortop Travmat Protez.* 11-14
12. Mironov GM, Nemytin luV, Konovalov VA, Smirnov EG (1991) The specialized treatment of the wounded with complications and unfavorable sequelae of gunshot wounds to the extremities. *Voen Med Zh* Jul 17-18.
13. Coupland RM (1991) The role of Reconstructive surgery in the management of War Wounds. *Ann R Coll Surg Engl* 73: 21-25.
14. Jovanović Z, Popović Z, Sar I (1992) Hirurško lečenje strelnih preloma-primarna hirurgija. Zbornik radova kongresa Zsl I SnSl u ratu. Banja Luka 171-172.