

Transvaginal Excision of Transverse Vaginal Septum in Children

Mohammed A Jouda*, A M Obaideen, Mohammed Zayed and Hossam Hamdy

University Hospital Sharjah, P.O Box 72772 Sharjah, UAE

Abstract

Congenital anomalies of the female genital tract are often asymptomatic and therefore unrecognized. They usually present at adolescent with abdominal pain at the time of menarche. This is a report of two teen aged girls who presented to the University Hospital-Sharjah (UHS) complaining of recurrent attacks of cyclical lower abdominal pain which comes within the premenstrual periods and fades after menses. They were investigated and managed in other hospitals with no improvement. The two patients were diagnosed by trans-abdominal and trans-perineal pelvic U/S in addition to MRI studies which confirmed the diagnosis of didelphys uterus with an obstructing transverse vaginal septum leading to hematocolpos and hematometrocolpos in addition to the presence of an ipsilateral renal agenesis. Per-operative hysteroscopy was valuable in identification of the abnormal anatomy. The technique of transvaginal surgical excision of the septum in both cases with attempt to preserve the hymen in addition to the problems in diagnosis and management of these rare anomalies are discussed.

Introduction

Development of the female genital tract is a complex process dependent upon a series of events involving cellular differentiation, migration, fusion and canalization. Failure of any one of these processes results in different types of anomalies of the vagina and uterus.

The incidence of congenital uterine anomalies is difficult to determine since many women with such anomalies are not diagnosed, especially if they are asymptomatic [1-7].

In one of the best designed studies, the incidence of congenital uterine anomalies in fertile women was 3.2 percent. The type and frequency of abnormality were septate uteri (90%), bicornuate uterus (5%), and didelphys uterus (5%) [1]. Another study included a combined population of infertile and fertile women, the frequency of anomalies by type was: septate (35%) bicornuate (26%), arcuate (18%), unicornuate (10%), didelphys (8%), and agenesis (3%) [7].

Classification of subtypes of congenital abnormalities of the female reproductive system is important in the treatment of infertility and symptoms arising from obstruction or deformity [8]. Many classifications of uterine anomalies exist; Buttram and Gibbons [9], According to the modified AFS classification [10], uterovaginal anomalies are categorized as dysgenesis disorders or vertical or lateral fusion defects. Anomalies are further subcategorized into obstructive or nonobstructive forms, since their treatment differs. Obstructive uterovaginal anomalies require immediate attention because of retrograde flow of trapped mucus and menstrual blood and increasing pressure on surrounding organs.

Transverse vaginal septum occurs in approximately 1 in 30,000 to 1 in 80,000 women [11]. These septa may be located at various levels in the vagina; approximately 46 percent are found in the upper vagina, 35 to 40 percent in the middle portion and 15 to 20 percent in the lower vagina [12]. The septa are generally less than 1 centimetre in thickness and may have a small central or eccentric perforation [13]. The majority of transverse vaginal septa have a fenestration and are thus not completely obstructed. The diagnostic work up of vaginal and uterine anomalies has improved by the use of MRI and hysteroscopy.

In this report, we describe the presentation of two girls diagnosed as having didelphys uterus with a unilateral transverse vaginal septum and operated at the University Hospital-Sharjah (UHS), U.A.E. Diagnostic work up, surgical management, follow up and lessons learned are described.

Case 1

A fourteen years old girl presented complaining of colicky cyclical suprapubic pain for fourteen months duration. Pain started with menarche at twelve. It continues for few days then fades after menses. She was diagnosed in another hospital as a case of hematocolpos for which she underwent examination under general anaesthesia with aspiration of the collected blood. Pain recurred in few weeks and referred to our hospital.

Rectoabdominal (PR) examination revealed a mildly tender soft mass palpated just above the examining finger towards the left side. Trans-abdominal pelvic U/S, trans-perineal U/S and MRI studies confirmed the presence of two completely separated uteri with bilateral normal uterine cavities and two cervixes. Right uterus was communicated with a normal vagina while the left uterus was communicated with a distended vagina "hematocolpos" due to the presence of a transverse vaginal septum. A distance of 4 cm between the septum and the labia major was measured by trans-perineal ultrasound and sagittal MRI, the septal thickness was 5 mm.

Diagnosis of didelphys uterus with a left sided transverse vaginal septum was confirmed in addition to left renal agenesis (Figures 1a and 1b).

Case 2

A fourteen and a half years old girl referred to University Hospital-Sharjah (UHS) complaining of colicky cyclical suprapubic pain for the last two years. The pain continues for few days then disappears after menses. The patient had two previous attacks of acute abdomen diagnosed in another hospital as haemoperitoneum and treated surgically. For the first attack an explorative laparotomy was done and

*Corresponding author: Mohammed A Jouda, General Surgeon, University Hospital Sharjah, P.O Box 72772 Sharjah, UAE, E-mail: mohammed.jouda@uhs.ae

Received May 20, 2013; Accepted September 23, 2013; Published September 25, 2013

Citation: Jouda MA, Obaideen AM, Zayed M, Hamdy H (2013) Transvaginal Excision of Transverse Vaginal Septum in Children. J Clin Case Rep 3: 302. doi:10.4172/2165-7920.1000302

Copyright: © 2013 Jouda MA, et al. This is an open-access article distributed under the terms of the Creative Commons Attribution License, which permits unrestricted use, distribution, and reproduction in any medium, provided the original author and source are credited.

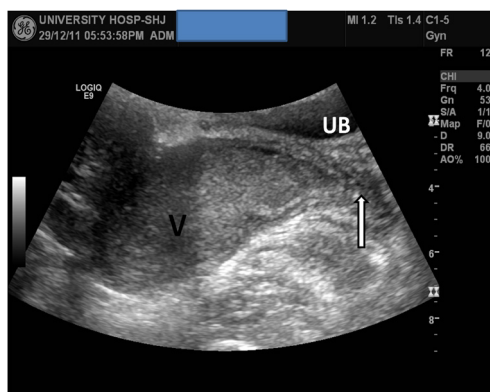


Figure 1a: Sagittal transabdominal pelvic ultrasound showing dilated left vagina with debris "V", and the level of the distal left vaginal obstruction "long arrow". UB: urinary bladder.

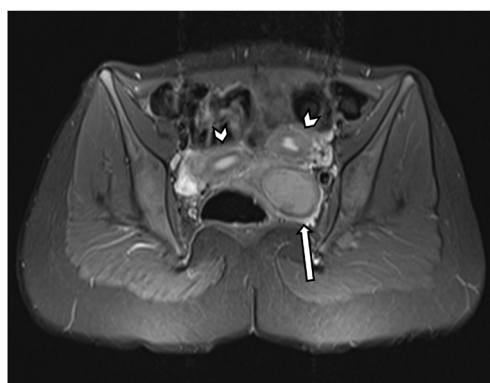


Figure 1b: Upper pelvic axial T2 fat sat MRI, normal left and right uteri "arrow head", dilated left vagina "long arrow".

she was diagnosed as a case of didelphic uterus while the collected blood was evacuated from the peritoneal cavity. For the second attack blood was evacuated laparoscopically. She was put on combined contraceptive pills to induce amenorrhea.

When referred to our hospital, abdominal examination revealed a mildly tender right sided pelvi-abdominal mass (distended right uterus), hemispherical in shape, about 10 cm in diameter with a smooth regular surface. Trans-abdominal U/S, trans-perineal U/S and MRI studies revealed the presence of two completely separated uteri, two cervixes and two vaginas. Left uterus was communicated with a normal vagina while the right uterus was distended and communicated with a hugely distended vagina due to a transverse vaginal septum diagnosed as "hematometocolpos". A distance of 3.8 cm between the septum and the labia major was measured by trans-perineal ultrasound and sagittal MRI, the septal thickness was 4 mm.

Diagnosis of didelphys uterus with right sided transverse vaginal septum was confirmed in addition to right renal agenesis (Figures 2a and 2b).

Management

The hysteroscopic examination and surgical technique in the two patients were the same. Transvaginal surgical approach was performed under general anaesthesia. Examination identified an intact hymen and with gentle retraction on it, using small Lamgenbeck retractors, it

was possible to access the vagina without complete tear of the hymen. The obstructing transverse vaginal septum was identified bulging on the abnormal side (left side in case 1 and right side in case 2), about 4 cm high in the vagina. Hystoscopic examination of the normal patent side done and revealed normal hemivagina, cervix and uterine cavity. In order to confirm and localize the proper site for surgical incision, a wide bore needle was used to aspirate few millilitres of the collected blood through the obstructing tissue. Excision of the obstructing vaginal tissue using diathermy creating 3 cm length transverse opening. Complete evacuation of the hematocolpos and hematometrium done. About 450 ml of old altered blood in case 1 and 700 ml in case 2. This was followed by proper wash and irrigation of the obstructed uterine cavity and vagina. Vaginoplasty performed by marsupialisation of the edges of the incised septum using 4/0 interrupted vicryl sutures. Hysteroscopic examination of the recently opened vagina and uterine cavity done. The retracted hymen was found to be intact.

Both patients had smooth postoperative recovery and discharged after 48hrs in good general condition. During their regular follow up visits they started to have regular menses with no complains and frequent follow up trans-abdominal U/S studies showed patent both vaginas with marked reduction in the sizes of the previously distended uteri and vaginas till they came back gradually to the same sizes of the opposite normal non-obstructed sides.

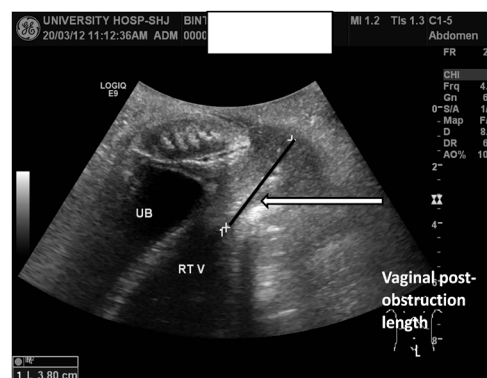


Figure 2a: Trans-perineal ultrasound showing the distance of the distal vaginal obstruction from labia major 'long arrow'.

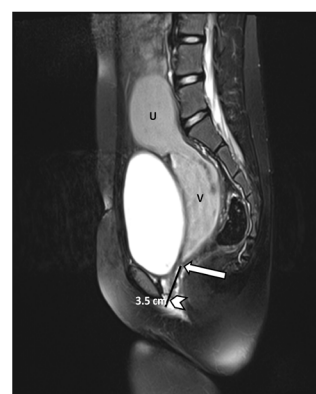


Figure 2b: Sagittal T2 fat saturated MRI sequence showing: dilated right uterus "U", dilated right vagina "V", level of obstruction "long arrow" and the distance of the distal vaginal obstruction from the labia minor "arrow head".

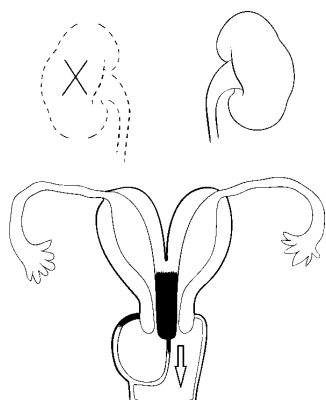


Figure 3: Uterus didelphys with right obstructed hemivagina with ipsilateral renal agenesis.

Discussion

Septated vagina occurs in 75 percent of didelphic uterus cases [14,15] and once the diagnosis of a transverse vaginal septum is established; it is advisable to interfere surgically and relieve the obstruction. Renal anomalies as in our two patients are found in 20 to 30 percent of women with müllerian defects [14,15]. Therefore, all women with müllerian defects should be investigated by intravenous pyelogram or renal ultrasound or CT scan study (Figure 3).

In our patients the initial diagnosis and management was incomplete with no improvement. Frequent aspiration of the hematocolpos/hematometocolpos and laparoscopic evacuation of hemoperitoneum are not recommended as they do not deal directly with the obstructing anomaly as well as they are not safe procedures and may induce infection.

For identifying the anatomic causes of reproductive tract anomalies and for evaluating pelvic pain or mass; ultrasound examination (transabdominal, transvaginal and transperineal) can be helpful [16-22]. Although MRI has historically been considered the "gold standard" for diagnosing anomalies of the reproductive tract [23-26]. Other modalities may be useful for evaluation. A hysterosalpingogram, performed on an outpatient basis with the use of fluoroscopy, can be helpful in determining the patency and possible complex communications in cases of genital tract anomalies [25]. Sonohysterography and 3-dimensional (3-D) ultrasound have also been shown to be helpful [27,28]. 3-D ultrasound is noninvasive, highly accurate, and able to provide detailed images of uterine anatomy. In cases of complicated müllerian anomalies, additional information may also be obtained by examination with the patient under anaesthesia, vaginoscopy, laparoscopy, and/or hysteroscopy. However, these procedures are required less frequently because of the radiologic advances described above [17-21].

Women with a transverse vaginal septum require surgical correction due to pain, increased risk of infection, retrograde menses and difficulty with sexual intercourse or vaginal delivery. A small transverse vaginal septum can be resected, followed by an end-to-end anastomosis of the upper and lower vaginal mucosa. A thick septum is more difficult to excise and repair; excision should be attempted only by surgeons experienced with this procedure. Re-anastomosis is easier if the upper vagina has been distended with menstrual blood products, as this acts as a natural tissue expander to increase the amount of upper vaginal

tissue available for the re-anastomosis. In addition, preoperative use of vaginal dilators may thin the septum and facilitate re-anastomosis. A Z-plasty technique can be used to prevent circumferential scar formation [29]. Great care is taken to avoid the bladder, rectum and the cervixes. The two cervixes may be at different levels; therefore, the tissue between them should be left in place so as not to compromise their blood supply.

Conclusions

- In general, surgical intervention is not indicated for uterine didelphys but Metroplasty should be considered for women with pelvic pain, recurrent miscarriages, or a history of preterm delivery, otherwise asymptomatic patients may have normal reproductive life.

- usually, patients with congenital vaginal septum become symptomatic at the age of menarche and surgical excision of that septum with vaginoplasty is mandatory once it is discovered and/ or became symptomatic.

- ymen preservation in virgin patients during vaginal septum excision is possible and should be tried in certain communities and circumstances.

- Hysteroscopy is a minimally invasive intervention that can be used to diagnose and treat many intrauterine, endocervical and vaginal problems including congenital anomalies. Given their safety and efficacy, diagnostic and operative hysteroscopy have become standards in gynecologic practice.

References

1. Simón C, Martinez L, Pardo F, Tortajada M, Pellicer A (1991) Müllerian defects in women with normal reproductive outcome. *Fertil Steril* 56: 1192-1193.
2. Cooper JM, Houck RM, Rigberg HS (1983) The incidence of intrauterine abnormalities found at hysteroscopy in patients undergoing elective hysteroscopic sterilization. *J Reprod Med* 28: 659-661.
3. Acién P (1997) Incidence of Müllerian defects in fertile and infertile women. *Hum Reprod* 12: 1372-1376.
4. Ashton D, Amin HK, Richart RM, Neuwirth RS (1988) The incidence of asymptomatic uterine anomalies in women undergoing transcervical tubal sterilization. *Obstet Gynecol* 72: 28-30.
5. Raga F, Bauset C, Remohi J, Bonilla-Musoles F, Simón C, et al. (1997) Reproductive impact of congenital Müllerian anomalies. *Hum Reprod* 12: 2277-2281.
6. Jurkovic D, Gruboeck K, Taylor A, Nicolaides KH (1997) Ultrasound screening for congenital uterine anomalies. *Br J Obstet Gynaecol* 104: 1320-1321.
7. Grimbizis GF, Camus M, Tarlatzis BC, Bontis JN, Devroey P (2001) Clinical implications of uterine malformations and hysteroscopic treatment results. *Hum Reprod Update* 7: 161-174.
8. Nahum GG (1998) Uterine anomalies. How common are they, and what is their distribution among subtypes? *J Reprod Med* 43: 877-887.
9. Buttram VC Jr, Gibbons WE (1979) Müllerian anomalies: a proposed classification. (An analysis of 144 cases). *Fertil Steril* 32: 40-46.
10. Rock JA, Adam RA (2000) Surgery to repair disorders of development. *Gynecologic, obstetric and related surgery*. (2nd edn), St Louis Mo: Mosby.
11. Rock JA, Azziz R (1987) Genital anomalies in childhood. *Clin Obstet Gynecol* 30: 682-696.
12. LODI A (1951) [Clinical and statistical study on vaginal malformations at the Obstetrical and Gynecological Clinic in Milano, 1906-50]. *Ann Ostet Ginecol* 73: 1246-1285.
13. Suidan FG, Azoury RS (1979) The transverse vaginal septum: a clinicopathologic evaluation. *Obstet Gynecol* 54: 278-283.
14. Lin PC, Bhatnagar KP, Nettleton GS, Nakajima ST (2002) Female genital anomalies affecting reproduction. *Fertil Steril* 78: 899-915.

15. Oppelt P, von Have M, Paulsen M, Strissel PL, Strick R, et al. (2007) Female genital malformations and their associated abnormalities. *Fertil Steril* 87: 335-342.
16. Shatzkes DR, Haller JO, Velcek FT (1991) Imaging of uterovaginal anomalies in the pediatric patient. *Urol Radiol* 13: 58-66.
17. Valdes C, Malini S, Malinak LR (1984) Ultrasound evaluation of female genital tract anomalies: a review of 64 cases. *Am J Obstet Gynecol* 149: 285-292.
18. Scanlan KA, Pozniak MA, Fagerholm M, Shapiro S (1990) Value of transperineal sonography in the assessment of vaginal atresia. *AJR Am J Roentgenol* 154: 545-548.
19. Blask AR, Sanders RC, Gearhart JP (1991) Obstructed uterovaginal anomalies: demonstration with sonography. Part I. Neonates and infants. *Radiology* 179: 79-83.
20. Blask AR, Sanders RC, Rock JA (1991) Obstructed uterovaginal anomalies: demonstration with sonography. Part II. Teenagers. *Radiology* 179: 84-88.
21. Raga F, Bonilla-Musoles F, Blanes J, Osborne NG (1996) Congenital Müllerian anomalies: diagnostic accuracy of three-dimensional ultrasound. *Fertil Steril* 65: 523-528.
22. Pui MH (2004) Imaging diagnosis of congenital uterine malformation. *Comput Med Imaging Graph* 28: 425-433.
23. Markham SM, Parmley TH, Murphy AA, Huggins GR, Rock JA (1987) Cervical agenesis combined with vaginal agenesis diagnosed by magnetic resonance imaging. *Fertil Steril* 48: 143-145.
24. Fedele L, Dorta M, Brioschi D, Giudici MN, Candiani GB (1990) Magnetic resonance imaging in Mayer-Rokitansky-Küster-Hauser syndrome. *Obstet Gynecol* 76: 593-596.
25. Pellerito JS, McCarthy SM, Doyle MB, Glickman MG, DeCherney AH (1992) Diagnosis of uterine anomalies: relative accuracy of MR imaging, endovaginal sonography, and hysterosalpingography. *Radiology* 183: 795-800.
26. Bakri YN, Al-Sugair A, Hugosson C (1992) Bicornuate nonfused rudimentary uterine horns with functioning endometria and complete cervical-vaginal agenesis: magnetic resonance diagnosis. *Fertil Steril* 58: 620.
27. Soares SR, Barbosa dos Reis MM, Camargos AF (2000) Diagnostic accuracy of sonohysterography, transvaginal sonography, and hysterosalpingography in patients with uterine cavity diseases. *Fertil Steril* 73: 406-411.
28. Alborzi S, Dehbashi S, Parsanezhad ME (2002) Differential diagnosis of septate and bicornuate uterus by sonohysterography eliminates the need for laparoscopy. *Fertil Steril* 78: 176-178.
29. Garcia RF (1967) Z-plasty for correction of congenital transverse vaginal septum. *Am J Obstet Gynecol* 99: 1164-1165.