

Toxic Leucoencephalopathy Due to CHOP Therapy in a Patient with NonHodgkin's Lymphoma

Chetanya Malik*, Aditya Kutiya, Sanjay Pandit, Sandeep Garg and Naresh Gupta

Maulana Azad Medical College, New Delhi, India

Abstract

Toxic leucoencephalopathy is damage to cerebral white matter due to exposure to cranial irradiation, environmental toxins, drugs of abuse and chemotherapeutic agents. It results in wide variety of clinical manifestations like personality change, inattention, memory loss, abulia, stupor, coma and death. It leads to white matter demyelination which is visible on T2 weighted MRI as hyperintensity. We report a rare case of a 14-year-old boy with large B cell lymphoma who developed toxic leucoencephalopathy due to exposure to CHOP regimen.

Keywords: Toxic; Leucoencephalopathy; Non-hodgkin's lymphoma; CHOP

Introduction

Leucoencephalopathy is structural alteration in cerebral white matter due to myelin damage. Toxic leucoencephalopathy is caused by cranial irradiation, environmental toxins, drugs of abuse and chemotherapeutic agents. It causes symptoms ranging from forgetfulness, inattention and personality change to dementia, coma and death. We present here a case of toxic leucoencephalopathy in a patient with non-hodgkin's lymphoma.

Case Report

A 14-year-old boy presented with complaints of moderate grade fever associated with loss of appetite and easy fatigability for last 20-25 days and black tarry liquid stools for last 7-10 days. There was no history of jaundice, abdominal distension, pedal edema or weight loss. On examination the patient was conscious, oriented and vitals were stable. There was pallor and petechial rash present diffusely on bilateral lower limbs and abdomen. There was single right submandibular lymph node of size 1.5 cm by 2 cm. On per abdomen examination, liver was palpable 6 cm below the costal margin and spleen was palpable 8 cm below the costal margin. Laboratory investigations revealed severe pancytopenia with Hemoglobin (Hb) of 3.8 g/dl, Total leucocyte count (TLC) of 290 cells/mm³ with 18% polymorphs, 82% lymphocytes and 2% monocytes and platelet count (P/C) of 8,000/mm³. ESR was 104 mm. Kidney function tests (KFT), liver function tests (LFT), serum calcium, phosphate, serum protein and albumin were within normal limits. Peripheral smear showed no atypical cells. CECT chest and abdomen revealed hepatosplenomegaly with multiple lymph nodes in right paratracheal, pre- and para-tracheal, pre- and sub-carinal region largest measuring 11 mm. Lymph node biopsy of the submandibular lymph node was suggestive of reactive lymphadenitis. Bone marrow aspirate was suggestive of few atypical cells, while biopsy revealed large atypical cells having vesicular nuclei and moderate to abundant vacuolated cytoplasm. Many cells showed prominent nucleoli and nuclear grooving and many mitotic figures were also seen. Immunophenotyping showed atypical cells are strongly positive for CD 19 and CD 10, weakly positive for LCA and negative for CD45RO, CD34, CD68, CD30, ALK and antiMPO. On the basis of above findings, a diagnosis of stage IV Large B cell Non-Hodgkin's lymphoma was made and was started on CHOP regimen that included Injection (inj.) Cyclophosphamide 750 mg/m², Inj. Doxorubicin 50 mg/m², Inj. Vincristine 1.4 mg/m² and tablet prednisolone 40 mg/m² for 5 days.

Around 10 days after completing the second cycle of chemotherapy, patient was admitted with the complaints of inability to pay attention,

decreased sleep, agitated behavior and abusive speech for last 2 days. There was no history of fever, headache or vomiting. There was no history of visual abnormality, weakness of any limb or history suggestive of cranial nerve abnormality. There was no history of sensory loss, gait abnormality or seizures. On examination, meningeal signs and neck rigidity were absent. Patient was conscious, oriented but agitated and unco-operative. His higher mental function could not be assessed because of agitated and unco-operative behavior. Rest of the central nervous system examination was normal.

Investigations revealed normal Hemoglobin, total leucocyte count, platelet count, KFT, LFT and serum calcium and phosphate. Cerebrospinal fluid (CSF) analysis revealed no cells, glucose of 66 mg/dl and protein of 20 mg/dl. CSF culture showed no growth. CSF sent for TBPCR, HSV PCR, Cryptococcal antigen were negative. CSF sent for malignant cells did not show any atypical cells on analysis. NCCT head revealed periventricular hypodensities in bilateral frontal region. MRI brain as shown in Figures 1 and 2 revealed confluent, symmetric hyperintensity in periventricular white matter in B/L frontal regions on T2 and FLAIR images with no restricted diffusion and contrast enhancement. There were few areas of subcortical white matter hyperintensity. There was no meningeal enhancement, lymphomatous deposits, hydrocephalus or any granuloma.

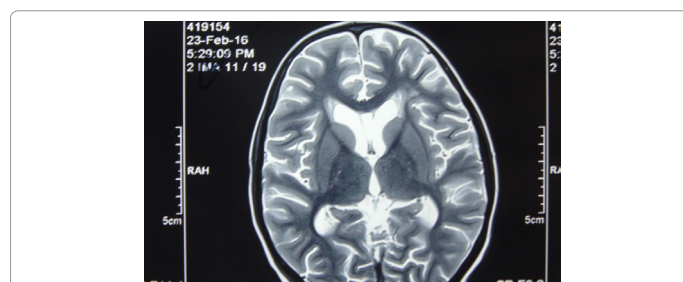


Figure 1: T2 MRI BRAIN image showing periventricular hyperintensity in white matter.

*Corresponding author: Chetanya Malik, Maulana Azad Medical College, New Delhi, India, Tel: 011 2323 9279; E-mail: drchetanyamalik86@gmail.com

Received May 28, 2017; Accepted August 18, 2017; Published August 24, 2017

Citation: Malik C, Kutiya A, Pandit S, Garg S, Gupta N (2017) Toxic Leucoencephalopathy Due to CHOP Therapy in a Patient with NonHodgkin's Lymphoma. J Clin Case Rep 7: 1006. doi: [10.4172/2165-7920.10001006](https://doi.org/10.4172/2165-7920.10001006)

Copyright: © 2017 Malik C, et al. This is an open-access article distributed under the terms of the Creative Commons Attribution License, which permits unrestricted use, distribution, and reproduction in any medium, provided the original author and source are credited.

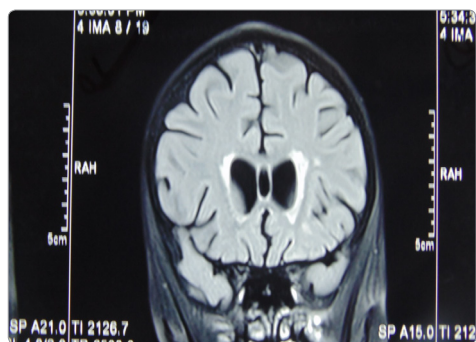


Figure 2: FLAIR MRI image showing similar area with hyperintensity.

On the basis of neurobehavioural manifestations in a patient of Non-Hodgkin's lymphoma who has received chemotherapy in the form of CHOP therapy and corroborative imaging findings with lack of any feature suggestive of CNS involvement in lymphoma or any infectious cause, a diagnosis of toxic leucoencephalopathy due to CHOP therapy was made.

Patient was initially managed with parenteral antipsychotics and benzodiazepines, after which the patient improved in 1 week. His 3rd cycle of chemotherapy was delayed by approximately 10 days due to the above manifestations. These neurobehavioural manifestations did not recur again and patient had completed 6 cycles of chemotherapy. Repeat bone marrow examination revealed no atypical cells and repeat CT scan showed normal size of liver and spleen without any intra-abdominal or mediastinal lymphadenopathy. His MRI brain repeated after the 6th cycle showed similar symmetric, confluent periventricular hyperintensity as seen in previous MR imaging.

Discussion and Conclusion

Toxic leucoencephalopathy should be considered a possibility in a patient with neurobehavioural manifestations and exposure to toxins

causing white matter damage. The range of disease severity varies from mild cases resulting in inattention and forgetfulness to severe disease resulting in dementia, coma and death [1]. It does not usually affect language function [2]. The diagnosis of this rare but increasingly recognised clinical entity requires exposure to toxin, neurobehavioural manifestations and neuroradiological abnormalities consistent with the diagnosis.

Among various neuroimaging modalities, T2 weighted MRI is the imaging of choice because of its ability to display white matter changes [3]. T2, DWI and FLAIR shows symmetrical and confluent white matter hyperintensity initially involving periventricular white matter in mild cases to diffuse involvement with areas of necrosis in cerebral white matter.

While toxic leucoencephalopathy is well known with various chemotherapeutic changes especially methotrexate, CHOP therapy related leucoencephalopathy is very rarely reported in literature. Cain et al. reported first such case report in 1998 which was a severe form of disease and was fatal [4]. The therapy needs to be stopped in severe cases, however in our case we had a patient with mild disease and therapy was completed. Thus, all neurobehavioural manifestations must be thoroughly evaluated and investigations in a patient with exposure to toxins keeping in mind the possibility of toxic leucoencephalopathy.

References

1. Filley CM, Kleinschmidt-Demasters BK (2001) Toxic leucoencephalopathy. *N Engl J Med* 345: 425-432.
2. Filley CM (1998) The behavioral neurology of cerebral white matter. *Neurology* 50: 1535-1540.
3. Miller AKH, Alston RL, Corsellis JAN (1980) Variations with age in the volumes of grey and white matter in the cerebral hemispheres of man: measurements with an image analyser. *Neuropathol Appl Neurobiol* 6: 119-132.
4. Cain MS, Burton GV, Holcombe RF (1998) Fatal leucoencephalopathy in a patient with non-Hodgkin's lymphoma treated with CHOP chemotherapy and high-dose steroids. *Am J Med Sci* 315: 202-207.