

Totally Extraperitoneal Herniorrhaphy (TEP) after Ipsilateral Spermatic Vein Embolization: A Case Report

Diedert Luc De Paep^{1*}, Vincent De Coninck², Nele Van De Winkel¹ and Dirk Michielsens²

¹Department of Surgery, University Hospital of Brussels, Belgium

²Department of Urology, University Hospital of Brussels, Belgium

Abstract

Introduction: Both totally extraperitoneal herniorrhaphy (TEP) and spermatic vein embolization are minimal invasive techniques gaining in popularity in the treatment of inguinal hernia and varicocele respectively. A previous spermatic vein embolization makes a TEP more difficult because of fibrotic changes of the spermatic vein. This is to our knowledge the first case report describing these difficulties and changes after spermatic vein embolization.

Case Presentation: We report the case of a 37 year old male who presented with an uncomplicated left sided inguinal hernia and ipsilateral varicocele. He first underwent a percutaneous left spermatic vein embolization for a grade 3 varicocele and later a TEP for the inguinal hernia. Reduction of the peritoneum and proper mesh placement were complicated due to fibrotic changes of the spermatic vein. Due to the dissection and resection of the embolized spermatic vein there was minor blood loss, increased operating room time and postoperative pain was more than average.

Conclusions: In case of a concomitant inguinal hernia and ipsilateral varicocele requiring embolization we propose to treat these diseases concomitantly or first treat the inguinal hernia and embolising the varicocele after repair of the hernia.

Keywords: Totally extraperitoneal herniorrhaphy (TEP); Spermatic vein embolization; Varicocele; Inguinal hernia

Introduction

Both totally extraperitoneal herniorrhaphy (TEP) and spermatic vein embolization are minimal invasive techniques gaining in popularity in the treatment of inguinal hernia and varicocele respectively. Coincident appearance of inguinal hernia and varicocele is expected to be more frequent with regard to pathogenesis [1]. We present a case in which a concomitant varicocele and inguinal hernia was first treated with percutaneous spermatic vein embolization and a TEP afterwards. To prevent perioperative difficulties and possible complications a TEP should be done before a spermatic vein embolization if both diseases are not concomitantly treated operatively.

Inguinal hernia -TEP

An inguinal hernia is a protrusion of the peritoneum and possibly intra-abdominal contents through the abdominal wall at the inguinal canal. An inguinal hernia is classified anatomically as direct if located medial of the epigastric vasculature and herniating through the fascia of the posterior wall of the inguinal canal or indirect if located laterally of the epigastric vasculature and herniating through the deep inguinal ring.

Inguinal hernias have a reported incidence of 1%-2% in males [1]. An uncomplicated inguinal hernia usually presents as a heaviness or dull discomfort at the groin sometimes accompanied with a visible bulge. Valsalva manoeuvre can precipitate or exacerbate the bulge. Complications include incarceration and strangulations necessitating reduction or emergent surgical intervention. Inguinal hernias are diagnosed by clinical examination and ultrasonography of the groin.

In general, symptomatic uncomplicated inguinal hernias in healthy individuals are an indication for elective repair. Open (e.g. Lichtenstein) and laparoscopic (e.g. TEP) approaches are available. There is no strong consensus for the use of open or laparoscopic procedure in the treatment of inguinal hernia and in general the approach should be the one the surgeon is most comfortable with. In experienced hands the recurrence rate is similar. In certain clinical situations an open or

laparoscopic approach can be indicated. Despite this TEP has grown in popularity and is increasingly performed [2,3].

Varicocele - Spermatic vein Embolization

A varicocele is an abnormal dilatation of the pampiniform venous plexus. It can be diagnosed in 15 percent of men. Idiopathic varicoceles are found at the left side because of the drainage into the left renal vein. When varicoceles are diagnosed at the right side, intra-abdominal or retroperitoneal obstructions should be excluded. A varicocele is associated with reduced sperm concentration, motility and morphology [4]. This can implicate a reduced fertility due to a decreased testicular growth and development. In general they are asymptomatic. Seldom they may cause scrotal discomfort or pain. Varicoceles are diagnosed by clinical examination and scrotal duplex ultrasonography. Varicoceles can be treated by surgery or percutaneous embolization with success rates exceeding ninety percent. When performing a surgical repair, all dilated veins are ligated. This can be done with an abdominal or (sub) inguinal approach, open or laparoscopically. In percutaneous embolization, the refluxing internal spermatic veins are occluded with a sclerosant or solid embolic device. None of these methods has been proven to be superior to the others in its ability to improve fertility. Complications of surgical repair are seen in up to 20% of patients. They include wound infection, hydrocele, prolonged pain, recurrence and rarely testicular atrophy [5]. Complication rates of percutaneous treatment vary from 0%-10%. They include thrombophlebitis or coil

***Corresponding author:** Diedert Luc De Paep, Department of Surgery, University Hospital of Brussels, Belgium, Tel: 0032 475 28 75 19; Fax: 0032 24 77 86 89; E-mail: diedert_depaep@hotmail.com

Received March 08, 2016; **Accepted** May 09, 2016; **Published** May 17, 2016

Citation: De Paep DL, De Coninck V, Van De Winkel N, Michielsens D (2016) Totally Extraperitoneal Herniorrhaphy (TEP) after Ipsilateral Spermatic Vein Embolization: A Case Report. J Clin Case Rep 6: 785. doi:10.4172/2165-7920.1000785

Copyright: © 2016 De Paep DL, et al. This is an open-access article distributed under the terms of the Creative Commons Attribution License, which permits unrestricted use, distribution, and reproduction in any medium, provided the original author and source are credited.

migration. Benefits of this treatment are minimally invasiveness and that patients recover quickly [6].

There is a lot of debate about the need of varicocele repair. Recent meta-analyses have shown that there is no benefit of treating men with normal semen analysis [7]. In case of abnormal semen analysis, only a few studies reported an improvement in semen parameters (concentration, motility and morphology) after varicocele repair [8]. In a meta-analysis of men with varicocele, oligozoospermia and unexplained infertility, there is a trend (but no significant difference) that treating a varicocele is moderately superior to observation for fertility [9]. In a recent meta-analysis studying men with a varicocele and an infertility duration longer than two years, it was shown that there is a significant higher pregnancy rate when treating these men [10]. In conclusion, varicocele repair may improve chances of fertility in infertile men. However, there is a lot of overtreatment and most men do not need treatment.

Case Description

A 37 year old male was referred to our outpatient clinic of abdominal wall surgery by the general practitioner because of an ultrasonic confirmed diagnosis of an uncomplicated left sided inguinal hernia and a left sided varicocele. The patient complained of dull discomfort and swelling in the left groin and testis. He has an unfulfilled desire to have children. His complaints are increasing over the last 15 years. Physical examination shows a left groin swelling that increases with valsalva manoeuvre. The varicocele is visible to the eye and palpable on physical exam so is graded as a grade 3 varicocele (Table 1). The medical history consisted of a deep vein thrombosis of the left calf veins following a knee arthroscopy and exertional palpitations. The patient is taking no medications. The case was discussed with our colleagues of the department of urology. Our idea was to treat both diseases operatively

Subclinical	Varicocele not detected on physical exam; found by radiologic or other imaging study.
Grade I	Varicocele only palpable during or after Valsalva maneuver on physical exam.
Grade II	Varicocele palpable on routine physical exam without the need for Valsalva maneuver.
Grade III	Varicocele visible to the eye and palpable on physical exam.

Table 1: Varicocele size and grading.

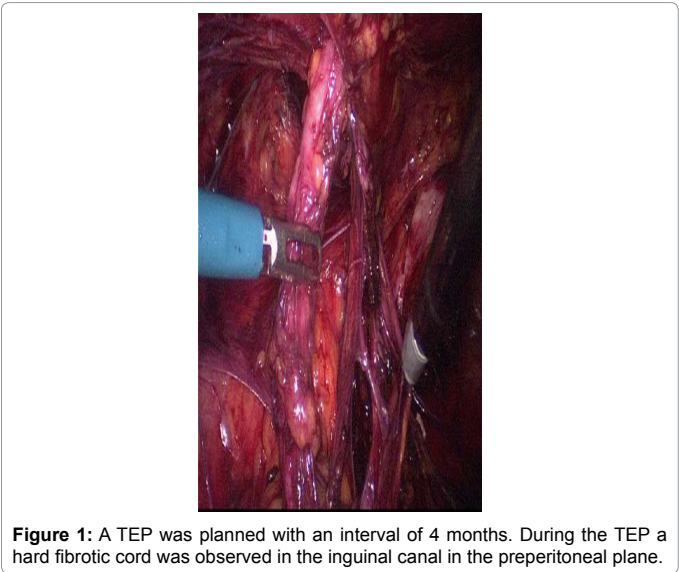


Figure 1: A TEP was planned with an interval of 4 months. During the TEP a hard fibrotic cord was observed in the inguinal canal in the preperitoneal plane.

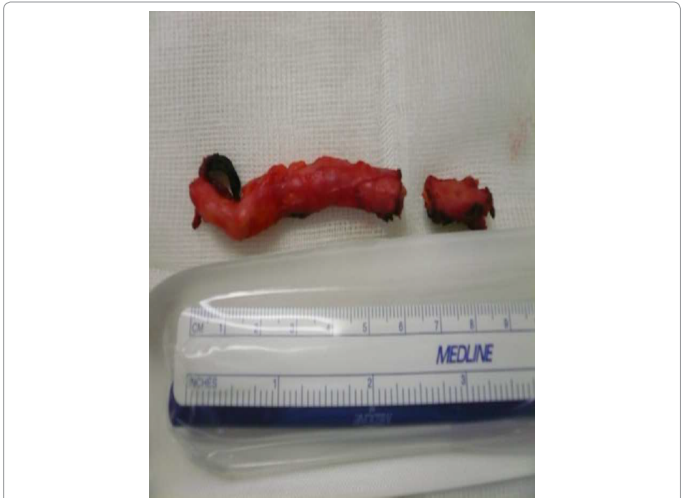


Figure 2: The structure prevented reduction of the peritoneal sac and proper mesh placement and was therefore partially resected.

concomitantly. But because a percutaneous spermatic vein embolization could be organized 4 months before a concomitant operation the patient preferred not to wait and a left spermatic vein embolization for a varicocele grade 3 was successfully performed. A TEP was planned with an interval of 4 months. During the TEP a hard fibrotic cord was observed in the inguinal canal in the preperitoneal plane (Figure 1). The hard fibrotic cord that we encountered was the left spermatic vein that was embolized 4 months before. The structure prevented reduction of the peritoneal sac and proper mesh placement and was therefore partially resected (Figure 2). This allowed us to successfully complete the operation with proper mesh placement. Due to the dissection and resection of the embolized spermatic vein there was minor blood loss, increased operating room time and postoperative pain was more then average. Two months after surgery the patient shows a good recovery but still has residual pain over the course of the resected spermatic vein.

Discussion

Spermatic vein embolization is a relatively new therapy for varicocele with still an unclear but growing position in treatment algorithms. TEP has already become the golden standard in inguinal hernia repair. Embolization of the spermatic vein causes fibrosis of the spermatic vein with entrapment and adhesion to the peritoneum. This makes reduction of the peritoneum difficult in case of hernia repair, in this case necessitating resection of the embolized vein. Placement of the mesh was also complicated due to sticky tissues and inflammatory changes. Both items led to minor blood loss, increased operating room time and more then average postoperative pain. To our knowledge this is the first case report describing these findings and possible complications. Considering the high incidence of inguinal hernia, varicocele and the growing popularity of spermatic vein embolization we expect the incidence of a TEP after spermatic vein embolization to grow. Our opinion is that in case of a concomitant inguinal hernia and ipsilateral varicocele a concomitant operative therapy or, in case of a spermatic vein embolization, a TEP first policy should be maintained. This way the described anatomic difficulties and concomitant complications can be prevented. If a patient presents with a inguinal hernia and a treated ipsilateral varicocele with spermatic vein embolization the technical difficulties and the possibility of more than average postoperative pain should be discussed with the patient.

References

1. Holzheimer RG, Schreiber A (2003) Inguinal hernia and concomitant varicocele mimicking mesh complication. *Eur J Med Res* 8:254-256.
2. Koning GG, Wetterslev J, van Laarhoven CJ, Keus F (2013) The totally extraperitoneal method versus Lichtenstein's technique for inguinal hernia repair: a systematic review with meta-analyses and trial sequential analyses of randomized clinical trials. *PLoS One* 8:e52599
3. Karthikesalingam A, Markar SR, Holt PJ, Praseedom RK (2010) Meta-analysis of randomized controlled trials comparing laparoscopic with open mesh repair of recurrent inguinal hernia. *Br J Surg* 97: 4-11.
4. Agarwal A, Sharma R, Harlev A, Esteves SC (2016) Effect of varicocele on semen characteristics according to the new 2010 World Health Organization criteria: a systematic review and meta-analysis. *Asian J Androl* 18: 296-309.
5. Shamsa A, Mohammadi L, Abolbashari M, Shakeri M, Shamsa S (2009) Comparison of Open and Laparoscopic Varicocelectomies in Terms of Operative Time, Sperm Parameters, and Complications. *Urol J* 6:170-175.
6. Beecroft D (2007) Percutaneous varicocele embolization. *Can Urol Assoc J* 1:278-280.
7. Grasso M, Lania M, Castelli M, Galli L, Franzoso F, et al. (2000) Low-grade left varicocele in patients over 30 years old: the effect of spermatic vein ligation on fertility. *BJU Int* 85: 305-307.
8. Will MA, Swain J, Fode M, Sonken J, Christman GM, et al. (2011) The great debate: varicocele treatment and impact on fertility. *Fertil Steril* 95:841-852.
9. Giagulli VA, Carbone MD (2011) Varicocele correction for infertility: which patients to treat? *Int J Androl* 34: 236-241.
10. Baazeem A, Belzile E, Ciampi A, Dohle G, et al. (2011) Varicocele and male factor infertility treatment: a new meta-analysis and review of the role of varicocele repair. *Eur Urol* 60:796-808.