

# Torpedo Maculopathy: A Case Report of a 9-Year-Old Girl in Albania

Krasniqi M\*

Department of Medical Sciences, University Aleksander Moisiu, Durres, Mother Theresa Hospital, Albania

## Abstract

Torpedo maculopathy is a rare, congenital anomaly of the retinal pigment epithelium (RPE) which is characterized by the appearance of a 'torpedo-shaped' lesion located temporal to the fovea. In our case a 9 years old girl on her routine eye examination was discover to have a bilateral macular RPE defect with a pointed-oval shape directed toward the foveola and hyperpigmented. OCT and Foto fundus was done to the patient and diagnoses of torpedo maculopathy was made. Regular was recommended.

**Keywords:** Torpedo maculopathy; RPE defect; Albania; Case report

## Introduction

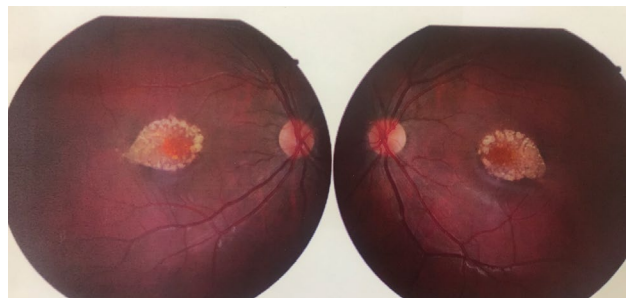
Torpedo maculopathy is a rare, congenital anomaly of the retinal pigment epithelium (RPE) which is characterized by the appearance of a 'torpedo-shaped' lesion located temporal to the fovea. It was first described by Roseman and Gass in 1992 as an asymptomatic 'hypopigmented nevus of the retinal pigment epithelium' [1].

In other cases, it has also been described as a paramacular coloboma [2], albinotic naevus, congenital hypo-melanotic freckle and subsequently, 'torpedo maculopathy' [3]. A diagnosis of torpedo maculopathy is typically made based on funduscopic appearance of the lesion.

Although the cause of torpedo maculopathy is unknown, optical coherence tomography (OCT) has provided insight into the structural and possible pathophysiologic changes associated with the lesion [4-6]. The OCT findings vary and may represent different stages of the condition. OCT images of eyes with torpedo maculopathy reveal an outer retinal and sub-retinal pigment epithelial 'cleft' with associated retinal pigment epithelial thinning that may be attributed to several developmental defects including a malformation of the horizontal raphe nerve fibers [3].

## Case Report

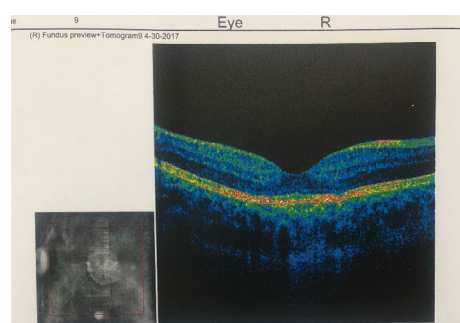
A 9-year-old girl with uncorrected 6/36 visual acuity was discovered on routine eye examination to have a macular RPE defect with a pointed-oval shape toward the foveola and hyperpigmented rounded margin on dilated fundus examination. The flat, nonpigmented lesion measured 2.5 mm horizontally and 1.5 mm vertically and was located 3 mm temporal to the optic disc. Optic nerve was flat, sharp and pink with normal physiologic cupping in each eye. The peripheral fundus was normal in both eyes with no holes, tears or detachments (Figure 1).



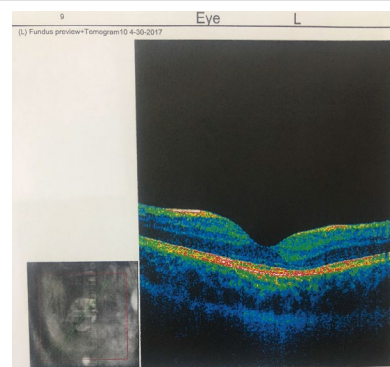
**Figure 1:** A 9-year-old girl with torpedo maculopathy in both eyes with a pointed-oval shape toward the foveola and hyperpigmented.

Visual acuity was 6/6 in the right and left eye with -2.50 spheres. Pupils were equal, round and reactive to light with no afferent pupillary defect. Ocular motilities were normal, and confrontation visual fields were unremarkable in both eyes. Laboratory findings for toxoplasmosis were negative.

OCT imaging revealed an area of mild retinal thinning in both eyes. The diagnosis of torpedo maculopathy was made and regular observation of the patient (Figures 2 and 3).



**Figure 2:** OCT of the right eye that shows a mild retinal thinning.



**Figure 3:** OCT of the left eye that shows a mild retinal thinning.

\*Corresponding author: Krasniqi M, Department of Medical Sciences, University Aleksander Moisiu, Durres, Mother Theresa Hospital, Albania, Tel: +355692633061; E-mail: [k\\_marsida@yahoo.it](mailto:k_marsida@yahoo.it)

Received April 26, 2018; Accepted May 05, 2018; Published May 18, 2018

**Citation:** Krasniqi M (2018) Torpedo Maculopathy: A Case Report of a 9-Year-Old Girl in Albania J Clin Case Rep 8: 1112. doi: [10.4172/2165-7920.10001112](https://doi.org/10.4172/2165-7920.10001112)

**Copyright:** © 2018 Krasniqi M. This is an open-access article distributed under the terms of the Creative Commons Attribution License, which permits unrestricted use, distribution, and reproduction in any medium, provided the original author and source are credited.

## Discussion and Conclusion

Torpedo maculopathy is a rare maculopathy that is often asymptomatic and typically found during routine examination. The condition is commonly unilateral, although bilateral cases have been reported [7,8], as it was in our case.

The etiology of torpedo maculopathy remains speculative and some have credited abnormal choroidal development or ciliary vasculature development leading to the localized, nonprogressive RPE lesion. The uniform location and size of this condition points toward a congenital defect at a precise time during fetal development of the RPE.

### References

1. Shields CL, Guzman JM, Shapiro MJ, Fogel LE, Shields JA (2010) Torpedo maculopathy at the site of the fetal "bulge". *Arch Ophthalmol* 128: 499-501.
2. Shields CL, Mashayekhi A, Ho T, Cater J, Shields JA (2003) Solitary congenital hypertrophy of the retinal pigment epithelium: clinical features and frequency of enlargement in 330 patients. *Ophthalmol* 110: 1968-1976.
3. Roseman RL, Gass JD (1992) Solitary hypopigmented nevus of the retinal pigment epithelium in the macula. *Arch Ophthalmol* 110: 1358-1359.
4. Daily MJ (1993) Torpedo maculopathy or paramacular spot syndrome. In *New dimensions in retina symposium* 11: 7.
5. Buzzonetti L, Petroni S, Catena G, Iarossi G (2015) Optical coherence tomography and electrophysiological findings in torpedo maculopathy. *Documenta Ophthalmologica* 130: 65-70.
6. Trevino R, Kiani S, Raveendranathan P (2014) The expanding clinical spectrum of torpedo maculopathy. *Optometry and Vision Science* 91: 71-78.
7. Rigotti M, Babighian S, De Prati EC, Marchini G (2002) Three cases of a rare congenital abnormality of the retinal pigment epithelium: torpedo maculopathy. *Ophthalmologica* 216: 226-227.
8. Dutra-Medeiros M, Leitão P, Magriço A, Toscano A (2013) Torpedo maculopathy with an anisometropic amblyopia in a 5-year-old Caucasian girl: A case report. *Arquivos brasileiros de oftalmologia* 76: 253-255.