

Thyroid Metastases from Renal Clear Cell Carcinoma Resected 9 Years Ago: A Fascinating Case Report and Review of Literature

Soumia Ayachi* and Achouak Bachir

Department of Oncology, Cancer Research Center of Batna, Algeria

Abstract

Introduction: Kidney cancer is relatively rare when compared to other malignancies. It accounts for approximately 3% of adult malignancies. The renal clear cell carcinoma (RCCC) is the most common. In 70% of cases the disease is confined to the kidney and surgical approaches are generally curative. One third of cases is discovered in metastatic stage (30% of cases), specially bone and lung metastases; however, other rare metastases sites have also been described.

Case report: We report a fascinating case of kidney cancer with thyroid metastases, discovered fortuitously during the surgical management of multinodular goitre; in a 54 years-old-woman with a history of nephrectomy 9 years ago for renal neoplasm.

Conclusion: Thyroid metastases of kidney cancer are uncommon, it's important for the surgeon and the oncologist to be able to recognize and differentiate thyroid metastases from primary tumours. The diagnosis can be suspected if the patient has a thyroid tumour and a past history of kidney cancer. These tumours, on the whole, tend to behave more aggressively and in most cases the use of multimodal therapy is recommended.

Keywords: Thyroid metastasis; Kidney neoplasms; Antigen CD10⁺

Introduction

Usually, thyroid gland represents a site of primary tumours; the four main types of this primary thyroid cancer are papillary, follicular, medullary and anaplastic thyroid cancer. However thyroid gland is a very rare site of clinically detectable tumour metastases, a same situation is a diagnosis dilemma because of similarity to malignant primary thyroid tumour.

Case Presentation

A 54-year-old woman with a history of left nephrectomy 9 years ago for renal clear cell carcinoma. The tumour was 60 mm in diameter and was localized in the upper pole of left kidney with adrenal and renal fascia involvement (Figure 1).

The tumour had been incidentally demonstrated on a routine ultrasonography (US). Preoperative whole body CT-Scan was negative for local and distant metastases. Histology examination has shown tumour extension into renal vein, renal fascia and the adrenal (pT3b pNx M0). The surgical margins were free of tumour.

The postoperative course was uneventful. Neither postoperative adjuvant treatment nor interferon were given 9 years later the patient presented a throat mass, the ultrasonography has demonstrated a large heterogeneous mass of 50/45 mm in left lobe of the thyroid without vascular involvement or lymph nodes. The thyroid balance has shown euthyroid.

The patient underwent subtotal thyroidectomy and the histology examination has shown an undifferentiated carcinoma very difficult to classify, related to a parathyroid carcinoma or a renal clear cell carcinoma taking as important consideration the patient's cancer history. The immunohistochemistry examination has demonstrated a negative staining to CK7 and positive staining to TTF1 as well as CD10 and vimentin (in 100% of the cellular population)

The radiologic investigation (whole body CT-Scan) has shown multiple spread lung metastasis (Figure 2) in various measures (between 7 and 36 mm).

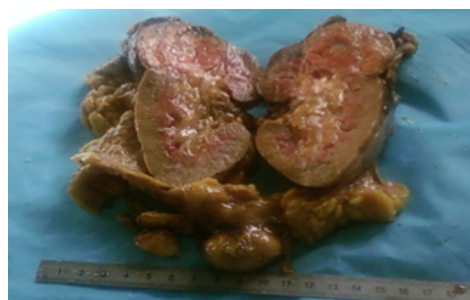


Figure 1: Macroscopic view of surgical specimen of nephrectomy.

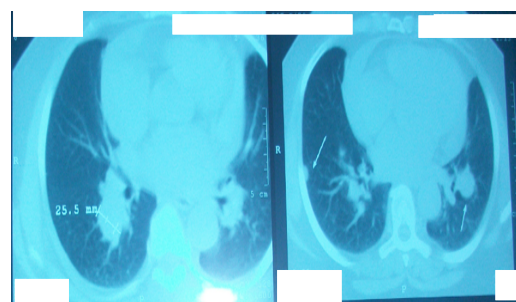


Figure 2: Horizontal view: spread lung metastasis in various diameters.

*Corresponding author: Soumia Ayachi, Department of Oncology, Cancer Research Center of Batna, Algeria, Tel: +213 33 98 07 47; E-mail: soumiayachi30@gmail.com

Received November 24, 2017; Accepted November 28, 2017; Published November 30, 2017

Citation: Ayachi S, Bachir A (2017) Thyroid Metastases from Renal Clear Cell Carcinoma Resected 9 Years Ago: A Fascinating Case Report and Review of Literature. J Mol Biomark Diagn 8: 365. doi: [10.4172/2155-9929.1000365](https://doi.org/10.4172/2155-9929.1000365)

Copyright: © 2017 Ayachi S, et al. This is an open-access article distributed under the terms of the Creative Commons Attribution License, which permits unrestricted use, distribution, and reproduction in any medium, provided the original author and source are credited.

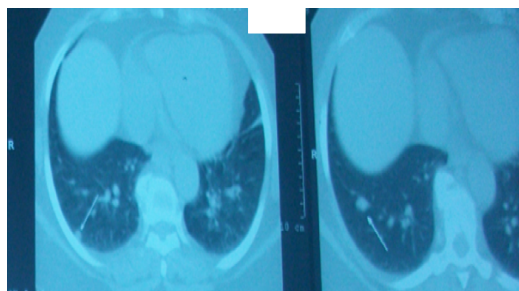


Figure 3: Horizontal view: persistence of basal spread metastasis which doesn't exceed 15 mm.

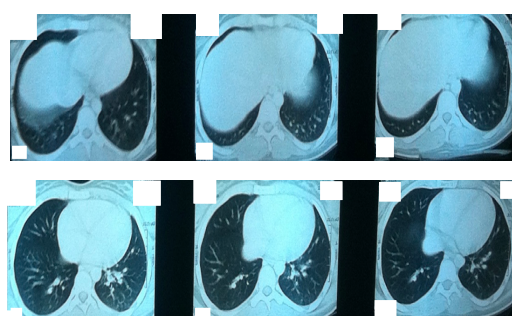


Figure 4: Horizontal view: disappearance of lung metastasis.

The patient has received a targeted therapy “Sunitinib” 50 mg/day 6 weeks on and 2 weeks off with a thyroid treatment substitution. Three 03 months later radiologic assessment by whole body CT-Scan (Figure 3) has shown a good response rate (number and size decline of lung metastases to 5-15 mm confined to the basal part of lungs) and tolerable adverse events (grade I asthenia and fatigue).

At present, the patient is disease-free of 25 months and actual radiologic assessment demonstrates disappearance of lung metastasis (Figure 4).

Discussion

The prevalence of intra thyroid metastases of solid tumours range from 1.9% to 25% [1-10], Mortensen et al. account 4% of patients with metastatic neoplasm with secondary tumours to the thyroid gland [11]. Silverberg found 25% on his autopsy series [12].

Usually, lung, kidney, breast and stomach are the most common tumours metastasizing to the thyroid [1-10]. In Shimaoka's study intra thyroid metastases occurred in 39% of melanoma patients, 21% of breast cancer patients, 12% of kidney cancer patients and 10% of lung or head and neck cancer [13].

However, the incidence of clinically significant metastases appears to be lower than the incidence found in autopsy. According to Shimaoka, the thyroid metastases were rarely clinically apparent in only 5% to 10% of the patients [13].

The physiopathogenesis explanation concerning intra thyroid metastases of kidney cancer is related to the renal cancer's venous tropism and thyroid hyper vascularisation [14].

Although, the presentation of a thyroid nodule or goitre years after the treatment of primary renal cancer often poses a diagnosis dilemma. Thyroid metastases are usually metachronous and rarely synchronous (there are some report about metastases which appeared prior to

the primary renal tumour being detected) [15,16] with an extremely variable delay onset from 1 month to 26 years (9.4 years as average) [17,18]. This case report which the patient presented a metachronous thyroid metastasis 9 years after is the confirmation. In similar situation, with a long period between the detection of the primary tumour and the development of thyroid metastases, the difficulty when making a correct diagnosis could increase as well [17].

In clinical practice, in a patient with a diffuse and bilateral multi nodular goitre a correct diagnosis is difficult. Since there are no specific findings of metastatic thyroid tumour on ultrasonography or computed tomography scan (CT-Scan) investigations [19]. Elliott and Frantz found 44 reported cases of metastatic carcinoma that had been misidentified as primary thyroid cancer [20].

Therefore, a correct diagnosis of metastatic thyroid tumours requires a careful consideration about patient's history of cancer. This information immediately stratifies a patient into a high risk category. So we have to respect the rule of “every thyroid nodule in neoplastic context is a metastasis until proof otherwise” [21].

In common, ultrasonography or CT-Scan demonstrates a voluminous heterogeneous lesion with necrosis or inflammation [19] like in the present case.

The fine needle aspiration (FNA) cytology is very specific and can allow the preoperative diagnosis, specially if the cancer is known. It is contributory in 80% of cases (nevertheless, the intra thoracic location can defeat this diagnosis tool) [21], but unfortunately our patient didn't undergo a fine needle aspiration which determines the treatment.

Once the diagnosis of metastatic disease has been confirmed on FNA, the patient should undergo a metastatic work-up to rule out other distant metastases [21]. For our patient thyroid metastasis was misdiagnosed by the surgeon and here thyroid mass was considered as a primary tumour that's why she underwent immediately to surgery.

Nevertheless, certainty diagnosis of thyroid metastases of renal clear cell carcinoma requires a histological examination and an immunohistochemistry test [22]. Commonly, histopathology examination shows nests and cords of large clear cells with abundant optically empty cytoplasm, sharply outlined boundaries and moderately atypical nuclei [23]. The tumors cells have a CD10, EMA and vementine positive staining on immunohistochemistry [21]. Doubtful pathology of surgical specimen of our patient led to necessary immunohistochemical test which has demonstrated a profile of a thyroid metastasis of renal clear cell carcinoma (100% of cells positive to CD10 and vementine).

Finally, if it's technically feasible, thyroidectomy can be effective for local control. Surgical resection is considered as the best treatment for a metastatic thyroid tumour, specially if the primary carcinoma appears to be controlled and there is no evidence of metastasis [17,24]. Moreover. According to Czech et al. loboisthmectomy is the best option and thyroidectomy would be required in order to treat tracheal compression [10]. For Mirailé et al. surgery is the best treatment in case of isolated thyroid metastases or other resectable metastases are associated [25]. Our patient underwent subtotal thyroidectomy despite she has lung metastases, because whole body CT-scan was demanded after surgery which reveal the importance of metastases assessment before surgery

The standard treatment of metastatic renal clear cell carcinoma is targeted therapy: tyrosine kinase inhibitor anti VEGF and anti VEGFR, but the value of this treatment in thyroid metastases was never evaluated because of the lack of cases identified through literature [26]. However,

after surgical management the administration of systemic therapy is recommended.

According Miraillé et al. the survival of patients with thyroid metastases was significantly better if the primary tumour is the kidney. Authors have demonstrated that for isolated thyroid metastasis, thyroidectomy has prolonged the overall survival in these patients. Complete resection of metastasis and a long delay between nephrectomy and metastases diagnosis predict a good prognosis with a survival of 7-22 years [27]. Chen et al. reported that 60% of the patients with solitary thyroid metastases were still alive after a thyroidectomy during a median follow-up period of 5.2 years [28]. In our case report, prognosis depends on lung metastases not in thyroid metastasis, although our patient is 25 months free-disease.

Conclusion

Thyroid metastases of kidney cancer are uncommon, it's important for the surgeon and the oncologist to be able to recognize and differentiate thyroid metastases from primary tumours. The diagnosis can be suspected if the patient has a thyroid tumour and a past history of kidney cancer. These tumours, on the whole, tend to behave more aggressively and in most cases the use of multimodal therapy is recommended.

References

- Ivy HK (1984) Cancer metastatic to the thyroid: A diagnostic problem. *Mayo Clin Proc* 59: 856-859.
- Hull OH (1955) Critical analysis of two hundred twenty-one thyroid glands; study of thyroid glands obtained at necropsy in Colorado. *AMA Arch Pathol* 59: 291-311.
- Lin JD, Weng HF, YS Ho (1998) Clinical and pathological characteristics of secondary thyroid cancer. *Thyroid* 8: 149-153.
- Akimaru K, Onda M, Tajiri T, Shimanuki K, Iwama H, et al. (2002) Colonic adenocarcinoma metastatic to the thyroid: Report of a case. *Surg Today* 32: 151-154.
- Rosen IB, Walfish PG, Bain J, Bedard YC (1995) Secondary malignancy of the thyroid gland and its management. *Ann Surg Oncol* 2: 252-256.
- Cichoń S, Anielski R, Konturek A, Barczyński M, Cichoń W (2006) Metastases to the thyroid gland: Seventeen cases operated on in a single clinical center. *Langenbecks Arch Surg* 391: 581-587.
- Lam KY, Lo CY (1998) Metastatic tumors of the thyroid gland: a study of 79 cases in Chinese patients. *Arch Pathol Lab Med* 122: 37-41.
- Nakhjavani MK, Gharib H, Goellner JR, Van Heerden JA (1997) Metastasis to the thyroid gland. A report of 43 cases. *Cancer* 79: 574-578.
- Wood K, Vini L, Harmer C (2004) Metastases to the thyroid gland: The Royal Marsden experience. *Eur J Surg Oncol* 30: 583-588.
- Czech JM, Lichter TR, Carney JA, Van Heerden JA (1982) Neoplasms metastatic to the thyroid gland. *Surg Gynecol Obstet* 155: 503-505.
- Mortensen J, Woolner LB, Bennett WA (1956) Secondary malignant tumors of the thyroid gland. *Cancer* 9: 306-309.
- Silverberg SG, Vidone RA (1966) Metastatic tumors in the thyroid. *Pacif Med Surg* 74: 175-180.
- Shimaoka K, Sokal JE, Pickren JW (1962) Metastatic neoplasms in the thyroid gland. Pathological and clinical findings. *Cancer* 15: 557-565.
- Benoit L, Favoulet P, Arnould L, Margarot A, Franceschini C, et al. (2003) Metastatic renal cell carcinoma to the thyroid gland: Report of seven cases and review of the literature. *Ann Chir* 129: 218-223.
- Méjean A, Lebert T (2008) Sites métastatique atypiques du cancer du rein. *Progrès en Urologie* 7: S320-S326.
- Lee HM, Kang HJ, Lee SH (2005) Metastatic renal cell carcinoma presenting as epistaxis. *Eur Arch Otorhinolaryngol* 262: 69-71.
- Douhib H, Ben AH, Daoud J, Frikha M, Charfeddine I, et al. (2009) Un cas de métastase intrathyroïdienne d'un primitive inhabituel. *Cancer Radiotherapy* 13: 213-215.
- Heffess CS, Wenig BM, Thompson LD (2002) Metastatic renal cell carcinoma to the thyroid gland. A clinical study of 36 cases. *Cancer* 1: 1869-1878.
- Wirtz G, Quoix E, Grunenberger F, Massard G, Mennecier B (2009) Métastase thyroïdienne d'un cancer bronchique et dysthyroïdie: à propos d'un cas. *Rev Pneumol Clin* 65: 27-31.
- Elliott RH, Frantz VK (1960) Metastatic carcinoma masquerading as primary thyroid cancer: A report of authors' 14 cases. *Ann Surg* 151: 551-561.
- Valo I, Verrièle V, Girraud P, Lorimier G, Guyétant S, et al. (2004) Métastases thyroïdiennes d'un corticosurrenalome 41 ans après le diagnostic de la tumeur initiale. *Ann Pathol* 24: 264-267.
- Kim T, Kim W, Ryu J, Gong G, Hong S, et al. (2005) 18F- fluorodeoxyglucose uptake in thyroid from positron emission tomogram for evaluation in cancer patients: High prevalence of malignancy in thyroid PET incidentaloma. *Laryngoscope* 115: 1074-1078.
- Dionigi G (2008) Solitary intrathyroidal metastases of renal clear cell carcinoma in a toxic substernal multinodular goitre. *Thyroid Res* 1:6.
- Rodier JF, Tuech JJ, Wilt M, Lindas P, Bruant-Rodier C (2008) Métastases intra thyroïdienne localement avancée d'un cancer bronchique. *Ann Otolaryngol Chir Cervicofac* 125: 198-203.
- Miraillé E, Rigaud J, Mathonnhet M, Gibelin H, Regenet N, et al. (2005) Management and prognosis of metastases to the thyroid gland. *J Am Coll Surg* 200: 203-207.
- Papi G, Carsello SM, Corrado S, Corrado S, Rossi ED, et al. (2007) Metastases to the thyroid gland: Prevalence, clinicopathological aspects and prognosis: A 10 years experience. *Clin Endocrinol (oxf)* 66: 565-571.
- Bakhos D, Lescanne E, Beutter P, Morinière S (2007) Métastase intrathyroïdienne d'un cancer renal. *Ann Otolaryngol chir cervicofac* 124: 301-304.
- Chen H, Nicol TL, Udelsman R (1999) Clinically significant, isolated metastatic disease to the thyroid gland. *World J Surg* 23: 177-181.