

Three-Dimensional High-Definition Laparoscopic Treatment of Dunbar Syndrome (Celiac Axis Compression by Median Arcuate Ligament Hypertrophy) With Intra-Operative Laparoscopic Duplex Ultrasound Evaluation: Report of Two Cases

Piera Leon*, Pierluigi Angelini, Stefano Reggio, Antonio Sciuto, Francesco Esposito and Francesco Corcione

Azienda Ospedaliero-Universitaria di Trieste, Cattinara Hospital, Italy

Abstract

Introduction: Dunbar syndrome consists in a rare vascular disorder characterized by extrinsic compression of the celiac artery. This mechanic compression results in symptoms related to intermittent mesenteric ischemia. The goal of treatment is to release celiac artery compression and to restore vessel patency. Here we report two cases treated in our Surgical Department over the last four years.

Case Report: A young female of 28 years-old, L.P., and 57-year-old men, E.G., both affected by recurrent post-prandial diffuse abdominal pain, diarrhea and weight loss came to our observation. A complete abdominal evaluation associated to radiologic exams made the diagnosis of CAC syndrome. Both patients were referred to a 3D laparoscopic surgical treatment of CACS with release of the median arcuate ligament. Vessels patency was checked intra-operatively using ecolaparoscopy.

Conclusion: Median arcuate ligament section is the treatment of choice in Dunbar Syndrome, a rare vascular syndrome caused by extrinsic compression of the celiac trunk by a lower-inserted muscular bridge that connects the two crura of the diaphragm and crosses over the abdominal aorta. Minimally invasive 3D laparoscopic approach is ideal to treat Dunbar syndrome for the high definition and magnification of the 3D visualization. We perform an intraoperative laparoscopic duplex ultrasound investigation in the initial phase of the operation and at the conclusion of the procedure to assess the effectiveness of the treatment.

Keywords: Dunbar syndrome; Median arcuate ligament (MAL) syndrome; Celiac artery compression syndrome (CACS); Vascular disorder; Ecolaparoscopy; Three-dimensional laparoscopy

Introduction

Dunbar syndrome or median arcuate ligament (MAL) syndrome, also known as the celiac artery compression syndrome (CACS), consists in a rare vascular disorder characterized by extrinsic compression of the celiac artery. This mechanic compression results in symptoms related to intermittent mesenteric ischemia as post-prandial and post-exercise abdominal pain, vomiting and unintentional weight loss in the long period. Uncommon mild presentations are likely gastropathy, peptic ulcer disease and not specified anemia. In CACS, symptoms are nonspecific and misdiagnosis is easy to achieve.

The goal of treatment is to release celiac artery compression and to restore vessel patency. Poor short- and long-term results have been reported in the literature performing endovascular methods only (restenosis after angioplasty alone, stent slippage, etc.), while surgery with external tissue compression debridement can provide better outcomes.

We report our experience on two clinical cases, undergone 3D laparoscopic surgical resection of the arcuate ligament with release of fibrotic tissue surrounding the celiac plexus.

Case Reports

Case 1

A young female of 28 years-old, L.P., affected by beta thalassemia minor, with no significant medical history and no previous abdominal surgery, came to our observation complaining of recurrent post-prandial diffuse abdominal pain, diarrhea and 7 kg weight loss (12% of her

initial body weight) over the last four months. The preliminary abdominal examination revealed no notable findings. She started investigations performing complete blood tests, ANA and ANCA antibodies and those for celiac disease, fecal occult blood assay: a mild anemia (Hb 10.2 g/dL) emerged among all these tests. She underwent an upper gastro-intestinal endoscopy, a colonoscopy and radiography of the bowel with no pathologic findings. An abdominal Ultrasound was then performed and a suspicion of CAC syndrome emerged. So a MRI angiography of the abdomen was required and this exam showed a significant stenosis of the origin of the celiac trunk given by a low and hypertrophic insertion of the arcuate ligament of diaphragm associated to the presence of post-stenotic flow (Figure 1).

An abdominal Duplex Ultrasound was obtained in both supine and orthostatic position and during deep inhalation and exhalation: an acceleration of blood flow through the stenosis was recorded during orthostatic position and deep inhalation. These findings confirmed the role of muscular ligament compression of the vessel in the pathogenesis of CACS. This young patient was referred to a laparoscopic surgical treatment of CACS with release of the median arcuate ligament (Figure 2).

*Corresponding author: Piera Leon, Azienda Ospedaliero-universitaria di Trieste, Cattinara Hospital, Italy, Tel: +39 040 399 1111; E-mail: pieraleon5@gmail.com

Received March 21, 2016; Accepted June 20, 2016; Published June 26, 2016

Citation: Leon P, Angelini P, Reggio S, Sciuto A, Esposito F, et al. (2016) Three-Dimensional High-Definition Laparoscopic Treatment of Dunbar Syndrome (Celiac Axis Compression by Median Arcuate Ligament Hypertrophy) With Intra-Operative Laparoscopic Duplex Ultrasound Evaluation: Report of Two Cases. J Clin Case Rep 6: 808. doi:10.4172/2165-7920.1000808

Copyright: © 2016 Leon P, et al. This is an open-access article distributed under the terms of the Creative Commons Attribution License, which permits unrestricted use, distribution, and reproduction in any medium, provided the original author and source are credited.

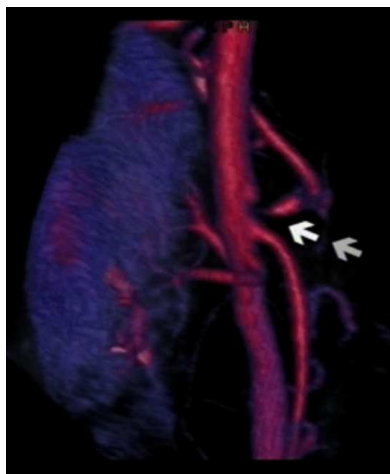

Figure 1: AngioRM 3D-reconstruction image showing compression of the celiac axis by the median arcuate ligament hypertrophy.

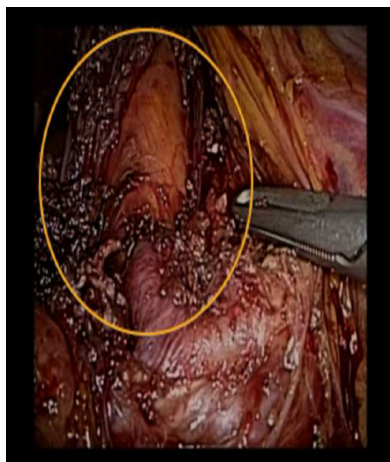


Figure 2: Intra-operative image showing the complete release of MAL, then evaluated using Laparoscopic Duplex Ultrasound evaluation.

Case 2

57-year-old men E.G., with a medical history of dyslipidemia, high arterial blood pressure and previous smoking, presented to the clinical attention complaining of post-prandial and post-heavy physical exercise abdominal pain lasting 30-60 minutes, associated to nausea and vomiting. He declared 8 kg weight loss over the last 6 months and two admissions to hospital with no clear diagnosis and no resolutions of symptoms. During hospitalization he underwent high and low digestive tract endoscopy that revealed a moderate gastropathy with no peptic ulcers and normal colonic mucosa. High dose anti-acid medication was given with no symptoms relief. Afterwards, he underwent an abdominal Ultrasound that revealed a dilatation of the distal aorta. An Echocardiography and an abdominal AngioTC (Computer Tomography) were performed to study the vascular tree and the latter showed a focal stenosis of the celiac artery by the extrinsic tissues (no atherosclerotic plaque of the vascular wall was visible in that site), also confirming the presence of a 37 mm abdominal aortic aneurism. A focused upper abdominal Duplex Ultrasound was then performed and revealed celiac artery stenosis with an increased blood flow during expiration and a reduction during inspiration. We therefore propose

this patient for a laparoscopic surgical division of the median arcuate ligament.

Operative Technique

The same laparoscopy-experienced surgeon performed both the operations. Patients were placed in supine split-leg position and the surgeon was standing between the legs as in the French approach; a mild anti-Trendelenburg bed position was achieved and during the operation a slightly lateral rotation to the left or to the right was used to improve visualization. After the induction of anesthesia, a bladder catheter and a nasogastric tube were placed. The operative field included the area within mammillary line and pubis. Two video monitors were placed in the cranial edge of the operating table. Pneumoperitoneum was induced through a Veres-assisted open technique. Veres needle was placed through the abdomen wall in the left subcostal space, in the so-called Palmer point, and as far as peritoneal cavity pressure reaches 10-12 mmHg, a CO₂ aspiration tests with a saline-filled syringe is performed to check for adhesions-free area where we want to insert the first optical trocar. In both cases the optical trocar of 10-12 mm (T1) was introduced along the mid line, in an intermediate position between the umbilicus and xiphoid. A flexible 3D laparoscope was used to perform the operation. Under vision we proceeded to Veres extraction and to introduce other four ports. Second (T2) and third (T3) operator trocar of 10-12 mm were placed along respectively the left and right mid-clavicular lines, just cephalic to the level of the optical trocar. A fourth 5 mm trocar (T4) for the assistant was allocated in the left para-xiphoid area and a fifth trocar (T5) in the left paraumbilical space between T1 and T2 (Figure 2). Dissection was performed with the harmonic scalpel and hemostasis was controlled using bipolar forceps.

We performed an antegrade dissection consisting of the following steps: first we divided pars flaccida of the gastro-hepatic ligament, preserving Latarjet vagal fibers; the right crus of the diaphragm can be easily identified inferiorly to the cardia. To gain a better exposure of the aortoceliac region, the stomach was retracted to the left by the grasper introduced through T5; lowering the small gastric curvature allows the identification of the left gastric artery and the isolation of the proximal segment of the coeliac trunk flattened by the fibers of the arcuate ligament. We then performed an intraoperative Duplex Ultrasound to evaluate vascular stenosis (revealed by a sectorial acceleration of the blood flow at the celiac artery associated to a post-stenotic pattern flow in the main vascular branches) and the pathophysiological external compression. The dissection was then conducted behind the esophagus, where the muscular fibers of the crura were identified and divided with harmonic scalpel to expose the anterior surface of the aorta. Fibrotic tissue around the ligament was completely removed and procedure ended when the origin of the CA was free of any external stricture. The effectiveness of the operation was confirmed performing an intra-operative Duplex Ultrasound that showed in both cases a wide vessel lumen with resolution of stenosis. One drain was positioned in the operative zone. No conversion to open technique occurred. Mean operative time was 40 minutes and there wasn't any relevant blood loss in both the operations.

Postoperative and Follow-Up

Patients did not require additional analgesia other than given by the elastomeric pump (60 mg ketorolac and 200 mg tramadol-filled) for the first 24 hours.

The restore of flatus occurred within the first 24 hours; patients returned to the oral intake of semi-liquid food in the first post-operative

day and both were discharged on the second postoperative day. Return to normal activities was rapid, respectively 5 and 7 days.

Control visits were planned after 7 and 30 days: both patients did not complain about upper abdominal pain or vomiting and both gained weight (0.6 kg and 0.8 kg respectively after one month). No complications occurred to the surgical wounds.

Two months afterwards patient L.P. practiced CT angiography with iodinated contrast, which confirmed persistence of normal patency of the celiac trunk and its branches (Figure 3). After six months from surgery, still without symptoms, she underwent an abdominal Duplex Ultrasound that showed a normal pattern of celiac flow.

The other patient, E.G., was referred to perform an abdominal Duplex ultrasound after two months from treatment, which confirmed the good result of operation with complete vessel patency.

Discussion

First reported by Lipshutz in 1917 as anatomical CA compression, CACS (Celiac Axis Compression Syndrome) was associated to a clinical syndrome in 1963 by Harjola and in 1965 by Dunbar [1,2]. It is due to the anomalous lower insertion of the median arcuate ligament (MAL), from T11 to L1, or to a superior origin of the CA. MAL is a prominent fibrous arch that connects the right and left crura and normally cross over the aorta cephalic to the celiac artery origin: during deep inspiration and erect position compression is increased, the opposite happens during expiration. The celiac autonomic nerve plexus of the upper abdominal organs, moreover, lay close to MAL [3].

The so-called Dunbar syndrome is characterized by chronic intermittent abdominal pain, often post-prandial, associated with bloating, vomiting and weight loss. Sometimes an epigastric bruit can be auscultated [4-6].

Pathophysiology of this syndrome is still under debate: some authors advocate an “ischemic theory”, describing a state of mesenteric ischemia due to physical compression of the celiac artery or to post-prandial stretching phenomenon caused by collaterals of superior mesenteric artery. However, isolated vascular compression of the celiac artery do not completely explain the syndrome. It’s believed, in fact, that a normal superior mesenteric artery would compensate for celiac artery compression. So the “neurogenic theory” was introduced:

the compression of the celiac ganglion fibers along with the artery could cause neurogenic pain and splanchnic vasoconstriction [7-9]. Performing a celiac ganglionectomy associated with MAL division should relieve symptoms, especially when compared to percutaneous transluminal angioplasty alone [10,11].

Diagnosis is not so easy to achieve because symptoms are non-specific and usually it’s made by exclusion. Abdominal Ultrasound, gastroscopy and gastric emptying radiographic studies are usually performed to rule out other causes of pain. A good-quality abdominal vascular-focused Duplex Ultrasound, an angioTC, a MRI or a splanchnic vessels angiography can highlight CA compression. Associated to one of these imaging modalities, a gastric tonometry can confirmed the presence of Dunbar Syndrome [11,12].

Mensink et al. using tonometry for diagnosis demonstrated the presence of gastric mucosal ischemia and low pH secretions in patients affected by MALS prior to treatment; all these features normalized after the treatment: this functional evaluation showed to be accurate in detecting CACS with a sensitivity of 77% and a specificity of 94% [13]. Our patients did not undergo gastric tonometry and pH measurements for diagnosis’s confirmation, both presented peculiar variations of the CA flow during inspiration/expiration performing abdominal Duplex Ultrasound.

We recommend to refer to a detailed diagnostic workup patients complaining for months about nausea, vomiting, diarrhea, post-prandial pain and weigh loss with no clear pathogenic definition after clinical investigations and routine endoscopic and radiological exams, in particular if the patient present with a vascular murmur on auscultation of the abdomen [14].

Two are the main treatment modalities to approach Dunbar syndrome: endovascular, surgical or even both. Endovascular balloon dilatation followed by stent placement for CACS has shown high mechanical and long-term failure rates. This is likely due to the fact that CACS results in extrinsic compression of the celiac artery [15,16]. A variety of vascular surgical procedures have been proposed: decompression of the constricting external fibers, reconstruction of the tract or even bypass of the compressed segment of celiac artery: the overall success of decompression of the celiac artery ranges between 60-87% [17,18].

The most effective treatment is surgical and consists in sectioning MAL and fibrotic tissue around the celiac axis. No substantial differences were highlighted between open and laparoscopic approach [19]. A minimally invasive 3D laparoscopic approach is ideal for this procedure: the high definition and magnification of the 3D visualization allow better instrument maneuverability gaining in precision, in a confined space such as the esophago-gastric junction, with results comparable to those of robotic surgery with lower operating time and lower costs [20-22]. Intraoperative Duplex ultrasonography has been showed to be a valid tool to check intra-operatively the effectiveness of surrounding tissue removal [23].

If the syndrome persist after the section of the arcuate ligament, probably the chronic presence of constriction together with the production of reactive fibrotic tissue in that site has stabilized vessel changes that do not regress despite the surgical removal of the extrinsic compression. In such cases, an associated procedure is required, like performing a celiac-artery angioplasty with or without a stent placement or positioning a by-pass graft, with variable long-term results [24].

Intraoperative Duplex Ultrasound in both of our cases, performed in the end of the operation, attested the normalization of the blood flow

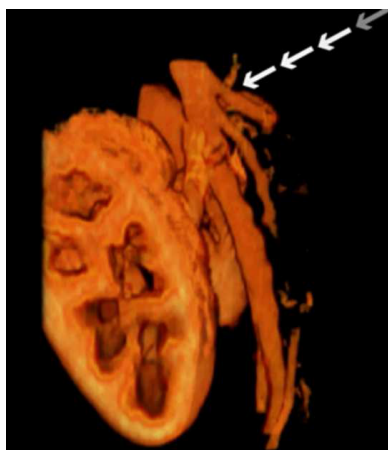

Figure 3: Angio TC 3D-reconstruction image showing the complete celiac artery patency after two months from the operation.

and the resolution of the compression, so it wasn't necessary to proceed further. Series published in literature underline the importance of an early diagnosis and a rapid removal of the cause of stenosis, before the stabilization of fibrosis occur, to improve treatment success rates [14].

Conclusion

Median arcuate ligament section is the treatment of choice in Dunbar Syndrome, a rare vascular syndrome caused by extrinsic compression of the celiac trunk by a lower-inserted muscular bridge that connects the two crura of the diaphragm and crosses over the abdominal aorta. Symptoms are non-specific and diagnosis is challenging, often reached by exclusion. Minimally invasive 3D laparoscopic approach is ideal to treat Dunbar syndrome: the high definition and magnification of the 3D visualization allow a better instrument maneuverability in a confined space such as the esophago-gastric junction, with results comparable to those of robotic surgery with lower operating time and lower costs.

We recommend, as done in both our patients, to perform an intraoperative laparoscopic duplex ultrasound investigation in the initial phase of the operation and at the conclusion of the procedure to assess the effectiveness of the treatment: this, in order to assess the normalization of the blood flow at the celiac artery after the section of the arcuate ligament and the debridement of fibrosis of the celiac ganglion, if present. If intraoperative duplex ultrasound doesn't show any change in celiac blood flow, as a consequence of a chronic fibrotic stricture, it would be necessary to continue debridement or to associate closely other procedures to solve the stenosis as endovascular stenting or vascular by-pass able to restore adequate vessel patency.

References

1. Harjola PT (1963) A Rare Obstruction of the coeliac artery. Report of a case. *Ann Chir Gynaecol Fenn* 52: 547-550.
2. Dunbar JD, Molnar W, Beman FF, Marable SA (1965) Compression of the celiac trunk and abdominal angina. *Am J Roentgenol Radium Ther Nucl Med* 95: 731-744.
3. Loukas M, Pinyard J, Vaid S, Kinsella C, Tariq A, et al. (2007) Clinical anatomy of celiac artery compression syndrome: a review. *Clin Anat* 20: 612-617.
4. Vaziri K, Hungness ES, Pearson EG, Soper NJ (2009) Laparoscopic treatment of celiac artery compression syndrome: case series and review of current treatment modalities. *J Gastrointest Surg* 13: 293-298.
5. Karavelioğlu Y, Kalçık M, Sarak T (2015) Dunbar syndrome as an unusual cause of exercise-induced retrosternal pain. *Türk Kardiyol Dern Ars* 43: 465-467.
6. di Libero L, Varricchio A, Tartaglia E, Iazzetta I, Tartaglia A, et al. (2013) Laparoscopic treatment of celiac axis compression syndrome (CACS) and hiatal hernia: Case report with bleeding complications and review. *Int J Surg Case Rep* 4: 882-885.
7. Bobadilla JL (2013) Mesenteric ischemia. *Surg Clin North Am* 93: 925-940, ix.
8. Wolfman D, Bluth EI, Sossaman J (2003) Median arcuate ligament syndrome. *J Ultrasound Med* 22: 1377-1380.
9. Gloviesky P, Duncan AA (2007) Treatment of celiac artery compression syndrome: does it really exist? *Perspect Vasc Surg Endovasc Ther* 19: 259-263.
10. Kotarać M, Radovanović N, Lekić N, Ražnatović Z, Djordjević V, et al. (2015) Surgical treatment of median arcuate ligament syndrome: case report and review of literature. *Srp Arh Celok Lek* 143: 74-78.
11. Grottemeyer D, Duran M, Iskandar F, Blondin D, Nguyen K, et al. (2009) Median arcuate ligament syndrome: vascular surgical therapy and follow-up of 18 patients. *Langenbecks Arch Surg* 394: 1085-1092.
12. Erden A, Yurdakul M, Cumhur T (1999) Marked increase in flow velocities during deep expiration: A duplex Doppler sign of celiac artery compression syndrome. *Cardiovasc Intervent Radiol* 22: 331-332.
13. Mensink PB, van Petersen AS, Kolkman JJ, Otte JA, Huisman AB, et al. (2006) Gastric exercise tonometry: the key investigation in patients with suspected celiac artery compression syndrome. *J Vasc Surg* 44: 277-281.
14. Duffy AJ, Panait L, Eisenberg D, Bell RL, Roberts KE, et al. (2009) Management of median arcuate ligament syndrome: a new paradigm. *Ann Vasc Surg* 23: 778-784.
15. Kohn GP, Bitar RS, Farber MA, Marston WA, Overby DW, et al. (2011) Treatment options and outcomes for celiac artery compression syndrome. *Surg Innov* 18: 338-343.
16. Baldassarre E, Torino G, Siani A, Barone M, Valenti G (2007) The laparoscopic approach in the median arcuate ligament syndrome: report of a case. *Swiss Med Wkly* 137: 353-354.
17. Estraviz B, Arévalo JA, Eizaguirre E, Jiménez E, Corcostegui M, et al. (2012) Laparoscopic approach for the multiple abdominal vascular entrapment syndrome. *Hepatogastroenterology* 59: 175-177.
18. Delis KT, Glovicski P, Altuwajri M, McKusick MA (2007) Median arcuate ligament syndrome: open celiac artery reconstruction and ligament division after endovascular failure. *J Vasc Surg* 46: 799-802.
19. Jimenez JC, Harlander-Locke M, Dutson EP (2012) Open and laparoscopic treatment of median arcuate ligament syndrome. *J Vasc Surg* 56: 869-873.
20. Carbonell AM, Kercher KW, Heniford BT, Matthews BD (2005) Multimedia article. Laparoscopic management of median arcuate ligament syndrome. *Surg Endosc* 19: 729.
21. Meyer M, Gharagozloo F, Nguyen D, Tempesta B, Strother E, et al. (2012) Robotic-assisted treatment of celiac artery compression syndrome: report of a case and review of the literature. *Int J Med Robot* 8: 379-383.
22. Do MV, Smith TA, Bazan HA, Sternbergh WC 3rd, Abbas AE, et al. (2013) Laparoscopic versus robot-assisted surgery for median arcuate ligament syndrome. *Surg Endosc* 27: 4060-4066.
23. Roayale S, Jossart G, Gitlitz D, Lamparello P (2000) Laparoscopic release of celiac artery compression syndrome facilitated by laparoscopic ultrasound scanning to confirm restoration of flow. *J Vasc Surg* 32: 814-817.
24. Palmer OP, Tedesco M, Casey K, Lee JT, Poultsides GA (2012) Hybrid treatment of celiac artery compression (median arcuate ligament) syndrome. *Dig Dis Sci* 57: 1782-1785.