

Case Report

Open Access

The Size and Number is Not Everything to Evaluate the Tumor Response

Erdem Sen*

Department of Medical Oncology, Selcuk University, Konya, Turkey

Abstract

Gastrointestinal stromal tumors are the most common mesenchymal tumors of the gastrointestinal tract. Contrast-enhanced computed tomography is the most commonly used for evaluating response to treatment. Targeted therapies may cause some changes in tumor structure. Reduced lesion vascularity, cavitations, and intratumoral hemorrhage are some changes in patients after imatinib therapy, even without any size reduction. Paradoxically, a transient increase in size may be seen in some cases due to cystic change and intratumoral hemorrhage. Alternative tumor response criteria were developed by Choi et al. in gastrointestinal stromal tumor. They showed that not only the tumor size but also the tumor density are important in evaluating the response. In the present study, we report a 67-year old man who had been diagnosed with the gastrointestinal stromal tumor and treated with imatinib. After 3 months of imatinib treatment, liver lesions reported progression in response assessment.

Keywords: Gastrointestinal stromal tumor; Imatinib; Choi criteria

Abbreviations: GIST: Gastrointestinal Stromal Tumor; GI: Gastrointestinal; CT: Computed Tomography; PET: Positron Emission Tomography; FDG: Fluorodeoxyglucose

Introduction

Gastrointestinal stromal tumor (GIST) is one of the most common soft tissue sarcoma subtypes; each year ~3,300-6,000 new cases are diagnosed [1,2]. GIST is usually seen in middle age and elderly patients, with ~60% located in the stomach, 30% in the small intestine, and 10% in other regions of the gastrointestinal (GI) tract [3]. Size, mitotic rate, and location of the primary lesion are the most important prognostic factors [4]. GIST may be increased in size during treatment because of intratumoral hemorrhage or myxoid degeneration. Decreasing in tumor density on computed tomography (CT) is an important early clinical marker of antitumor activity. Once tumors become hypodense (cystic), the size of the lesions may decrease slowly and eventually stabilize [5,6]. Responses can be observed within 24 hours of starting therapy on PET-CT [7].

Case Report

The 67-year-old male patient was admitted to our hospital to determine the cause of anemia. Heterogeneously enhancing solid mass (11 cm × 17 cm) revealed in the pelvic region and multiple metastatic lesions in the liver were determined on abdominal CT (Figures 1 and 2).

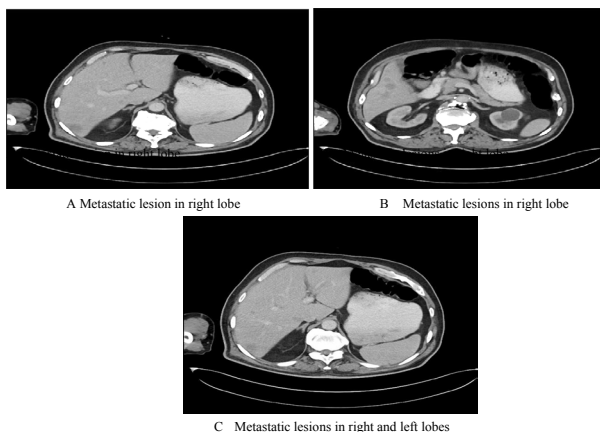

Figure 1: Multiple metastatic lesions are seen in left and right lobes of the liver. Before starting treatment of imatinib. A, B: Metastatic lesions in right lobe. C: Metastatic lesions in right and left lobes.

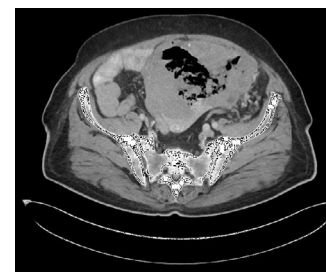


Figure 2: Heterogeneous mass (11 cm × 17 cm) in the pelvic region of abdomen. The mass was originated from ileum. GIST was diagnosed by biopsy in this primary lesion. (Before starting Imatinib treatment).

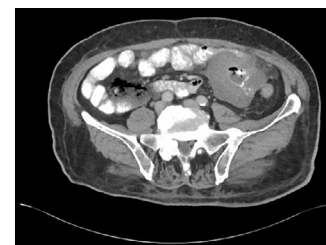

Figure 3: The primary, heterogeneous mass dimensions have decreased (7 cm × 7.5 cm). Tumor has partial response according to RECIST criteria. (After three months of the imatinib treatment).

The mass was originated from the ileum. GIST was diagnosed as a result of the biopsy of the abdominal mass and liver. Imatinib therapy (400 mg/day) was started. After 3 months of imatinib treatment thoracic and abdominal CT scans were taken. The mass in the pelvic area measured 7 cm × 7.5 cm (Figure 3). However, in the liver parenchyma, metastatic lesions were reported as progression by the department of radiology according to RECIST 1.1 criteria (Table 1) (Figure 4). In PET-CT

***Corresponding author:** Sen Erdem, Department of Medical Oncology, Selcuk University, Konya, Turkey, Tel: +903322244085; Fax: +903322416065; E-mail: dr17erdem@mytel.com

Received January 18, 2018; **Accepted** March 02, 2018; **Published** March 05, 2018

Citation: Sen E (2018) The Size and Number is Not Everything to Evaluate the Tumor Response. J Clin Case Rep 8: 1082. doi: [10.4172/2165-7920.10001082](https://doi.org/10.4172/2165-7920.10001082)

Copyright: © 2018 Sen E. This is an open-access article distributed under the terms of the Creative Commons Attribution License, which permits unrestricted use, distribution, and reproduction in any medium, provided the original author and source are credited.

Response assessment	RECIST, version 1.1
	Target lesions
CR	Disappearance of all target lesions and reduction in the short axis measurement of all pathologic lymph nodes to ≤10 mm
PR	≥ 30 percent decrease in the sum of the longest diameter of the target lesions compared with baseline
PD	≥ 20 percent increase of at least 5 mm in the sum of the longest diameters of the target lesions compared with the smallest sum of the longest diameter recorded OR The appearance of new lesions, including those detected by FDG-PET
SD	Neither PR nor PD

CR: Complete Response; PR: Partial Response; PD: Progressive Disease; FDG-PET: Fludeoxyglucose-Positron Emission Tomography; SD: Stable Disease.

Table 1: Response evaluation criteria in Solid Tumors (RECIST) version 1.1.

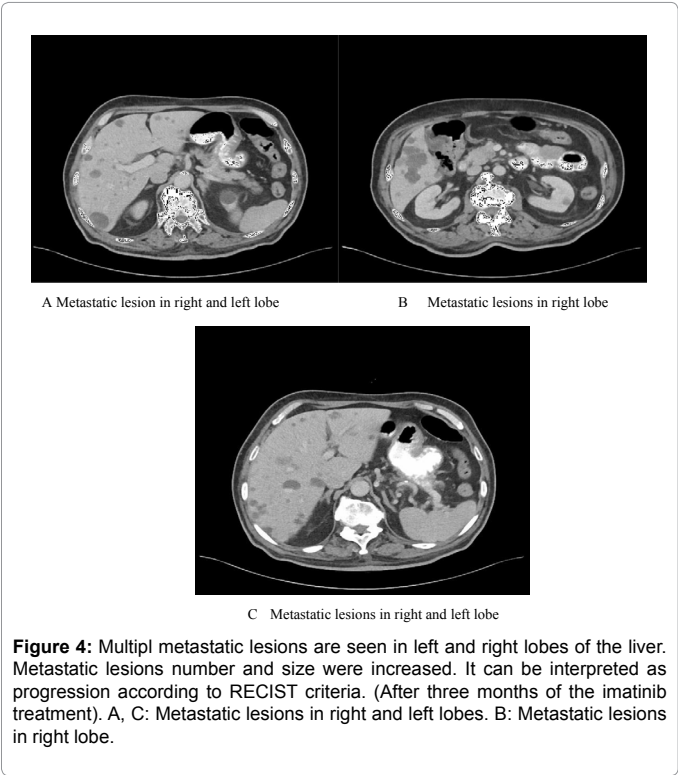


Figure 4: Multipl metastatic lesions are seen in left and right lobes of the liver. Metastatic lesions number and size were increased. It can be interpreted as progression according to RECIST criteria. (After three months of the imatinib treatment). A, C: Metastatic lesions in right and left lobes. B: Metastatic lesions in right lobe.

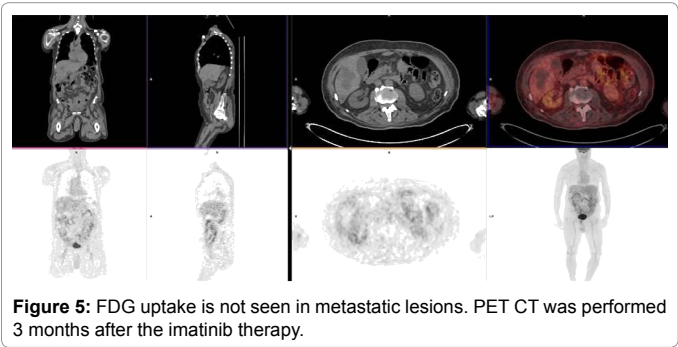


Figure 5: FDG uptake is not seen in metastatic lesions. PET CT was performed 3 months after the imatinib therapy.

examination there were multiple hypodense lesions in the liver with no FDG uptake (Figure 5). Abdominal CT examination was re-evaluated by Choi criteria (Table 2) (Figures 6-8). And then compared tumor density findings was compatible with the partial response. At this time

Response assessment	Choi criteria
CR	Disappearance of all lesions No new lesions
PR	A decrease in size ≥ 10 or a decrease in tumor attenuation (HU) ≥ 15 on CT No new lesions No obvious progression of non-measurable disease
PD	An increase in tumor size ≥ 10 and does not meet criteria of PR by tumor attenuation on CT New lesions
SD	Does not meet the above criteria

CR: Complete Response; PR: Partial Response; PD: Progressive Disease; SD: Stable Disease; CT: Computed Tomography

Table 2: Choi criteria.

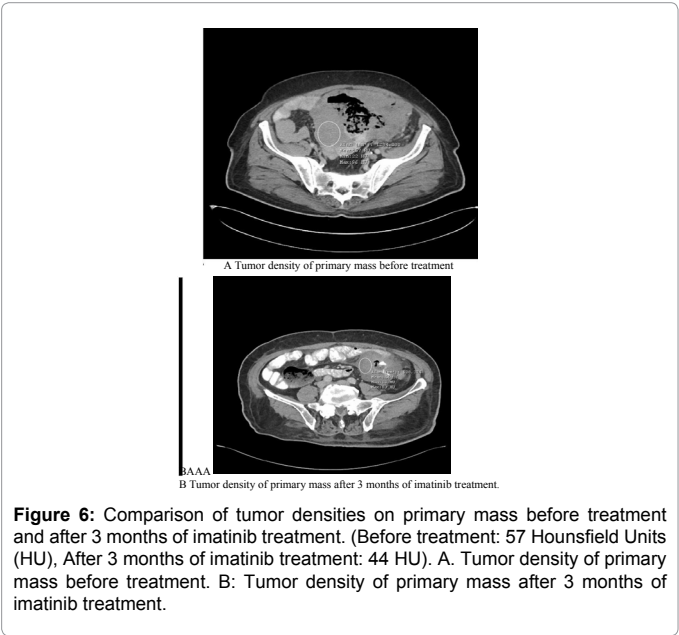


Figure 6: Comparison of tumor densities on primary mass before treatment and after 3 months of imatinib treatment. (Before treatment: 57 Hounsfield Units (HU), After 3 months of imatinib treatment: 44 HU). A. Tumor density of primary mass before treatment. B: Tumor density of primary mass after 3 months of imatinib treatment.

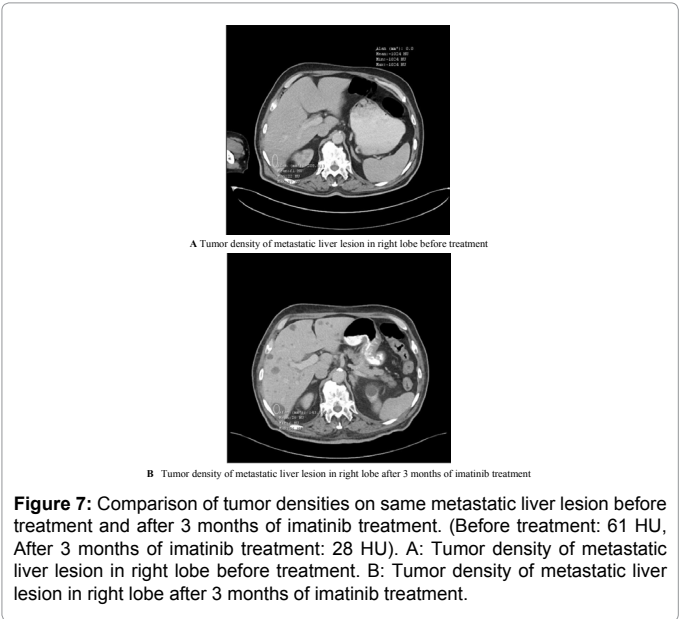
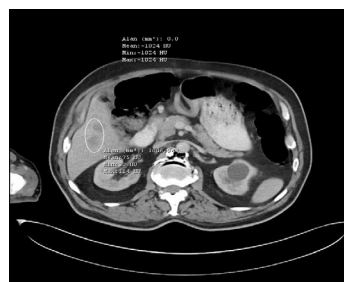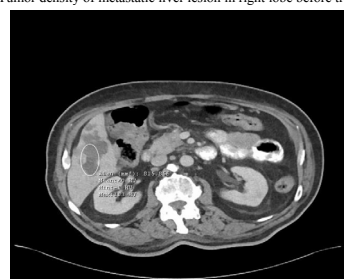


Figure 7: Comparison of tumor densities on same metastatic liver lesion before treatment and after 3 months of imatinib treatment. (Before treatment: 61 HU, After 3 months of imatinib treatment: 28 HU). A: Tumor density of metastatic liver lesion in right lobe before treatment. B: Tumor density of metastatic liver lesion in right lobe after 3 months of imatinib treatment.

imatinib therapy (400 mg/day) is still ongoing. There is no disease progression for 10 months. Stable disease is going on.



A: Tumor density of metastatic liver lesion in right lobe before treatment



B: Tumor density of metastatic liver lesion in right lobe after 3 months of imatinib treatment

Figure 8: Comparison of tumor densities on same metastatic liver lesion before treatment and after 3 months of imatinib treatment. (Before treatment: 75 HU, After 3 months of imatinib treatment: 40 HU). A: Tumor density of metastatic liver lesion in right lobe before treatment. B: Tumor density of metastatic liver lesion in right lobe after 3 months of imatinib treatment.

Discussion

In metastatic GIST; There are differences for evaluating treatment response compared to other solid tumors. For example, late response may occur who have stable disease. A clinical trial performed by Verweij et al. demonstrated that the median time of objective response is four months, a maximal response may be in six months or even longer [8]. In clinical trials performed that PET-CT is able to show an earlier response than CT [9,10]. Treglia et al., demonstrated that PET-CT has a significant value in assessing treatment response in GIST. This modality allows an early evaluation of treatment response and is a strong predictor of clinical outcome [11]. Alternative response assessment criteria (Choi criteria) have been developed in GIST. Investigators at MD Anderson reported that Choi criteria are a better predictor of response to therapy than standard RECIST criteria. Also, they showed that 10 percent decrease in unidimensional tumor size or a 15 percent decrease in tumor density on contrast-enhanced CT scans (Partial response) correlates well with PET scan findings (Table 2) [12,13]. Fluid retention is a common side effect of imatinib therapy. Treatment-related fluid retention may be seen as ascites, a pleural effusion, a pericardial effusion, or extensive subcutaneous edema. New ascites or effusions noted on CT scans can be mistakenly regarded as a new finding of peritoneal disease when the disease is otherwise stable or resolving. This is an important consideration in evaluating the response [14].

Conclusion

Tumoral lesions may enlarge paradoxically during treatment in GIST. These enlargements can be due to the development of intratumoral hemorrhage or myxoid degeneration. Enlargement of the tumor does not indicate progression. Also at the beginning, uninvolved tumoral solid lesions may become cystic and may appear as new lesions in the later months of treatment. In this study, we presented the response evaluation process in our patient with metastatic GIST who received imatinib therapy.

References

1. Corless CL, Fletcher JA, Heinrich MC (2004) Biology of gastrointestinal stromal tumors. *J Clin Oncol* 22: 3813-3825.
2. Plesec TP (2011) Gastrointestinal mesenchymal neoplasms other than gastrointestinal stromal tumors: focusing on their molecular aspects. *Patholog Res Int* 2011: 1-10.
3. Miettinen M, Lasota J (2013) Gastrointestinal stromal tumors. *Gastroenterol Clin North Am* 42: 399-415.
4. Rajendra R, Pollack SM, Jones RL (2013) Management of gastrointestinal stromal tumors. *Future Oncol* 9: 193-206.
5. Bechtold RE, Chen MY, Stanton CA, Savage PD, Levine EA (2003) Cystic changes in hepatic and peritoneal metastases from gastrointestinal stromal tumors treated with Gleevec. *Abdom Imaging* 28: 808-814.
6. Linton KM, Taylor MB, Radford JA (2006) Response evaluation in gastrointestinal stromal tumors treated with imatinib: misdiagnosis of disease progression on CT due to cystic change in liver metastases. *Br J Radiol* 79: e40-e44.
7. Stroobants S, Goeminne J, Seegers MS, Dimitrijevic P, Dupont, et al. (2003) 18FDG-Positron emission tomography for the early prediction of response in advanced soft tissue sarcoma treated with imatinib mesylate (Glivec). *Eur J Cancer* 39: 2012-2020.
8. Verweij J, Casali PG, Zalcberg J, LeCesne A, Reichardt P, et al. (2004) Progression-free survival in gastrointestinal stromal tumors with high-dose imatinib: randomized trial. *Lancet* 364: 1127-1134.
9. Van den Abbeele AD (2008) The lessons of GIST-PET and PET/CT: a new paradigm for imaging. *Oncologist* 13: 8-13.
10. Antoch G, Kanja J, Bauer S, Kuehl H, Renzing-Koehler K, et al. (2004) Comparison of PET, CT, and dual-modality PET/CT imaging for monitoring of imatinib (STI571) therapy in patients with gastrointestinal stromal tumors. *J Nucl Med* 45: 357-365.
11. Treglia G, Mirk P, Stefanelli A, Rufini V, Giordano A, et al. (2012) 18F-Fluorodeoxyglucose positron emission tomography in evaluating treatment response to imatinib or other drugs in gastrointestinal stromal tumors: a systematic review. *Clin Imaging* 36: 167-175.
12. Choi H, Charnsangavej C, Faria SC, Macapinlac HA, Burgess MA, et al. (2007) Correlation of computed tomography and positron emission tomography in patients with metastatic gastrointestinal stromal tumor treated at a single institution with imatinib mesylate: proposal of new computed tomography response criteria. *J Clin Oncol* 25: 1753-1759.
13. Benjamin RS, Choi H, Macapinlac HA, Burgess MA, Patel SR, et al. (2007) We should desist using RECIST, at least in GIST. *J Clin Oncol* 25: 1760-1764.
14. Demetri GD, Benjamin R, Blanke CD (2004) NCCN task force report: optimal management of patients with gastrointestinal stromal tumors (GIST)- expansion and update of NCCN clinical practice guidelines. *J Natl Compr Cancer Netw* 2: S1-S26