

The Innocence of Youth Can Lead to Life-Threatening Events: A Case Report of Testicular Cancer in Adolescents

Sur Genel^{1,2*}, Floca Emanuela¹ and Sur Daniel^{1,3}

¹University of Medicine and Pharmacy, IuliuHatieganu, Cluj-Napoca, Romania

²Emergency Clinical Hospital for Children, Cluj-Napoca, Romania

³The Oncology Institute „Prof. Dr. Ion Chiricuță” Cluj-Napoca, Romania

Abstract

Innocence of youth and lack of awareness of danger can sometimes lead to fatal endings. Our case meets these conditions. Patient aged 15 years who is well-developed believe that nothing bad can happen. The increase in size of a testicle is considered by him as a sign of manhood and masculinity. The boy ignored this problem for 6 months. Only after six months of testicular tumor development, due to the occurrence of a troublesome cough and dyspnoea of effort present at a local medical service. Because of the symptoms described it is performed a chest radiograph which detect many well-defined opacities, with precise contours. Doctors suspected a possible Koch bacillus pneumonia and guided the case for investigation to our pediatric service. At the first consultation the patient does not mention of any testicular tumor. He totally ignores the issue, although in the last month due to the increase in size of the testicle have started pain and discomfort in walking. It is established the diagnosis of testicular tumor with multiple lung metastases and the case is referred to a specialized department of oncology for staging and initiation of appropriate therapy. Patient was diagnosed with testicular germ cell tumor for which appropriate treatment have been initiated.

Keywords: Testicular cancer; Teenager; Ignorance

Introduction

Testicular cancer is the most common in young or middle-aged men. The incidence of this cancer increased during the last century. Testicular tumors account for 1-2% of all pediatric tumors [1]. The cause of testicular cancer is not known exactly. There are data supporting the involvement of genetic alterations in disease pathogenesis. Thus the risk of developing the disease is higher in those who have first-degree relatives with testicular cancer than the general population [2,3]. Although the etiology is not known there are risk factors associated with testicular cancer. The most important risk factors include cryptorchidism, prior testicular cancer, Klinefelter syndrome, and infertility [4,5].

Testicular tumors can be classified as seminomatous and non-seminomatous germ-cell tumor (NSGCT) types [2].

Patients with localized disease can present with painless scrotal swelling, a sudden collection of fluid in the scrotum, pain or discomfort in a testicle or the scrotum. Patients with disseminated disease can present with lymph node metastasis, gastrointestinal and respiratory symptoms, back and bone pain. Some of the patients with testicular germ cell tumors can present with gynecomastia. Cancer usually affects only one testicle [6].

The diagnosis protocol of testicular cancer includes the following:

- Complete history and physical examination
- Lab tests: serum alpha-fetoprotein, serum beta subunit of human chorionic gonadotropin (beta-hCG), lactate dehydrogenase (LDH)
- Testicular ultrasound
- High-resolution computed tomography (CT) scan of the abdomen and pelvis
- Chest x-ray [2,6]

Staging for testicular cancer is established by correlating the results of imaging studies. It follows the TNM (tumor, node, metastasis)

system. The AJCC stage groupings use both TNM staging and serum tumor marker levels (LDH, HCG, AFP).

Nowadays testicular cancers are curable even in the presence of metastatic disease. Therapeutic possibilities of testicular cancer include the following: surgery, radiation therapy, chemotherapy, and surveillance. The choice of treatment or combination of therapeutic methods are based on the disease stage and type of tumor (seminoma or nonseminoma) [6,7].

Case Report

We report the case of a boy who at age of 15 years was hospitalized for asthenia, fatigue, mixed dyspnea on medium effort.

He was born full term, following a normal pregnancy; birth weight was 3650 g, and he was exclusively breast fed to 1 month. At the age of three years he was diagnosed with right cryptorchidism; he followed treatment with human chorionic gonadotrophin (Pregnyl) for 3 months. After treatment testicle descended into the scrotum. After completing treatment the patient was not monitored in a medical service.

In the last 2 weeks before hospitalization the patient had progressive dyspnea and marked weakness after gym class. In evolution he presented dyspnea at low efforts. Patient presents to territorial service of pediatrics. Here it was found a marked inflammatory syndrome. Chest radiography was performed, and after analyzing this doctors suspected

***Corresponding author:** Sur Genel, University of Medicine and Pharmacy, IuliuHatieganu, 8 Babeş Street, 400012 Cluj-Napoca, Romania, Tel : +40-264-597-256; Fax : +40-264-597-257; E-mail: surgenel@yahoo.com

Received June 16, 2015; **Accepted** August 10, 2015; **Published** August 13, 2015

Citation: Genel S, Emanuela F, Daniel S (2015) The Innocence of Youth Can Lead to Life-Threatening Events: A Case Report of Testicular Cancer in Adolescents. J Cancer Sci Ther 7: 266-268. doi:10.4172/1948-5956.1000360

Copyright: © 2015 Genel S, et al. This is an open-access article distributed under the terms of the Creative Commons Attribution License, which permits unrestricted use, distribution, and reproduction in any medium, provided the original author and source are credited.

Koch bacillus pneumonia. The case was directed for investigate and diagnosis to our service (Figure 1).

Initial clinical examination revealed: pale skin, ringed facies, multiple pigmented nevi on posterior chest, palpable lymph nodes in the anterior cervical, inguinal, and axillary regions, enlarged inflamed tonsils. Vital parameters were stable. The chest was clear on auscultation. The abdomen was soft on palpation with no obvious organomegaly. External genitals examination revealed the left testis with normal size, contour and consistency; the right testis was enlarged, endured, adherent to deep plans, and tumor exceeded the midline of the scrotum (Figures 2 and 3).

Laboratory results revealed inflammatory syndrome with elevated erythrocyte sedimentation rate (ESR=59 mm/hr), increased C-reactive protein (CRP=18.9 Mg/dL), and elevated levels of fibrinogen (861 Mg/dL) and orosomucoid (273Mg/dL). Chemistry profile included elevated levels of lactate dehydrogenase (LDH=2985U/L). Also it revealed leukocytosis (13600/ μ L) with neutrophilia. We have determined anti-HIV antibodies that were negative.

Chest radiography (Figure 1) revealed the following: multiple macronodular, homogeneous, well defined opacities, disseminated in the both pulmonary areas, and compensatory hypertransparency areas as possible lymph nodes.

Considering the changes highlighted on chest radiography we have questioned the following diagnoses: lung metastases, granulomatous pulmonary disease, sarcoidosis and pulmonary tuberculosis. Among the possible causes of lung metastases we have included testicular tumor and malignant melanoma.

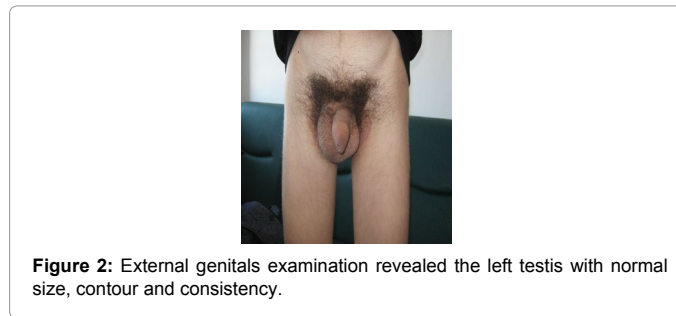
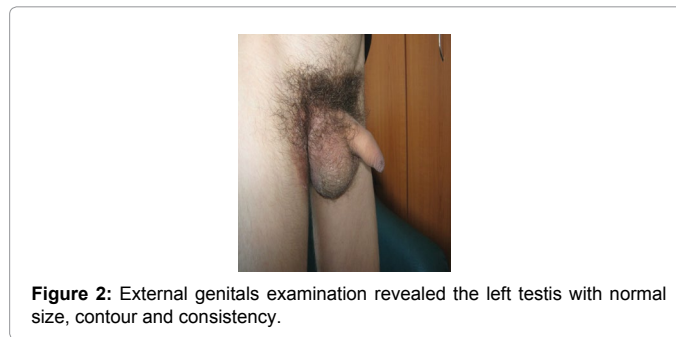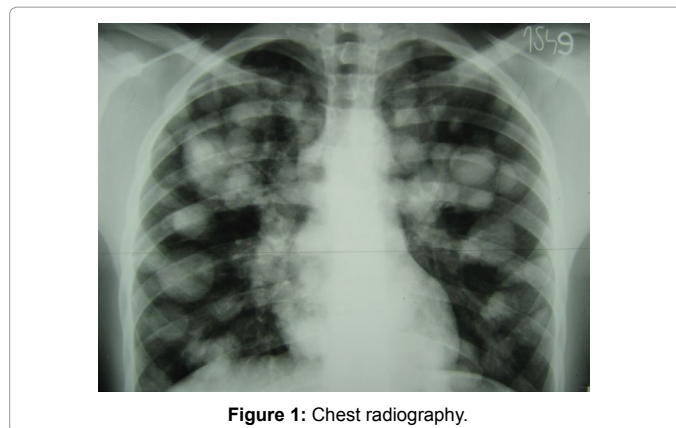
We have continued investigations. Testicular ultrasound revealed a right intratesticular mass with size of 5.2 / 3.7 cm. The tumor had a parenchymal structure and contained hypoechoic areas alternating with hyperechoic areas. There were also detected inguinal adenopathies with moderate size.

Computed tomography (CT) scanning of the chest revealed multiple nodules disseminated in bilateral lung parenchyma with sizes up to 5 cm diameter. There were also detected mediastinal adenopathies and adenopathies in the bilateral hili with sizes up to 4 cm. CT images suggest the presence of multiple lung metastases and mediastinal lymph nodes. No changes were detected in the heart (Table 1).

Abdominal CT scan revealed the presence of lymph nodes with size of 5.5/4 cm in the hilus of the liver. The others abdominal organs showed no pathological changes.

By correlating clinical data and results of investigations we diagnosed the patient with testicular cancer with lung metastases and lymph nodes metastasis (mediastinal and abdominal). Patient was transferred to the Oncology Institute of Cluj Napoca, Department of onco-pediatrics. Here patient was evaluated by a committee that included oncologist, urologist and specialist in anesthesia and intensive care. Laboratory investigations were continued by determining lactate dehydrogenase (LDH) and serum tumor markers including alpha fetoprotein (AFP), and the beta subunit of human chorionic gonadotropin. All these markers were elevated (LDH=3124 U/L >10 times normal, HCG= 4600 mIU/mL, AFP= 3857 ng/mL). Furthermore, it has revealed hyper-uricaemia (6.4 mg / dL).

The final diagnosis is right testicular tumor with lung metastasis and lymph nodes metastasis (abdominal, mediastinal) stage III C (Tx N1 M1 S3).



The increase in tumoral markers is indicative of germ cell tumor.

BEP (Bleomycin, Etoposide, Cisplatin) chemotherapy regimen was initiated. 4 cycles of BEP chemotherapy were administered at intervals of 21 days. Cisplatin was administered in doses of 20 mg / m² / day (31 mg / day) IV for 5 days. Etoposide was administered in doses of 100 mg / m² / day (160 mg / day) IV for 5 days. It was also given anti-inflammatory treatment with dexamethasone. Prevention of tumor lysis syndrome was made by use of allopurinol. Regimen was completed by antitussive (codeine) and prevention of vomiting (Osetron).

Even from the initiation of the first cycle of chemotherapy was observed improvement of respiratory symptoms. After the first treatment cycle were observed changes in lung metastasis by reducing their size. Testicular tumor mass has been reduced in size. Clinical symptoms resolved completely at the end of BEP protocol.

Prostate biopsy was not necessary because there were not detected imagistic pathological changes in the prostate.

CT scan of the abdomen and pelvis and tumor marker were evaluated after the completion of chemotherapy. Tumor markers were normalized at the end of treatment and CT scan has not revealed lung

Stage	Seminoma	Nonseminoma
Stage IA, IB	radical inguinal orchiectomy - after orchiectomy: active surveillance or adjuvant chemotherapy or adjuvant radiation therapy	radical inguinal orchiectomy - after orchiectomy: active surveillance or chemotherapy
Stage IIA, IIB	radical inguinal orchiectomy and adjuvant chemotherapy or adjuvant radiation therapy	open nerve-sparing RPLND or chemotherapy
Stage IIC, III	chemotherapy - after primary treatment with chemotherapy: active surveillance	chemotherapy - after primary treatment with chemotherapy: active surveillance, open nerve-sparing RPLND, salvage chemotherapy

Table 1: Treatment of testicular cancer.

metastases and no changes in the testis. These investigations showed complete remission of the disease. The patient returned to daily activities, school and age schedules, more confident in future.

Clinical course of patients and biomarkers were followed up for a period of two years during which the clinical, biological and imaging data were not changed. The case is still evaluated periodically. Biological markers and imaging investigations were evaluated at three months in the first year and at six months in the 2nd year.

Particularities of the Case

- tumor growing in the testicle with cryptorchidism diagnosed at age 3 years and treated with human chorionic gonadotrophin (Pregnyl)
- ignoring the increase in volume of the testis and consider it to be a sign of manhood
- presentation in a medical service at the onset of respiratory failure secondary to multiple lung metastases

References

1. Christopher S Cooper, Marc Cendron, Bartley G Cilento Jr, Brian L Gallagher (2013) Prepubertal Testicular and Paratesticular Tumors. *Medscape*.
2. Albers P, Albrecht W, Algaba F, Bokemeyer C, Cohn-Cedermark G, et al (2011) EAU Guidelines on Testicular Cancer: 2011 Update. *Eur Urol* 60: 304-319.
3. American Cancer Society (2015) What are the key statistics about testicular cancer? American Cancer Society.
4. Lydia Ferguson, Alexander I Agoulnik (2013) Testicular Cancer and Cryptorchidism. *Front Endocrinol (Lausanne)* 4: 32.
5. Lip SZ, Murchison LE, Cullis PS, Govan L, Carachi R (2013) A meta-analysis of the risk of boys with isolated cryptorchidism developing testicular cancer in later life. *Arch Dis Child* 98: 20-26.
6. Testicular Cancer Treatment (2014) National Cancer Institute.
7. Rebecca Siegel, Carol DeSantis, Katherine Virgo, Kevin Stein, Angela Mariotto, et al. (2012) Cancer treatment and survivorship statistics, 2012. *A Cancer Journal for Clinicians* 62: 220-241.