

The Influence of Antithrombotic Drug Application on Intracranial Hemorrhage

Yinghui Xu*

Department of Neurosurgery, First Affiliated Hospital, Dalian Medical University, Dalian, PR China

*Corresponding author: Yinghui Xu, Department of Neurosurgery, First Affiliated Hospital, Dalian Medical University, 222 Zhong Shan Road, Dalian 116011, PR China, Tel: +8641186110221; E-mail: xuyh_dl@126.com

Rec date: Jan 31, 2017; Acc date: Mar 06, 2017; Pub date: Mar 08, 2017

Copyright: © 2017 Xu Y. This is an open-access article distributed under the terms of the creative commons attribution license, which permits unrestricted use, distribution, and reproduction in any medium, provided the original author and source are credited.

Abstract

Thrombosis is caused by many diseases or complications, such as cerebrovascular disease, coronary heart disease, pulmonary thromboembolism, deep vein thrombosis after surgery and trauma, thus effective antithrombotic therapy has very important significance to the health of human beings. However, more and more clinical reports showed hemorrhage issues induced by antithrombotic treatment, especially in the central nervous system. Accordingly, in this paper, the relationship between common oral anticoagulants applied in clinic and the related problems about intracerebral hemorrhage will be reviewed.

Keywords: Antithrombotic drug; Intracranial hemorrhage; Therapy; Central nervous system; Anticoagulants

Introduction

With the improvement of living standards, the number of middle-aged and elderly who take antithrombotic drugs used for treatment and prevention of cardiovascular disease significantly is increased, many developed and developing countries face the same problems that hemorrhage issues induced by antithrombotic treatment, especially in the central nervous system [1]. Epidemiology is similar, thus our results may be important for compartmental studies aiming at solving these problems all over the world.

Oral Anticoagulants Related Cerebral Hemorrhage

Vitamin K antagonists (VKA) related cerebral hemorrhage

Warfarin is the most commonly used oral anticoagulant drugs for prevention and treatment of thrombosis diseases in clinic, which prevents the formation of thrombin by vitamin K clotting factors (II, VII, IX, X) and protease C and S without influencing on the activation of coagulation factor. It applies to ACS, atrial fibrillation, mechanical heart valve replacement and VTE patients [1].

Previous studies showed VKA increases the risk of intracranial hemorrhage (ICH) 1-6 fold, which induced the overwhelming majority (90%) of VKA related death [2-4]. With the increasing of INR, the risk of ICH will be increased even if INR is in the recommended range when VKA related ICH occurs in clinic mostly. Emergently reversing the anticoagulant effect of VKA may improve the prognosis of ICH, reduce fatality rate and limit expansion of bleeding in patients. It seems to be reasonable that reversed therapy can be applied in patients with expanding hematoma after onset of 72 h because the bleeding volume is recognized as a determinant of patients with bad prognosis [5,6].

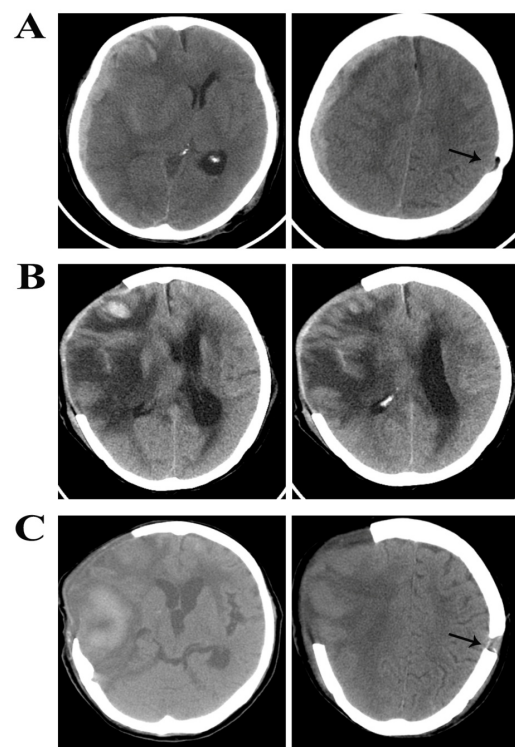
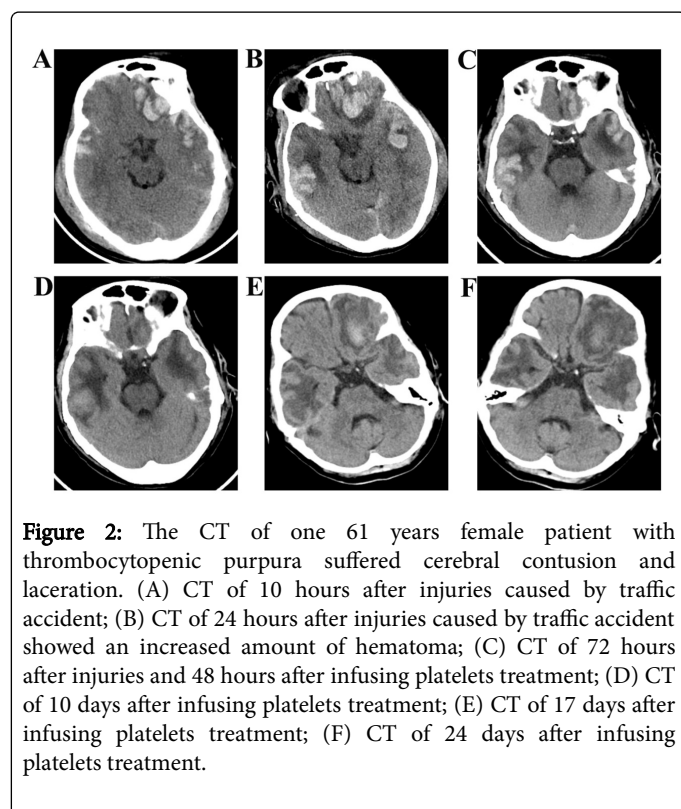


Figure 1: The CT of one 81 years old women patient with atrial fibrillation taking warfarin for 30 years after falling down. (A) CT of 3 hours after falling down; (B) Postoperative CT of 3 days; (C) Postoperative CT change of two week; (→) Postoperative CT change of chronic subdural hematoma 4 years ago.

A variety of effective treatments can be used to reverse the effect of VKA, including vitamin K, fresh frozen plasma (FFP), concentrated clotting factors, and the activity of blood coagulation factor. However,

onset time of these treatments, persistence of reverse and side effects are very different, which needs to consider synthetically. And it makes physician feel concerned when they prescribe oral anticoagulants for atrial fibrillation because traumatic intracranial hemorrhage often happens to old people taking warfarin when they fall down (Figure 1). A recent study released the incidence rate of traumatic intracranial hemorrhage in old people with AF using warfarin is higher than the previous reports about clinical trials [7]. As shown in Figure 2, a female patient with thrombocytopenic purpura suffered cerebral contusion and laceration, who accepted platelet transfusion treatment. Treatment effect is significantly.



Antiplatelet agents related cerebral hemorrhage

Aspirin is the most widely used antiplatelet agents in clinic currently, which inhibits epoxidase to play a role of anticoagulation effects. A large number of studies have shown that aspirin plays an important role in prevention and treatment of cardiovascular disease, and recommend as a first-line drug in many national guidelines [8,9]. In spite of this, according to the study published in Japan, aspirin does not achieve the curative effect of primary prevention of stroke for Japanese old people (whether receive aspirin treatment or not) with stroke risk factors (more than 70 Y, smoking and diabetes) [10].

The absolute risk of ICH induced by antiplatelet drugs is quite low. For example, compared with placebo, the absolute risk of aspirin (ASA) treatment increased only 0.12% every year [11]. The test about risk of ischemic events in patients with clopidogrel and aspirin showed that clopidogrel and ASA treatment have no significant difference (0.33% vs. 0.47%) in the incidence of intracerebral haemorrhage [12]. At present, more and more newer and potent antiplatelet drugs are used to treat patients with acute coronary syndrome with aspirin. ICH risks are basically the same even though the bleeding risk of thiophene

and pyridine drugs-prasugrel is higher than clopidogrel. Compared to clopidogrel, increasing ICH risk of ticagrelor, which is a kind of non-thiophene and pyridine drug combining with platelet P2Y12 receptor reversibly, is not obvious [13]. And another non-thiophene and pyridine-cangrelor also does not show higher ICH risk than clopidogrel. In addition, the dual antiplatelet therapy may have the similar bleeding risk to oral anticoagulants [14,15]. However, the research results show that infusing platelets is not better than the standard treatment in patients with spontaneous intracranial hemorrhage according to the results in clinical practice [16].

Parenteral Anticoagulants Related Cerebral Hemorrhage

Common heparin, low molecular heparin and heparinoid related cerebral hemorrhage

Heparin plays a role of inhibition in every aspect of coagulation *in vitro* and *in vivo* quickly, and becomes the first choice of the antithrombotic because of preventing the formation of acute thrombosis, which can also be used for early treatment of disseminated intravascular coagulation and anticoagulation during hemodialysis extracorporeal circulation, but has no effect on formed thrombosis.

The similar incidence of heparin, low molecular heparin and heparinoid related cerebral hemorrhage depends on the treatment of disease, route of administration, the dosage of anticoagulant, and complications in patients. Compared with aspirin or placebo, therapeutic doses of common heparin, low molecular heparin and heparinoid can increase the ICH risk 1 fold in those patients with ischemic stroke within two weeks [1]. In the international stroke trials, those patients who receive ordinary heparin 5000 U or 12500 U twice a day have ICH rate 0.7% and 1.8% respectively, the control group is 0.3% [17]. Common heparin and low molecular heparin treatment in patients with acute myocardial infarction (AMI) increase ICH risk with no significant difference. According to the low molecular heparin test in patients with acute myocardial infarction, ICH risk of treatment and placebo group are 0.3% and 0.1% respectively. In addition, it is indicated that ICH risk will rise with the increasing of drug dosage, age and degree of kidney damage. And a meta-analysis research found that when the low molecular heparin was used in patients with glomerular filtration rate <60 mL/min although the dose has been adjusted, the relative risk of bleeding is still as high as 1.67 [18].

Thrombolytic agents related cerebral hemorrhage

Thrombolytic drug is a kind of drug which can activate plasmin to promote fibrin degradation and dissolve the formed thrombus. In current, thrombolytic drugs have been developed to the fourth generation, mainly used for cerebral infarction, pulmonary infarction, acute myocardial infarction and deep vein thrombosis.

There is also ICH risk in patients with AMI and AIS when using recombinant tissue plasminogen activators (rtPA). The incidence of ICH are 0.68% and 3% to 9% respectively in the above two kinds of patients, the latter is higher [19,20]. It is reasonable to use thrombolysis reversal agent within the first 24 hours because of its long terminal half-life. Cold precipitation (fibrinogen, blood clotting factor VIII, fibronectin and coagulation factor XIII and von willebrand factor) and fresh frozen plasma are main reversal treatments, although only a few data can support this approach at present. The treatment of platelet transfusion was suggested by American heart association because

thrombolytic drugs could inhibit platelet function temporarily by plasmin and glycoprotein Ib/IIIa pathway [21]. Leukoaraiosis is more common in patients with acute ischemic stroke. Many results show that incidence of intracerebral haemorrhage increases twice in patients with leukoaraiosis receiving thrombolytic therapy. However, the decisions that patients with acute ischemic stroke receive thrombolysis treatment may not be changed. These require further investigation [22].

Discussion

Ischemic cerebrovascular disease is more common in vascular encephalopathy, and cerebral infarction accounted for 59.2% to 85%. Commonly used drugs for the treatment of ischemic encephalopathy are as follows: warfarin, antiplatelet agents (aspirin and clopidogrel), common heparin, low molecular heparin and heparinoid, and thrombolytic agents (rtPA and UK). Previous results showed that incidence of intracerebral haemorrhage increases in patients with ischemic cerebrovascular disease treated by these agents [11]. There were still no unified standard treatments for antithrombotic drugs related intracranial hemorrhage in previous studies. We sum up some experience and methods from previous studies as follows: firstly, stop using the antithrombotic drugs and close monitoring of blood coagulation function; second, give corresponding treatment according to the types of antithrombotic drugs and blood coagulation function in patients and correct blood coagulation function as soon as possible; thirdly, use hemostatic drugs appropriately in all of patients; fourthly, Take a conservative treatment or surgery according to amount of bleeding calculated by MRI or CT, consciousness and cerebral hernia. In the future, understanding and solving these issues clearly need a lot of work, such as looking for predictors, more prospective and retrospective studies and tests of the prevention/treatment strategies.

Conclusion

Coagulation dysfunction is common in the neurological intensive care unit, and it is also a huge challenge to clinicians, while ICH is major neurological complications of patients with coagulation dysfunction. In all patients with intracranial hemorrhage, antithrombotic drugs related intracranial hemorrhage accounts for about 12% to 20%, and compared with other types of cerebral hemorrhage, antithrombotic drugs related intracranial hemorrhage has worse prognosis and higher mortality. In recent ten years, the usage of antithrombotic drugs has been increased significantly, and this trend is likely to continue in the coming decades.

Conflict of Interests

The authors have no financial or personal conflict of interest to declare.

References

- Schulman S, Beyth RJ, Kearon C, Levine MN (2008) Hemorrhagic complications of anticoagulant and thrombolytic treatment: American College of Chest Physicians evidence-based clinical practice guidelines (8th edn). *Chest* 133: 257S-298S.
- Fang MC, Go AS, Chang Y, Hylek EM, Henault LE, et al. (2007) Death and disability from warfarin-associated intracranial and extracranial hemorrhages. *Am J Med* 120: 700-705.
- Fang MC, Chang Y, Hylek EM, Rosand J, Greenberg SM, et al. (2004) Advanced age, anticoagulation intensity, and risk for intracranial hemorrhage among patients taking warfarin for atrial fibrillation. *Ann Intern Med* 141: 745-752.
- Campos NL (2014) Comparison of the occurrence of thromboembolic and bleeding complications in patients with mechanical heart valve prosthesis with one and two leaflets in the mitral position. *Rev Bras Cir Cardiovasc* 29: 59-68.
- Cucchiara B, Messe S, Sansing L, Kasner S, Lyden P (2008) Hematoma growth in oral anticoagulant related intracerebral hemorrhage. *Stroke* 39: 2993-2996.
- Kuramatsu JB, Gerner ST, Schellinger PD, Glahn J, Endres M, et al. (2015) Anticoagulant reversal, blood pressure levels, and anticoagulant resumption in patients with anticoagulation-related intracerebral hemorrhage. *Jama* 313: 824-836.
- Dodson JA, Petrone A, Gagnon DR, Tinetti ME, Krumholz HM, et al. (2016) Incidence and determinants of traumatic intracranial bleeding among older veterans receiving warfarin for atrial fibrillation. *JAMA Cardiol* 1: 65-72.
- Halvorsen S, Andreotti F, ten Berg JM, Cattaneo M, Coccheri S, et al. (2014) Aspirin therapy in primary cardiovascular disease prevention: A position paper of the European Society of Cardiology working group on thrombosis. *J Am Coll Cardiol* 64: 319-327.
- Chubak J, Kamineni A, Buist DSM, Anderson ML, Whitlock EP (2015) Aspirin use for the prevention of colorectal cancer: An updated systematic evidence review for the U.S. preventive services task force. Rockville MD.
- Uchiyama S, Ishizuka N, Shimada K, Teramoto T, Yamazaki T, et al. (2016) Aspirin for stroke prevention in elderly patients with vascular risk factors: Japanese primary prevention project. *Stroke* 47: 1605-1611.
- He J, Whelton PK, Vu B, Klag MJ (1998) Aspirin and risk of hemorrhagic stroke: A meta-analysis of randomized controlled trials. *Jama* 280: 1930-1935.
- CAPRIE Steering Committee (1996) A randomised, blinded, trial of clopidogrel versus aspirin in patients at risk of ischaemic events (CAPRIE). *Lancet* 348: 1329-1339.
- Becker RC, Bassand JP, Budaj A, Wojdyla DM, James SK, et al. (2011) Bleeding complications with the P2Y12 receptor antagonists clopidogrel and ticagrelor in the PLATelet inhibition and patient outcomes (PLATO) trial. *Eur Heart J* 32: 2933-2944.
- Bhatt DL, Lincoff AM, Gibson CM, Stone GW, McNulty S, et al. (2009) Intravenous platelet blockade with cangrelor during PCI. *N Engl J Med* 361: 2330-2341.
- Harrington RA, Stone GW, McNulty S, White HD, Lincoff AM, et al. (2009) Platelet inhibition with cangrelor in patients undergoing PCI. *N Engl J Med* 361: 2318-2329.
- Baharoglu MI, Cordonnier C, Al-Shahi Salman R, de Gans K, Koopman MM, et al. (2016) Platelet transfusion versus standard care after acute stroke due to spontaneous cerebral haemorrhage associated with antiplatelet therapy (PATCH): A randomised, open-label, phase 3 trial. *Lancet* 387: 2605-2613.
- (1997) The international stroke trial (IST): A randomised trial of aspirin, subcutaneous heparin, both, or neither among 19435 patients with acute ischaemic stroke. International stroke trial collaborative group. *Lancet* 349: 1569-1581.
- Hoffmann P, Keller F (2012) Increased major bleeding risk in patients with kidney dysfunction receiving enoxaparin: A meta-analysis. *Eur J Clin Pharmacol* 68: 757-765.
- Broderick J, Connolly S, Feldmann E, Hanley D, Kase C, et al. (2007) Guidelines for the management of spontaneous intracerebral hemorrhage in adults: 2007 update: A guideline from the American Heart Association/American Stroke Association Stroke Council, high blood pressure research council, and the quality of care and outcomes in research interdisciplinary working group. *Circulation* 116: e391-413.
- Carlson SE, Aldrich MS, Greenberg HS, Topol EJ (1988) Intracerebral hemorrhage complicating intravenous tissue plasminogen activator treatment. *Arch Neurol* 45: 1070-1073.

21. Jauch EC, Saver JL, Adams HP, Bruno A, Connors JJ, et al. (2013) Guidelines for the early management of patients with acute ischemic stroke: A guideline for healthcare professionals from the American Heart Association/American Stroke Association. *Stroke* 44: 870-947.
22. Lin Q, Li Z, Wei R, Lei Q, Liu Y, et al. (2016) Increased risk of post-thrombolysis intracranial hemorrhage in acute ischemic stroke patients with leukoaraiosis: A meta-analysis. *PloS one* 11: e0153486.