

# The Experiences of Buprenorphine (Sovenor®) via Transdermal Patch in Elderly with Poor Renal Function

Chen JY<sup>1,2</sup>, Chen WT<sup>1,2</sup>, and Tseng HC<sup>1,2</sup>

<sup>1</sup>Department of Anesthesiology, Shin-Kong Wu Ho-Su Memorial Hospital, Taipei, Taiwan

<sup>2</sup>School of Medicine, Fu Jen Catholic University, New Taipei City, Taiwan

## Abstract

Transdermal buprenorphine is an opioid analgesic used in the management of moderate-severe pain via transdermal pathway. The case series is to discuss the efficacy and safety of transdermal buprenorphine (Sovenor®) in elderly patients with chronic low back pain under renal function impairment condition.

We presented 4 cases demonstrating successful therapy in management of chronic severe low back pain in elderly, who were with poor renal function. Transdermal buprenorphine benefited significantly in those patients' symptoms, and the elderly tolerated transdermal buprenorphine well under good compliance.

In conclusion, transdermal buprenorphine is effective in treating chronic neuropathic pain, and to be a safe analgesic for the elderly. In light of evidence for efficacy, safety, tolerability, and cost, physicians may consider transdermal buprenorphine as the priority choice as pain management in the elderly.

**Keywords:** Buprenorphine; Chronic pain; Low back pain; Renal function impairment; Opioid analgesic; Sovenor

## Introduction

Transdermal buprenorphine is a semi-synthetic opioid analgesic used in the management of moderate-severe pain, it works by producing typical opioid agonist effects. The transdermal formulation provides continuous delivery of buprenorphine, resulting in relatively consistent plasma drug concentrations through-out the 7-day interval. It has been approved for the treatment of chronic non-malignant pain by the Health Sciences Authority (HSA) when an opioid is necessary for obtaining adequate analgesia [1].

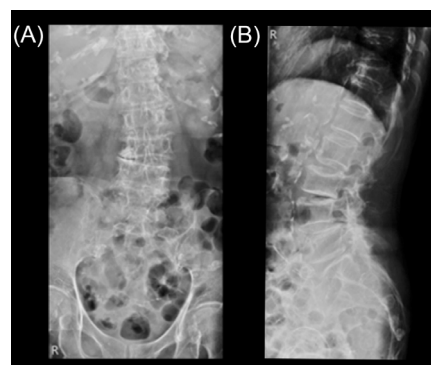
Chronic pain represents a significant challenge to the elderly and physician. The elderly is usually identified as those aged equal or more than 65 years. Many elderly patients suffer cognitive impairment, this can lead to problems of compliance of taking medicine, describing pain or side effect. Also, physiological decline in organ function such as renal, hepatic impairment can affect the pharmacokinetics of analgesic, increase the possibility of drug interactions, and adverse events such as dizziness, headache, and respiratory depression [2]. To choose the best treatment option for the chronic pain in elderly is an important issue. We reported the case series to discuss the efficacy and safety of transdermal buprenorphine in elderly patients with chronic low back pain under renal function impairment condition.

## Case Report

### Case 1

The first patient was a 99-year-old female with history of diabetes mellitus (DM) under poor renal function (creatinine: 2.11 mg/dL, estimated glomerular filtration rate (eGFR): 21.7 ml/min/1.73 m<sup>2</sup>), and the biochemical test also showed higher potassium level (K<sup>+</sup>: 6.6 mmol/L). She visited emergency department and was admitted for compression fracture over T11 and sacrum due to falling down in September 2016 (Figure 1), operation was unable to be performed due to higher risk by the above condition.

Tramacet (tramadol/acetaminophen) 325 mg under oral use three times a day, and morphine 3 mg under intravenous injection (IV) daily were prescribed for pain management in the beginning, but the symptom of delirium was induced. After consulting with nephrologists and pain control team, patient-controlled analgesia (PCA) 3-4 mg under



**Figure 1:** Lumbar X-ray for case 1: (A) posterior-anterior (P-A) view., (B) lateral view.

IV use daily, and caudal steroids injection were applied. In the end of October 2016, physician tried buprenorphine via transdermal patch (5 µg/per hour), the patient's symptoms relived without severe side effect. Since transdermal buprenorphine might be an effective and safe therapy, multiple pain management under transdermal buprenorphine, oral arcoxia (etoricoxib), and seroquel XR (quetiapine fumarate) were prescribed for chronic pain in February 2017, and the patient tolerated the pain management well. Transdermal buprenorphine was discontinued due to stable pain control since May 2017, the patient then received paramol (acetaminophen) 500 mg oral use four times a day till July 2017.

### Case 2

The second patient was an 83-year-old female with history of

**\*Corresponding author:** Hsiang-Chien Tseng, Department of Anesthesiology, Shin Kong Wu Ho-Su Memorial Hospital, Taipei, Taiwan, Tel: 886-2-2833-2211; Fax No: 886-2-2838-9343; E-mail: [ulink@service-top1.com](mailto:ulink@service-top1.com)

**Received** March 15, 2018; **Accepted** March 20, 2018; **Published** March 23, 2018

**Citation:** Chen JY, Chen WT, Tseng HC (2018) The Experiences of Buprenorphine (Sovenor®) via Transdermal Patch in Elderly with Poor Renal Function. J Clin Case Rep 8: 1096. doi: [10.4172/2165-7920.10001096](https://doi.org/10.4172/2165-7920.10001096)

**Copyright:** © 2018 Chen JY, et al. This is an open-access article distributed under the terms of the Creative Commons Attribution License, which permits unrestricted use, distribution, and reproduction in any medium, provided the original author and source are credited.

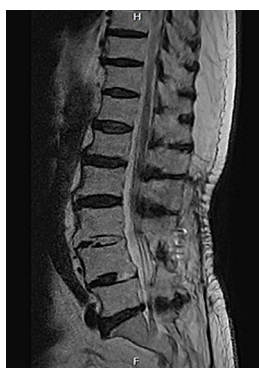DM with neuropathy, coronary artery disease (CAD), and with poor renal function (CKD stage III, Creatinine:1.26 mg/dL, eGFR:40.65 ml/min/1.73 m<sup>2</sup>), she suffered from chronic low back pain due to failed back surgery syndrome (FBSS) (Figure 2), and post-herpetic neuralgia (PHN). Since the patient's older age and underlying diseases might indicate higher risk for spine surgery, both neurosurgeon and orthopedic surgeon suggested conservative treatments for pain management.

She received long-term high dose use of tramadol 200-400 mg daily for low back pain, and lyrica (pregabalin) for PHN since 2010. However, the patient was admitted to neurology ward due to cortical myoclonus with non-convulsive seizure in November 2016, which may be associated with inappropriate use of tramadol. As the result, tramadol was discontinued by physician, and acetaminophen was prescribed instead of tramadol for the safety issue. However, severe pain persisted after the replacement of prescription to acetaminophen, and the patient did not visit clinic for pain management for more than 3 months.

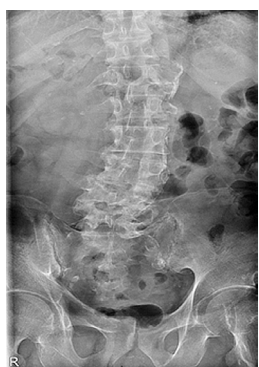She visited clinic again for intolerable severe pain, physician tried transdermal buprenorphine one patch a week for pain management since March 2017. The patient can tolerate transdermal buprenorphine well, with mild side effect under good compliance.

### Case 3

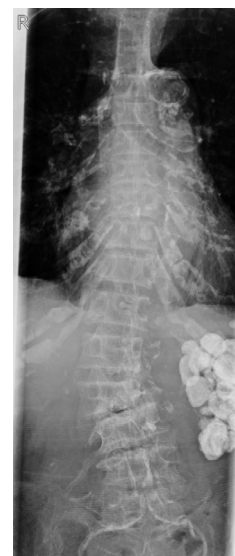The third patient was a 69-year-old male with history of uremia under hemodialysis for two years (end stage renal disease, Creatinine:10.44 mg/dL, eGFR:40.65 ml/min/1.73 m<sup>2</sup>), who complained persistent low back pain for years, and received epidurolysis twice, but the pain still persisted (Figure 3).



**Figure 2:** Lumbar X-ray for case 2: lateral view.



**Figure 3:** Lumbar X-ray for case 3: P-A view.



**Figure 4:** Lumbar X-ray for case 4: P-A view.

The physician tried transdermal buprenorphine for pain management since May 2017. Also, tramacet 325 mg under oral use twice a day was prescribed for three days in the beginning stage of transdermal buprenorphine therapy. The therapy relieved the symptom of persistent pain under good compliance.

### Case 4

The fourth patient was an 86-year-old female with history of uremia under hemodialysis for more than twenty years (end stage renal disease, Creatinine: 4.5 mg/dL). In September 2015, she suffered from osteoporosis with right femoral neck fracture, then received open reduction internal fixation, and complained severe back and hip pain for months (Figure 4).

Tramacet 325 mg under oral use daily was prescribed in the beginning; however, dizziness, nausea, and vomiting were induced. Since June 2017, the physician tried buprenorphine via transdermal patch (5 µg/per hour), stage of buprenorphine therapy. The therapy relieved the symptom of severe pain with mild side effect.

## Discussion

### Our case series

We presented 4 cases demonstrating successful therapy in management of chronic severe low back pain in elderly, whom were with poor renal function impairment. They took kinds of oral pain treatment for neuropathic pain but in vain, also, three of the patients were suffered from severe adverse effects as delirium, non-convulsive seizure, or vomiting. However, transdermal buprenorphine benefited significantly in those patients' symptoms with mild side effect and drug interaction, and the elderly tolerated transdermal buprenorphine well under good compliance.

### Management of chronic and low back pain in elderly

Prior randomized studies showed that transdermal buprenorphine was significantly more effective than placebo in reducing low back pain at moderate-severe degree [3,4] The observational studies also reported transdermal buprenorphine treatment improved the pain scores as compared with controlled non-steroidal anti-inflammatory drugs

(NSAIDs) such as ibuprofen or diclofenac, [5] or other oral tramadol, tilidine/naloxone, the oral opioids provided inadequate analgesia [6].

Studies comparing the efficacy and tolerability of opioids such as transdermal fentanyl, morphine, and sublingual buprenorphine in the elderly, had shown better response as compared with opioid treatment than younger groups. Elderly patients treated with transdermal buprenorphine benefited substantially in reducing pain intensity, and improved pain relief, duration of sleep [7-9].

Several pharmacokinetic factors put the elderly at higher risk when prescribing the opioids. Functional impairment of excretory organs is common in the elderly, especially with respect to renal function or hepatic function. Except buprenorphine, all opioids may increase the half-life of the active drug, metabolites in the elderly, as the result, transdermal buprenorphine appeared to be a safe choice for opioid treatment in the elderly [2].

### Safety, tolerability, and compliance

As other opioids, buprenorphine may cause neurologic adverse events such as nausea, dizziness, or tiredness. However, the overall tolerability of transdermal buprenorphine was acceptable [10]. The respiratory depression with transdermal buprenorphine was rare, the most frequently reported adverse events were headache, dizziness, constipation, nausea, dry mouth etc [1].

Transdermal buprenorphine pharmacokinetics were not altered by advanced age or renal dysfunction, the risk of respiratory depression is lower than with other opioids including morphine, hydromorphone, methadone, and fentanyl. No need for dosage adjustments in the elderly patients with renal dysfunction. Therefore, buprenorphine is recommended as a suitable and safe treatment option in elderly patients and those with severe renal insufficiency [10,11].

### Conclusion

In conclusion, transdermal buprenorphine is effective in treating chronic non-malignant pain with neuropathic pain, and to be a safe analgesic without significant side effect for the elderly, most notably the convenience of once-weekly administration and no need for dosage adjustments in the elderly those with renal function and those on hemodialysis. In light of evidence for efficacy, safety, tolerability,

and cost, physicians may consider transdermal buprenorphine as the priority choice as pain management in the elderly with poor renal function.

### References

1. Plosker GL (2011) Buprenorphine 5, 10 and 20 mug/h transdermal patch: A review of its use in the management of chronic non-malignant pain. *Drugs* 71: 2491-2509.
2. Pergolizzi J, Boger RH, Budd K, Dahan A, Erdine S, et al. (2008) Opioids and the management of chronic severe pain in the elderly: Consensus statement of an international expert panel with focus on the six clinically most often used world health organization step iii opioids (buprenorphine, fentanyl, hydromorphone, methadone, morphine, oxycodone). *Pain practice: the official journal of World Institute of Pain* 8: 287-313.
3. Gordon A, Callaghan D, Spink D, Cloutier C, Dzongowski P, et al. (2010) Buprenorphine transdermal system in adults with chronic low back pain: A randomized, double-blind, placebo-controlled crossover study, followed by an open-label extension phase. *Clinical Therap* 32: 844-860.
4. Gordon A, Rashiq S, Moulin DE, Clark AJ, Beaulieu AD, et al. (2010) Buprenorphine transdermal system for opioid therapy in patients with chronic low back pain. *Pain Res Manag* 15:169-178.
5. Bohme K, Heckes B, Thomitzek K (2011) Application of a seven-day buprenorphine transdermal patch in multimorbid patients on long-term ibuprofen or diclofenac. *MMW Fortschritte der Medizin* 152 Suppl 4:125-132.
6. Schutter U, Ritzdorf I, Heckes B (2010) The transdermal 7-day buprenorphine patch-an effective and safe treatment option, if tramadol or tilidate/naloxone is insufficient. Results of a non interventional study. *MMW Fortschritte der Medizin* 152 Suppl 2:62-69.
7. Likar R, Vadlau EM, Breschan C, Kager I, Korak-Leiter M, et al. (2008) Comparable analgesic efficacy of transdermal buprenorphine in patients over and under 65 years of age. *Clin J Pain* 24: 536-43.
8. Ueberall MA, Müller-Schwefe GH (2013) Long-term treatment of chronic pain with low-dose 7-day buprenorphine transdermal patch. Observational data from elderly patients of pain relief and quality of life. *MMW Fortschr Med* 155 Suppl 3: 87-96.
9. Johnson RE, Fudala PJ, Payne R (2005) Buprenorphine: Considerations for pain management. *J pain Symptom Manage* 29: 297-326.
10. Kress HG (2009) Clinical update on the pharmacology, efficacy and safety of transdermal buprenorphine. *Euro J Pain (London, England)* 13: 219-230.
11. Karlsson J, Söderström A, Augustini BG, Berggren AC (2013) Is buprenorphine transdermal patch equally safe and effective in younger and elderly patients with osteoarthritis-related pain? Results of an age-group controlled study. *Curr Med Res Opin* 30: 575-87.