

The Cervical Trauma in Children: Difficulties in Diagnosis and Treatment Choice

Tiziana Greggi*, Antonio Scarale, Elena Maredi, Francesco Lolli, Konstantinos Martikos, Francesco Vommaro, Mario Di Silvestre, Stefano Giacomini and Andrea Baioni

Spinal Deformity Surgery Department, Rizzoli Orthopaedic Institute, Bologna, Italy

Abstract

Cervical traumas in children are often misunderstood and treated incorrectly. Injuries of the cervical spine are relatively rare in children but are a distinct clinical entity compared with those found in adults. The unique biomechanics of the pediatric cervical spine leads to a different distribution of injuries and distinct radiographic features. The treatment of cervical spine injuries in children must be founded on an understanding of spine development. Differences in injury patterns, interpretation of radiographic studies, and management of injuries are a direct result of the unique anthropometrics and biomechanics of a child. The literature specifically addressing cervical spine injuries in children is scarce most studies have been focused on adults. In more recent years, as distinct aspects of the pediatric spine have been better appreciated, more attention has been given exclusively to injuries of the cervical spine in younger patients. We describe two cases of cervical trauma of different entity for which the incorrect evaluation of the trauma led to a difficult diagnostic-therapeutic path.

Case Report

Case 1

Female 10 years, sudden pain with stiff neck and Cock Robin Sign, after a slight trauma reported during normal activities, she was initially treated with manipulations. Then she was hospitalized after 2 months, due to the persistence of the rotary luxation of C1-C2. In the anamnesis the girl has reported also an initial difficulty walking with lameness already a few weeks before the trauma. She has been studied with RX, NMR and CT (Figure 1a) scan that showed a cervical rotatory luxation type 2 [1], there were very mild aspects of inflammation, type chronic process C1-C2 in NMR (Figure 1b), but the PET showed hyperfixation C1-C2 and acetabulum, the sacroiliac joint and the sternoclavicular. Given the nature of the clinical-radiographic definitely not post-traumatic, we decided for conservative treatment. After the evaluation at the Pediatric Rheumatic center where Chronic Recurrent Multifocal Osteomyelitis (CRMO) was diagnosed, we changed the initial indication with halo-jacket and progressive traction with chin traction and Philadelphia Collar.

Case 2

Male 9 years old, he has had vertebral fractures after fall skiing. He had A1 fractures of T2, T3, T5 and B2 F C2-C3, [1]. He has been treated conservatively with brace and Philadelphia collar. The young boy arrived to our attention two months after the trauma with persistent pain and stiff neck: MRI (Figure 2b) and RX (Figure 2a) show a persistent edema of the soft tissues at C2-C3, signs of posterior instability and spondylolisthesis with kyphosis C2-C3. We have treated him with application of halo-jacket (Figure 2c), well tolerated and RX control at follow up showed the stability and the correct position of the cervical spine.

Results

Case 1: After the correct diagnosis, we have undertaken progressive traction with chin and physiotherapy along with specific medical therapy for the rheumatologic disease with bisphosphonates and immunosuppressants. The clinical response has been good. At last 2-year follow-up MRI (Figure 1c), inflammation appears off in all districts also shows a partial correction of luxation C1-C2.

Case 2: After Halo-jacket correction, worn for 2 months, we have moved to a collar Philadelphia for another month, then soft collar

until the end of treatment. At a 2-year follow-up X-rays show a good correction and cervical stability (Figure 2d) without increasing of pathological kyphosis.

Discussions and Conclusions

Previous investigators have documented that cervical spine injuries are uncommon in the pediatric population. There are substantial differences between children and adults in the clinical presentation after cervical spine trauma. Diagnosis and functional outcome for cervical spine injuries, especially for very young children [2-4] are

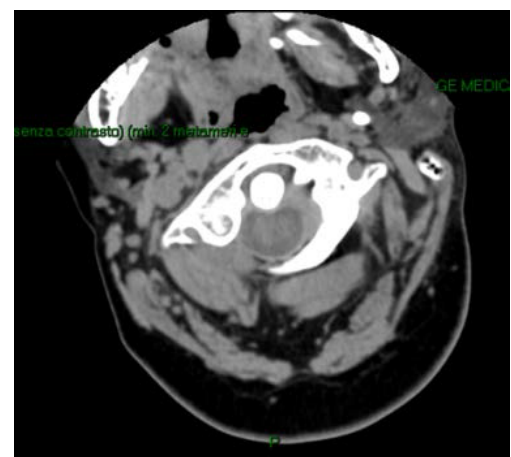


Figure 1a: Case 1- CT scan, axial image of rotatory luxation C1-C2

***Corresponding author:** Tiziana Greggi, Spinal Deformity Surgery Department, Rizzoli Orthopaedic Institute, Bologna, Italy, Tel: 390516366900; E-mail: tiziana.greggi@ior.it

Received January 19, 2015; **Accepted** February 18, 2015; **Published** February 20, 2015

Citation: Greggi T, Scarale A, Maredi E, Lolli F, Martikos K, et al. (2015) The Cervical Trauma in Children: Difficulties in Diagnosis and Treatment Choice. J Spine 4: 214. doi:10.4172/21657939.1000214

Copyright: © 2015 Greggi T, et al. This is an open-access article distributed under the terms of the Creative Commons Attribution License, which permits unrestricted use, distribution, and reproduction in any medium, provided the original author and source are credited.

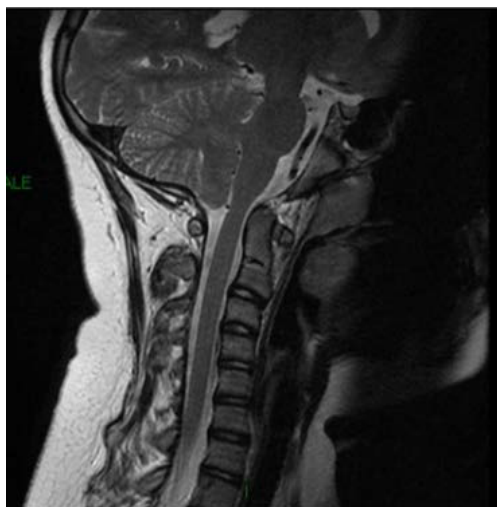

Figure 1b: Case 1- MRI examination, the initial sagittal image.

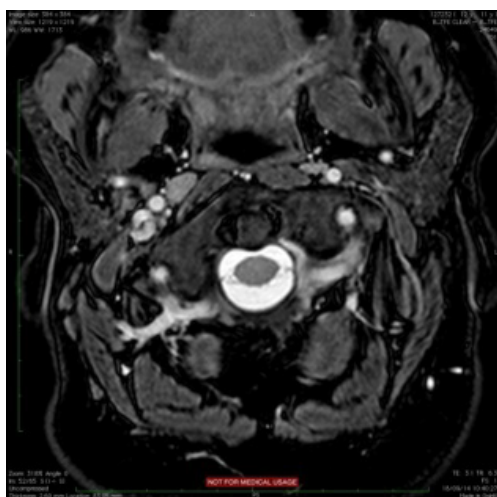

Figure 1c: Case 1, axial MRI image.

difficult to manage. The majority of these injuries are sustained from a motor vehicle crash (27 of 52, 52%) while the remaining are the result of falls (15%), bicycle accidents (11%), sports-related injuries (10%), walking accidents (8%), or motorcycle crashes (4%). Global mortality rate in this kind of injuries is 13%. Although the incidence of spinal cord injury is relatively low (1% to 2%) in the pediatric population cervical trauma arrives to 60%-80%, while in the adults cervical spine injuries constitute 30% to 40% of all vertebral injuries [5]. Whereas these injuries are rare, the most appropriate and cost-effective treatment remains controversial [6]. The presence of a modest trauma with rotary dislocation makes necessary a deep clinical examination and evaluation of comorbidities (case 1). A major trauma can lead to a lesion apparently light or an unrecognized and underestimated instability (case 2). The cervical trauma in childhood is often under or overestimated. The physiological hyperlaxity often causes errors of judgment because the lesion cannot be identified immediately. What these cases have taught us is that in case of minor trauma some other causes (rheumatology, inflammatory) should always be investigated starting from the history, considering the existence of other signs and symptoms of disease. The correct diagnosis is the first step of the treatment and in case of

persistence of pain further diagnostic investigation is mandatory. The conservative treatment in cases of mild trauma should be considered as a valid treatment with satisfactory results.

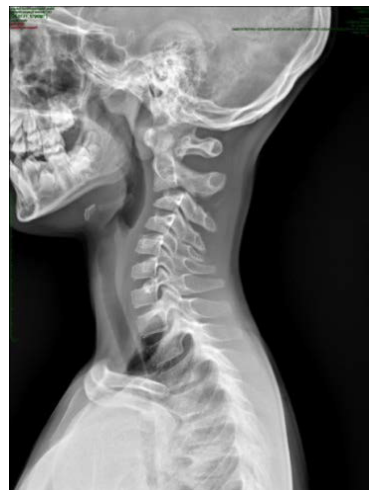

Figure 2a: Case 2, RX image of fracture luxation C2-C3.

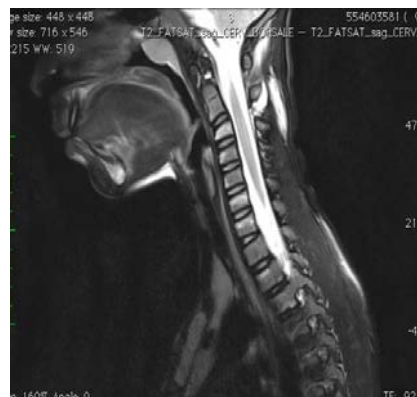

Figure 2b: Case 2, sagittal MRI with evident lesion of interspinous ligament C2-C3.

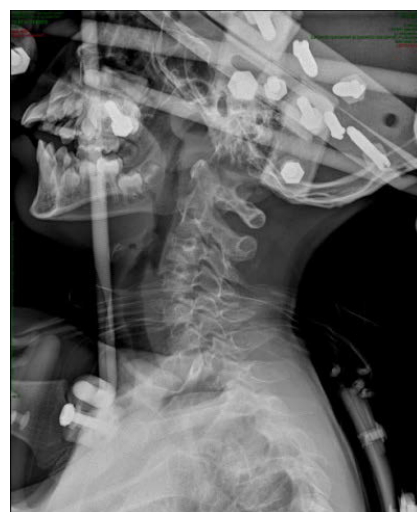

Figure 2c: Case 2, RX cervical spine, lateral view with halo-jacket.

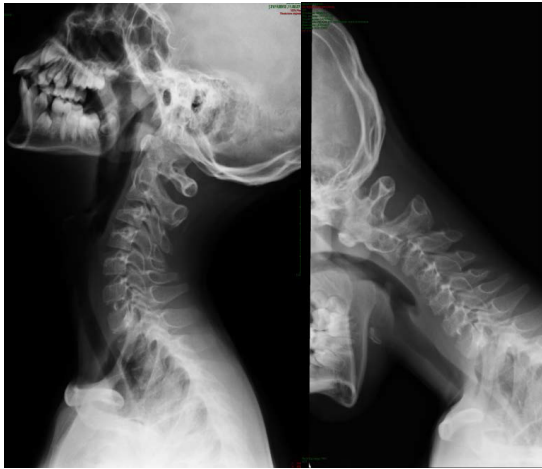

Figure 2d: Case 2, RX dynamical examination in lateral view.

References

1. Vaccaro AR, Hulbert RJ, Patel AA, Fisher C, Dvorak M, et al. (2007) Spine Trauma Study Group. The Subaxial Cervical Spine Injury Classification System A Novel Approach to Recognize the Importance of Morphology, Neurology, and Integrity of the Disco-Ligamentous Complex. *Spine* 32: 2365-2374.
2. Pekmezci M, Theologis AA, Dionisio R, Mackersie R, McClellan RT (2015) Cervical spine clearance protocols in Level I, II, and III trauma centers in California. *Spine J* 15: 398-404.
3. Duan Y, Wang HH, Jin AM, Zhang L, Min SX, et al. (2015) Finite element analysis of posterior cervical fixation. *Orthop Traumatol Surg Res* 101: 23-29.
4. Kokoska ER, Keller MS, Rallo MC, Weber TR (2001) Characteristics of pediatric cervical spine injuries. *J Pediatr Surg* 36: 100-105.
5. Polk-Williams A, Carr BG, Blinman TA, Masiakos PT, Wiebe DJ, et al. (2008) Cervical spine injury in young children: a National Trauma Data Bank review. *J Pediatr Surg* 43: 1718-1721
6. Patrick DA, Bensard DD, Moore EE, Calkins CM, Karrer FM (2000) Cervical spine trauma in the injured child: a tragic injury with potential for salvageable functional outcome. *J Pediatr Surg* 35: 1571-1575.