

The Caution of Non-Operative Management of High Grade Blunt Hepatic Trauma

Liu SY, Shankara GS, Yang SY and Liu ZJ*

Department of General Surgery, Nanjing First Hospital Affiliated to Nanjing Medical University, Nanjing, Jiangsu Province, P.R. China

Abstract

Background: Non-operative management (NOM) has evolved into the treatment of choice for most patients with blunt liver injuries who are hemodynamically stable. However, there are still evidence of patients at higher risk for NOM failure. These patients must be treated more cautiously regarding the NOM approach.

Method: The failure of four high grade blunt hepatic trauma cases treated with NOM was reviewed in recent three years in our hospital.

Results: Four patients with high grade liver trauma (three grade IV, one grade V) were initially hemodynamically stable and treated with NOM. Several hours later, their heart rates increased rapidly, and blood pressure decreased and underwent surgery. One patient died just on opening the abdominal cavity due to massive bleeding while the other three were saved.

Conclusion: Non-operative management should be very cautious for high grade blunt hepatic trauma patients although they are early hemodynamically stable

Keywords: Hepatic trauma; Non-operative management; Risk of failure

Introduction

The liver is the second most commonly injured organ after blunt abdominal trauma [1]. The management of hepatic trauma has changed dramatically during the past three decades, particularly for blunt trauma. At present, non-operative management (NOM) has evolved into the treatment of choice for most patients with blunt liver injuries who are hemodynamically stable and success rates for non-operative management commonly are greater than 95% [2]. The current evidence indicates that the NOM can also be successfully applied to selected patients who are initially hemodynamically unstable but respond to intravenous fluids [3,4]. NOM in patients with stable hemodynamics hepatic trauma seems to be the gold standard [5-7]. Most of the severe injured patients presented with active bleeding and underwent emergency operation, however a minority of cases may manifest with stable vital signs in the early hours following accident, then subsequently have massive haemorrhage. In our hospital, most of the blunt liver injury patients were cured by NOM, but we still have much concern about over enthusiasm for the non-operative approach to liver injuries and report the failures of four high-grade hepatic trauma patients which were initially hemodynamically stable and treated with NOM in our hospital in the recent three years [7].

Case Presentation

Case 1

A 40-year-old male patient was squashed by a machine and sent to a local hospital. Immediate CT scan showed liver laceration and subcapsular hematoma (Figure 1). The patient vital signs were: heart rate (HR) 83/minute, blood pressure (BP) 92/64 mmHg. Routine blood test: red blood cell count (RBC) $4.48 \times 10^{12}/L$ (normal range 4.3-5.8 $10^{12}/L$), hemoglobin (HB) 130.9 g/L (normal range 130-175 g/L), hematocrit (HCT) 38.96% (normal range 40-50%). He received NOM and two hours later the BP suddenly decreased to 80/68 mmHg and HR increased to 118/minute. He underwent urgent surgery and the liver had a grade V injury according to The American Association for the Surgery of Trauma (AAST). There was about 1500 ml of blood clot

in the abdominal cavity, the ruptured liver vessels which were actively bleeding were sutured and ligated, and the wound of the liver were closed by stitches. During the surgery, the total amount of blood loss was 11000 ml and about 7000 ml underwent auto-transfusion by Cell Saver. The liver was packed with four gauzes and removed five days later. He recovered from the injury and was discharged 12 days later.

Case 2

A 32-year-old male patient was clamped by a machine on the right upper abdomen and back. He was sent to a local hospital immediately. His vital signs were normal, and the abdominal CT scan suggested liver trauma and hepatoma with no fluid in the abdomen. The patient was treated with NOM. Three hours later, the patient was transferred to our hospital because they had less experience. In our hospital, the vital signs of the patient were: BP 100/68 mmHg, HR 105/minute. CT scan in our hospital indicated liver trauma with moderate amount of fluid in the abdomen (Figure 2). Routine blood test: RBC 3.73×10^{12} , HB 112 g/L and HCT 37%. Because of the severe injury, we decided to give the patient urgent surgery in spite of hemodynamical stability. Ten minutes later, when he was in the operation room, the BP rapidly decreased to less than 80 mmHg and his heart rate increased to 140/minute. The abdomen was distended and shifting dullness was obvious. There were about 3800 ml blood fluid and clot in the abdomen and the liver was injured with grade IV and the ruptured blood vessels were bleeding. We sutured and ligated the rupture vessels and packed the

*Corresponding author: Liu ZJ, Resident, Department of General Surgery, Nanjing First Hospital Affiliated to Nanjing Medical University, No: 68 Changle Rd, Qinhuai District, Nanjing, Jiangsu Province, P.R. China, 210029, Tel: +8618951670241; E-mail: liuzijundocor@sina.com

Received May 07, 2019; Accepted May 20, 2019; Published May 27, 2019

Citation: Liu SY, Shankara GS, Yang SY, Liu ZJ (2019) The Caution of Non-Operative Management of High Grade Blunt Hepatic Trauma - A Case Report. J Trauma Treat 8: 446.

Copyright: © 2019 Liu SY, et al. This is an open-access article distributed under the terms of the Creative Commons Attribution License, which permits unrestricted use, distribution, and reproduction in any medium, provided the original author and source are credited.

liver with five pads of gauzes. Four days later, the gauzes were removed, and he had recovered.

Case 3

A 51-year-old male was hit by a car and sent to a local hospital. He received CT scan immediately which showed hepatic trauma and hematoma. The vital signs were: BP 118/80 mmHg, HR 102/minute. Routine blood test: RBC 4.03×10^{12} and HB 118 g/L. He received NOM. Four hours later, the patient BP was slightly decreased but still within normal range and heart rate increased to 120/minute. He was transferred to our hospital and directly to the operation room within 30 minutes. In the operation room, the BP was 70/52 mmHg and HR was 142/minute. The patient underwent urgent surgery. On opening the abdominal cavity, the HR of the patient decreased rapidly and then stopped. Although rescue was done, he was still not saved. There was about 5500 ml of blood in the abdominal cavity and the color of the liver was pale with grade IV injury.

Case 4

A 56-year-old male patient was injured by a car accident and sent to our emergency room. CT scan suggested liver laceration and subcapsular hematoma with a few amount fluids in the abdominal cavity. His vital signs were: BP 110/78 mmHg, HR 96/minute and the routine blood test was: RBC 3.92×10^{12} , HB 114 g/L. He received NOM. Six hours later, the patient's BP decreased to 86/60 mmHg and HR increased to 122/minute. His abdomen was distended with shifting dullness and urgent surgery was decided. 5 minutes later, in the operation room, his BP decreased to 72/60 mmHg and HR increased to 145/minute. On entering the abdominal cavity, the heart rate decreased and stopped and fortunately he was saved by our rescue measures. The liver injury was grade IV and there were about 4200 ml blood in the abdominal cavity.

Discussion

The management of liver injury is challenging particularly for severe

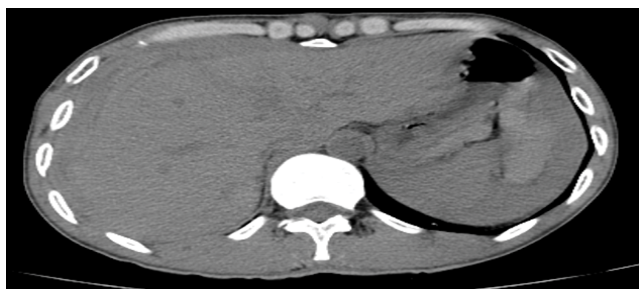


Figure 1: Immediate CT scan showed liver laceration and sub-capsular hematoma.

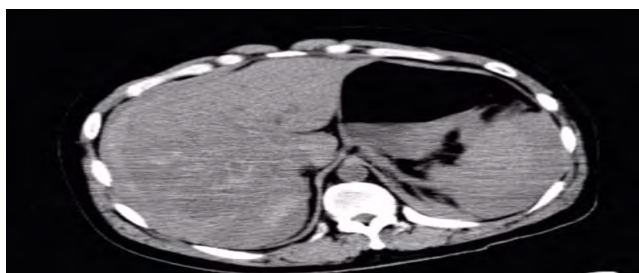


Figure 2: Three hours after injury, CT scan in our hospital indicated liver trauma with moderate amount of fluid in the abdomen.

grades (Grades III-V) [8]. Multiple reports have outlined the efficacy of nonsurgical treatment and its relative safety in hemodynamically stable patients [9,10]. Although most blunt liver injuries may be managed without surgery, some complex liver injuries still require surgery. If surgery is delayed, it can cause massive haemorrhage that threatens the patients' life and even results in death which can lead to the complains and even lawsuit by patients or their relatives.

The success of NOM depends upon proper selection of the patient. Different hospital may have different physiologic criteria or CT criteria, but most of them are hemodynamically stable. Hemodynamic stability is defined as systolic blood pressure above 90 mmHg, heart rate below 110/minute, and normal level of consciousness on arrival or during follow-up [11].

NOM can be chosen for hemodynamically stable patients, but efficiency is not always assured. There are no widely accepted criteria for the choice of NOM and the timing of surgery may sometimes be hard to decide. We therefore suggest the following items as advice to treat liver injury patients.

- First, physicians should be very cautious about the NOM. They should keep in mind all the time that blunt liver trauma is a serious situation which may need surgery. If surgery is delayed it may cause severe outcome even death to the patient.
- Secondly, the etiology of the blunt liver trauma should be taken and its mechanism should be analysed which may aid doctors in choosing the method of treating patients. In our four cases, the traumas were all severe and surgery should be considered.
- Thirdly, we should monitor patients' vital signs carefully. Some authors think that close monitor with repeated clinical assessment which includes the evaluation of vital signs such as BP, HR, temperature, and fluid balance with estimated input and output of fluids in the body and measurement of BP and HCT four times daily for the first 48 hours are mandatory [12].

Conclusion

In our opinion, four times daily is not enough in the early stage because in the first 24 hours, especially the first 6 hours the option of management is critically important. BP and HR should be observed every 15 minutes and the RBC, HB and HCT should be measured every 60 minutes in the first 12 hours. If HR increased to 120/minutes with the fluid resuscitation, surgery should be considered even if BP is normal. If RBC, HB and HCT decrease continuously, surgery should also be considered. Positive shifting dullness and enlarged abdomen circumference suggest active bleeding which are also indications for surgery. The B-ultrasound is helpful and convenient for the diagnosis of liver injury, but sometimes the amount of blood in the abdomen is not in accord with the result of the B ultrasound. Repeated computerized tomography is useful but patients need to be moved which is very inconvenient and sometimes even dangerous.

Finally, although NOM can treat most blunt liver injured patients, there are still a minority of severely injured cases that need surgery. In our four cases, NOM did not work, so the preparation for prompt surgery should always be ready.

Conflicts of Interests

The authors declare that they have no conflicts of interests.

References

1. Abdelrahman H, Ajjaj A, Atique S, El-Menyar A, Al-Thani H (2013) Conservative

- management of major liver necrosis after angioembolization in a patient with blunt trauma. *Case Rep Surg* 13: 1-4.
2. Bala M, Gazalla SA, Faroja M, Bloom AI, Zamir G, et al. (2012) Complications of high grade liver injuries: Management and outcomewith focus on bile leaks. *Scand J Trauma Resusc Emerg Med* 20: 1-20.
 3. Scollay JM, Beard D, Smith R, McKeown D, Garden OJ, et al. (2005) Eleven years of liver trauma: The Scottish experience . *World J Surg* 29: 744-749.
 4. Beuran M, Negoii I, Ispas AT, Păun S, Runcanu A, et al. (2010) Nonoperative management of high degree hepatic trauma in the patient with risk factors for failure: Have we gone too far?. *J Med Life* 3: 289.
 5. Asensio JA, Roldán G, Petrone P, Rojo E, Tillou A, et al. (2003) Operative management and outcomes in 103 AAST-OIS grades IV and V complex hepatic injuries: Trauma surgeons still need to operate but angio-embolization helps. *J Trauma* 54: 647-654.
 6. Dabbs DN, Stein DM, Scalea TM (2009) Major hepatic necrosis: A common complication after angioembolization for treatment of high-grade liver injuries. *J Trauma Acute Care Surg* 66: 621-629.
 7. Di Saverio S, Moore EE, Tugnoli G (2012) Non operative management of liver and spleen traumatic injuries: a giant with clay feet. *World J Emerg Surg* 7: 3.
 8. Zago TM, Pereira BMT, Calderan TRA, Godinho M, Nascimento B, et al. (2012) Nonoperative management for patients with grade IV blunt hepatic trauma. *World J Emerg Surg* 7:8.
 9. Norrman G, Tingstedt B, Ekelund M, Andersson R (2009) Non-operative management of blunt liver trauma: feasible and safe also in centres with a low trauma incidence. *HPB: Oxford, UK.* 11: 50-56.
 10. Sharma OP, Oswanski MF, Singer D (2005) Role of repeat computerized tomography in nonoperative management of solid organ trauma. *Am Surg* 71: 244-249.
 11. Raza M, Abba Y, Devi V, Venkatachalam K, Prasad S, et al. (2013) Non-operative management of blunt hepatic trauma: A ten years review. *World J Emerg Surg* 9: 14.
 12. Ozogul B, Kaisaoglu A, Aydini B (2014) Non-operative management of blunt hepatic trauma: 80 cases. *Ulus Trama Acil Cerr Derg* 20: 97-100.