

The Cause of Idiopathic Pulmonary Fibrosis: A Hypothesis

Ian M Rogers*

46 Whitburn Road, Cleadon, Tyne and Wear SR67QS, Sunderland, UK

*Corresponding author: Ian M Rogers FRCS,FRCP,PGCMEdu, 46 Whitburn Road, Cleadon, Tyne and Wear SR67QS, Sunderland, UK, Tel: 01915367944; E-mail: irogers2000@hotmail.com

Received date: August 26, 2017; Accepted date: September 08, 2017; Published date: September 13, 2017

Copyright: © 2017 Rogers IM. This is an open-access article distributed under the terms of the Creative Commons Attribution License, which permits unrestricted use, distribution, and reproduction in any medium, provided the original author and source are credited.

Abstract

Idiopathic pulmonary fibrosis (IPF) is a rapidly fatal condition of unknown cause. The alveolar membrane becomes thickened with collagen and inflammatory and immune cells, which accumulate in the sub-alveolar tissues. The reduction in the ability of oxygen to diffuse across the membrane leads inevitably to progressive anoxia. There is no satisfactory treatment.

It is proposed that the histological changes observed in the alveolar membrane are due to an immunological reaction to foreign antigens delivered to the alveoli in the form of an aerosol. It is further proposed that repeated exposure to the same foreign antigen leads to an intense immunological reaction. It is argued that expired antigens from the patient's partner may be the source of the antigens.

Further investigations of this hypothesis are likely to involve Polymer chain reaction (PCR) of the expressed breath condensate (EBC) of the relevant partner.

What is the key question?

Is there evidence that repetitive exposure of the alveolar epithelium to the same antigen would be consistent with the pathogenesis?

What is the bottom line?

Expressed breath condensate (EBC) of the partner should be investigated as the suspected antigen for the immunological reaction of the alveolar membrane in IPF.

Why read on?

Idiopathic pulmonary fibrosis quickly kills; it is incurable and progressive and the cause is presently unknown. This hypothesis is consistent with the known pathology and lends itself to further analysis.

Keywords: Idiopathic pulmonary fibrosis; Lung physiology; Allergic alveolitis; Interstitial fibrosis

diseases and reactions to particular drugs such as nitrofurantoin and bleomycin.

Review

Idiopathic pulmonary fibrosis (IPF) condition kills within 3-6 years [1]. There is no known cause and no known effective treatment. The incidence is rising steadily [2,3]. The patient with IPF usually smokes and is usually a male over the age of 50. He becomes progressively breathless due to anoxia from the failure of oxygen to diffuse through the thickened alveolar walls.

The present prevalence in USA varies from 14-42/100,000 with a yearly incidence of 6.8-16.3/100,000 [4]. In Denmark the incidence is rising at the rate of 11%/year [5]. Of all the various varieties of pulmonary fibrosis IPF is the most common [6]. It is unclear how much of this variation among studies is due to geographic or demographic differences in the risk of IPF.

Less common causes of pulmonary fibrosis include hypersensitivity pneumonitis (HP), systemic sclerosis, a variety of dust inhalational

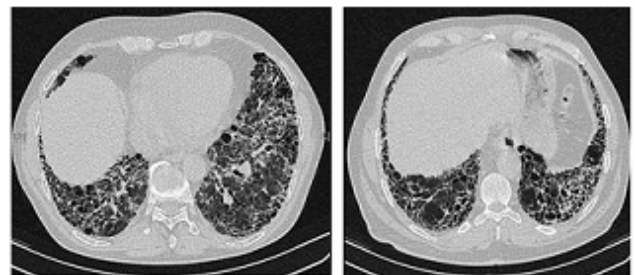


Figure 1: High-resolution computed tomography scans of the chest of a patient with IPF. The main features are of a peripheral, predominantly basal pattern of coarse reticulation with honeycombing.

Diagnosis of IPF (when these other causes do not exist) is best made by high resolution computerised tomography (HRCT scan) or less specifically, chest X-ray since lung biopsies pose significant risks of reducing oxygenation even further (Figure 1 and Figure 2) [5].

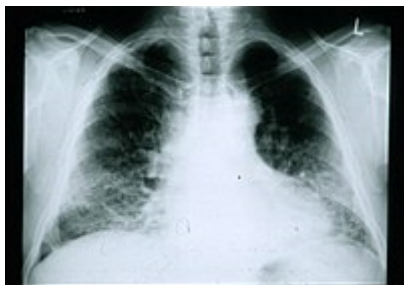

Figure 2: A chest radiograph of a patient with IPF. Note the small lung fields and peripheral pattern of reticulonodular opacification.

When histology is obtained fibroblasts predominate with excess collagen detected in the greatly thickened interstitial spaces between the alveoli (Figure 3) [3].

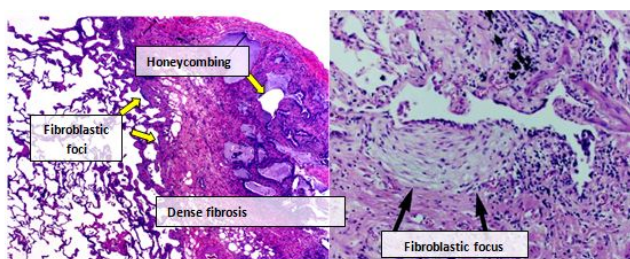


Figure 3: Photomicrograph of the histopathological appearances of usual interstitial pneumonia. High-power magnification (on the right) shows a focus of fibroblastic proliferation, close to an area of fibrosis within which a mild, non-specific, chronic inflammatory cell infiltrate can be observed. In the subpleural space, a typical honeycombing aspect can be recognized.

An excess of free light chains (FLC) of immunoglobulin cells, plasma cells and activated mast cells is found both in IPF and hypersensitivity pneumonitis (HP) compared to normal lung tissue. HP is known to have an allergic or immunological cause and the lung is known to be par excellence, an immunological organ [7]. Lung transplantation in patients who are deemed fit enough may produce good survival rates with a reduction of death by 75% compared to waiting IPF patients. Indeed IPF is the most common reason for lung transplantation in the USA [8].

The Present State

Despite extensive investigation, the cause of IPF remains unknown. The fibrosis in IPF has been linked to cigarette smoking, environmental inhalational factors, and other medical conditions including gastroesophageal reflux disease and in 5% of cases it is due to a genetic predisposition (familial IPF). However, none of these conditions is present in all people with IPF. There is consequently no completely satisfactory explanation for the disease [2,9].

IPF is believed to occur because of an aberrant wound healing process including abnormal and excessive deposition of collagen (fibrosis) in the pulmonary interstitium with minimal inflammation [10].

It is hypothesized that the initial or repetitive injury in IPF occurs to the lung cells, called alveolar epithelial cells (AECs, pneumocytes), which line the majority of the alveolar surface [11]. When type I AECs are damaged or lost, it is thought that type II AECs undergo proliferation to cover the exposed basement membranes. In normal repair, the hyperplastic type II AECs die and the remaining cells spread and undergo a differentiation process to become type I AECs. Under pathologic conditions and when transforming growth factor beta (TGF β) is present, instead fibroblasts accumulate and differentiate into myofibroblasts that secrete collagen and other proteins [11].

The Proposed Cause

The lung is well known to be an immunological organ, which potentially absorbs antigens from the inspired air, provided they are sufficiently small to form an aerosol. The region of absorption is naturally at the thinnest part of the barrier between air and blood---the alveoli [12].

When the invading antigen is in the form of a microbe, the defence mechanisms will include mucous moved upwards by active cilia, surfactant, anti-microbial peptides as well as the more conventional active immunological cells. Dendritic cells or antigen presenting cells (APC) arise close to the alveolar membrane and through the agency of helper T cells and tissue resident memory cells combine to form an adaptive immune system. Such a system when activated will produce a cytokine storm sufficient to repel most invaders but leading to a cellular response at the level of the alveolar membrane. Repeated activation is likely to lead to chronic thickening [13,14].

The repeated entry of a foreign antigen, especially the same foreign antigen, would be likely to progressively induce an intense immunological reaction with the chronic presence of activated cells. Free light chain immunoglobulins (FLC), B cells, plasma cells and activated mast cells have been shown to be present in abnormally high concentration in IPF [7].

In the early 1940s the late Professor Tom Gibson, Professor of Plastic Surgery at Glasgow [13] while working in an MRC unit in Glasgow investigating burned patients, made a seminal discovery. He discovered a phenomenon, which was to later become the basis of the immunology which underpins transplant surgery.

Heavily burned patients were in those days sometimes required to receive split skin grafts from willing relatives or friends. These grafts lasted around 15 days before being rejected. Curiously a second graft from the same donor was rejected instantaneously.

Prof. Gibson possessed a quality of imagination that allowed him to see connections between apparently unrelated facts and discover order and reason in what to individuals less gifted than he appeared only as disorder. This capability was demonstrated in early 1942 when in the Burns Unit of Glasgow Royal Infirmary he was the first person to recognise that the rejection of homografts was an antigen-antibody reaction. Upon learning of Gibson's pioneering insight, Peter Medawar, then at Oxford, came to Glasgow specifically to work with him. Their collaboration led to the classic paper 'The fate of skin homografts in man' [14].

Prof. Gibson's observations have been traditionally known as the second-set phenomenon.

The B cells and T cells physiology-and a Nobel Prize-for Peter Medawar followed in 1960 [15]. In 1960 Medawar wrote to Gibson: . . .

"and I do want you to know how clearly I understand my deep obligation to you for giving me my first insight into the real problem we were facing and my first understanding of the nature of clinical research".

Hence with IPF we simply have to identify the same antigen. An antigen, which enters through the air and naturally is absorbed through the alveoli. On repeated exposure to the same antigen, a progressive immunologically inflammatory response is excited. Progressive involvement of previously undamaged alveoli will occur if the antigen exposure is maintained.

The mucosal damage of the airways associated with smoking may make the respiratory epithelium more receptive to an immunological reaction. The chronic smokers cough is likely to enhance delivery of the antigen as an aerosol. The effect of smoking on reducing the efficiency of the cilia in clearing mucous is likely to allow a more secure deposition at the level of the alveolus.

Most patients with IPF are over 50-most will be married-most will be smokers- most will be sharing the same room with the same partner (traditionally the same woman).

What if the partner-perhaps from smoking too-had a chronic cough?

What if they regularly sat in a relatively small sitting room on a nightly basis? Her bronchial mucosal cells will be from time to time transported as an aerosol to find a resting place in her husband's alveolar membrane and vice versa. It therefore should be no surprise to find that hairdressers-an occupation of close personal exposure with the possibility of repetitive exposure is noted for a higher than normal incidence of IPF-ODDS Ratio 4.4 [16].

The first set phenomenon will rapidly become the second set phenomenon (and the third set) and the immunological derived cascade involving tissue factors and activated cells will have begun.

Exhaled breath condensate (EBC) is a technique, which allows the constituents of the expired or coughed air to be analysed. Metabolic, proteomic and genomic constituents have been identified [17].

The hypothesis here outlined concentrates particularly on the foreign proteins in aerosol form, which would be available for inhalation by our theoretical host.

DNA analysis of the EBC after polymer chain reaction (PCR) will allow an assessment of the cellular expired loss and identify the purity of the sample.

Cats and dogs are not immune from the development of IPF potentially from close regular contact between the same canine and feline partners [18].

Possible further study

Further demographic studies e.g. to find out if bachelors who live alone are less affected may be informative.

An animal model, which features the inhalation of an aerosol rich in the exhaled proteins from another animal, would be of interest.

If IPF develops it would then be possible to test remedial treatments and use HRCT or lung biopsy as a measure of disease progression or improvement.

In-vitro testing of suspected aerosol antigens with the patient's lymphocytes or skin testing *in-vivo* of suspected antigens to demonstrate hypersensitivity would be another avenue to explore.

Acknowledgement

To Dr. Roger Kirby whose untimely death from this condition stimulated this manuscript.

References

1. Ley B, Collard HR, King TE Jr (2011) Clinical Course and Prediction of Survival in Idiopathic Pulmonary Fibrosis. *Am J Respir Crit Care Med* 183: 431-440.
2. Raghu G, Collard HR, Egan JJ, Martinez FJ, Behr J, et al. (2011) An official ATS/ERS/JRS/ALAT statement: Idiopathic pulmonary fibrosis: Evidence-based guidelines for diagnosis and management. *Am J Respir Crit Care Med* 183: 788-824.
3. Ley B, Collard HR (2013) Epidemiology of idiopathic pulmonary fibrosis. *Clin Epidemiol* 5: 483-492.
4. Raghu G, Weycker D, Edesberg J, Bradford WZ, Oster G (2006) Incidence and prevalence of idiopathic pulmonary fibrosis. *Am J Respir Crit Care Med* 174: 810-816.
5. Hyldgaard C, Hilberg O, Muller A, Bendstrup E (2014) A cohort study of interstitial lung diseases in central Denmark. *Respir Med* 108: 793-799.
6. Travis WD, Costabel U, Hansell DM, King TE Jr, Lynch DA, et al. (2013) An official American Thoracic Society/European Respiratory Society statement: Update of the international multidisciplinary classification of the idiopathic interstitial pneumonias. *Am Respir Crit Care Med* 188: 733-748.
7. Kormelink TG, Pardo A, Knipping K, Buendia-Roldan I, Garcia-de-Alba C, et al. (2011) Immunoglobulin Free Light Chains are Increased in Hypersensitivity Pneumonitis and Idiopathic Pulmonary Fibrosis. *PLoS ONE* 6: e25392.
8. Russo MJ, Iribarne A, Hong KN, Davies RR, Xydas S (2010) High lung allocation score is associated with increased morbidity and mortality following transplantation. *Chest* 137: 651-657.
9. Garcia-Sancho C, Buendia-Roldán I, Fernández-Plata MR, Navarro C, Pérez-Padilla R, et al. (2011) Familial pulmonary fibrosis is the strongest risk factor for idiopathic pulmonary fibrosis. *Respir Med* 105: 1902-1990.
10. Harari S, Caminati A (2010) IPF: new insight on pathogenesis and treatment. *Allergy* 65: 537-553.
11. Loomis-King H, Flaherty KR, Moore BB (2013) Pathogenesis, current treatments and future directions for idiopathic pulmonary fibrosis. *Curr Opin Pharmacol* 13: 377-385.
12. (2015) The lungs at the frontlines of immunity. *Nat Immunol* 16: 17.
13. rse.mtcservers6.com/cms/files/fellows/obits_alpha/gibson_thomas.pdf
14. Gibson T, Medawar PB (1943) The fate of skin homografts in man. *J Anat* 77: 299-310.
15. The Nobel Prize in Physiology or Medicine 1960
Sir Frank Macfarlane Burnet, Peter Medawar-Nobel Lecture, 1960.
16. Baumgartner KB, Samet JM, Coultas DB, Stidley CA, Hunt WC, et al. (2000) Occupational and environmental risk factors for idiopathic pulmonary fibrosis: a multicenter case-control study. *Am J Epidemiol* 152: 307-315.
17. Chow S, Thomas PS, Malouf M, Yates DH (2012) Exhaled breath condensate (EBC) biomarkers in pulmonary fibrosis. *J Breath Res* 6: OI6004.
18. Williams K, Malarkey D, Cohn L, Patrick D, Dye J, et al. (2004) Identification of spontaneous feline idiopathic pulmonary fibrosis:

morphology and ultrastructural evidence for a type II pneumocyte defect.
Chest 125: 2278-2288.