

## The Bamberg Plate: An Alternative Procedure for Tibial Tubercle Fractures

Christoph Lutter<sup>1,2\*</sup>, Dominik Popp<sup>2</sup>, Jorg Dickschas<sup>2,3</sup> and Volker Schoffl<sup>2,3</sup>

<sup>1</sup>CV Path Institute, Gaithersburg, USA

<sup>2</sup>Department of Sports Orthopedics, Sports Medicine, Sports Traumatology, Department of Orthopedics and Traumatology, Klinikum Bamberg, Germany

<sup>3</sup>Department of Trauma and Orthopedic Surgery, Friedrich Alexander University, Erlangen-Nuremberg, Germany

\*Corresponding author: Christoph Lutter, CVPath Institute, Gaithersburg, USA, Tel: +13012083570; E-mail: christoph.lutter@googlemail.com

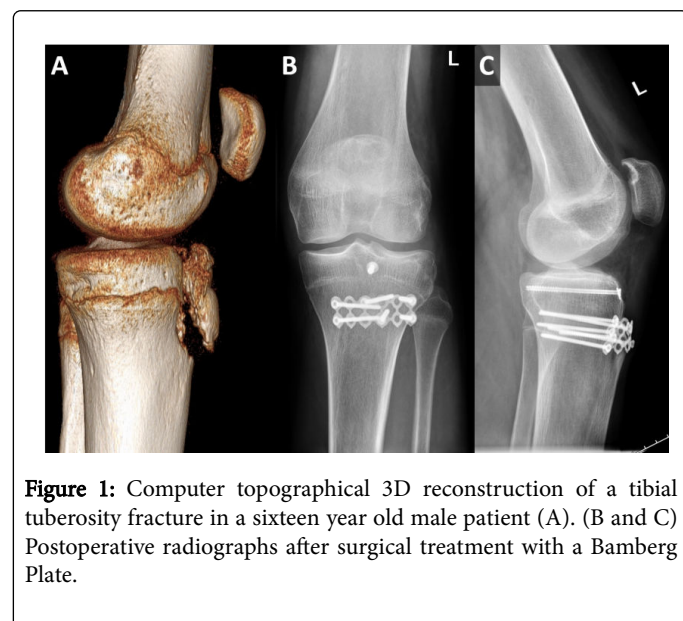
Rec date: Jun 20, 2016; Acc date: Jun 29, 2016; Pub date: Jun 30, 2016

Copyright: © 2016 Lutter C, et al. This is an open-access article distributed under the terms of the Creative Commons Attribution License, which permits unrestricted use, distribution, and reproduction in any medium, provided the original author and source are credited.

### Letter to the Editor

Atypical fractures are challenging for surgeons, as standard procedures are not applicable [1,2]. An interesting alternative for avulsion fractures of the tibial tubercle is the Bamberg Plate, a self-adjusted calcaneus titanium plate [3,4]. This simple and inexpensive implant was originally developed for displaced fractures of the greater humerus-tuberosity, but has already proved its advantage in various other locations, such as the tibial head or the posterior collum of the acetabulum [3,4]. We have now treated four patients aged 16, 19, 36 and 50 with avulsion fractures of the tibial tubercle who all showed an excellent postoperative outcome with no complications, secondary dislocations or loss of strength. The size of the fracture fragments ranged from small bony avulsions to bigger fragments of the tibial tubercle.

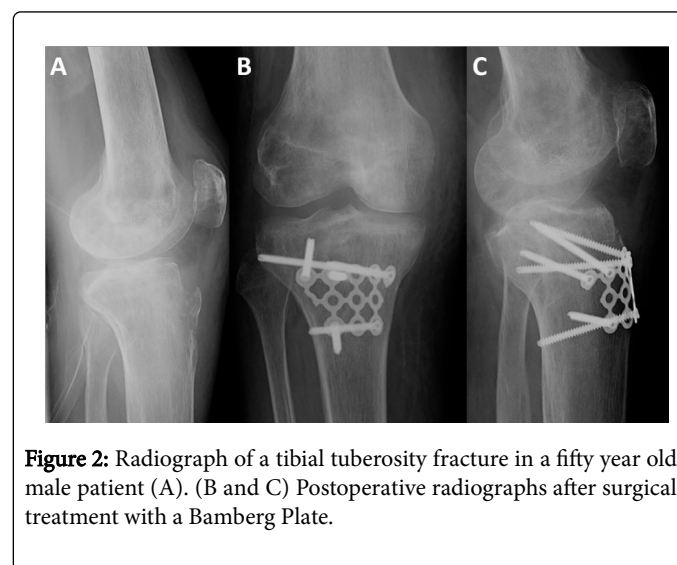
All patients had sustained a fracture of the tibial tuberosity during sports (2x basketball, 1x soccer, 1x rock climbing) when lunging, falling or crashing into an opponent, and were all seen in our emergency room after the trauma. Radiographs revealed the fractures and MRI was performed to ensure integrity of the capsular ligament apparatus (Figures 1 and 2).



**Figure 1:** Computer topographical 3D reconstruction of a tibial tuberosity fracture in a sixteen year old male patient (A). (B and C) Postoperative radiographs after surgical treatment with a Bamberg Plate.

Following a conventional surgical approach and preparation of the fracture, a titanium plate was cut into a small six (or more)-hole plate

and remodeled depending on the intraoperative circumstances and the size of the tibial tuberosity.



**Figure 2:** Radiograph of a tibial tuberosity fracture in a fifty year old male patient (A). (B and C) Postoperative radiographs after surgical treatment with a Bamberg Plate.

After repositioning the fracture, the plate was fixed with 5-8 bicortical and/or locking screws to create a high pressure on the fracture gap (Figures 1 and 2). The postoperative therapy consisted of early immobilization under full relief for two weeks, followed by full load under extension of the knee. A cast with a restricted range of motion (0°/0°/30°, Extension/Flexion) was prescribed for two weeks postoperative and stepwise adjusted during the healing process (weeks 2-4: 0°/0°/60°; weeks 4-6: 0°/0°/90°). Load under flexion was permitted after seven weeks. All patients showed an excellent postoperative outcome with no complications or secondary dislocations; all were able to resume sporty activities quickly.

We therefore highly recommend the Bamberg Plate as an alternative implant for the treatment of tibial tuberosity fractures. The main advantages are:

- It is custom-made and adjustable for almost any fracture lines or anatomical characteristics,
- It is suitable for both angle-stable and conventional screws,
- The extremely thin design allows quick healing of the wound and prevents soft tissue irritations,
- The flexible titanium implant allows postoperative MRI examinations and is suitable for allergic patients [3,4].

Further studies are required to prove the advantages of the implant, but this new approach might be a promising alternative for atypical fractures of the tibial tuberosity.

## References

1. Frangen TM, Dudda M, Martin D, Arens S, Greif S, et al. (2007) Proximal humeral fractures with angle-stable plate osteosynthesis--is everything better now? *Zentralbl Chir* 132: 60-69.
2. Clavert P, Adam P, Bevort A, Bonnomet F, Kempf JF (2010) Pitfalls and complications with locking plate for proximal humerus fracture. *J Shoulder Elbow Surg* 19: 489-494.
3. Schöfl V, Popp D, Strecker W (2009) Bamberger -Platte Ein einfaches und effektives Implantat zur Versorgung dislozierter Tuberculum majus Frakturen. *Trauma und Berufskrankheit* 11: 247-250.
4. Schoffl V, Popp D, Strecker W (2011) A simple and effective implant for displaced fractures of the greater tuberosity: the "Bamberg" plate. *Arch Orthop Trauma Surg* 131: 509-512.